



Case Portfolio

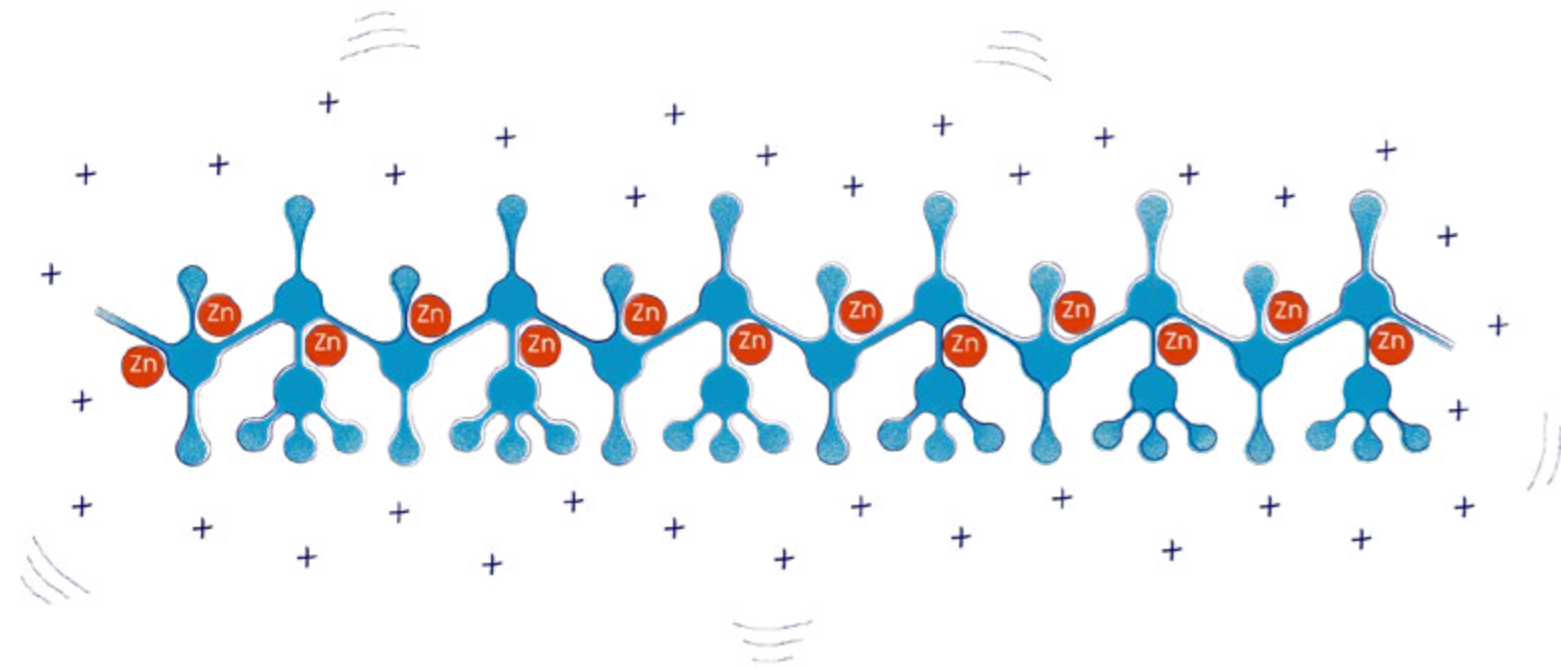
Applications of Elemental®
hydroplastic bacteriostatic granulate.

Cases documented by

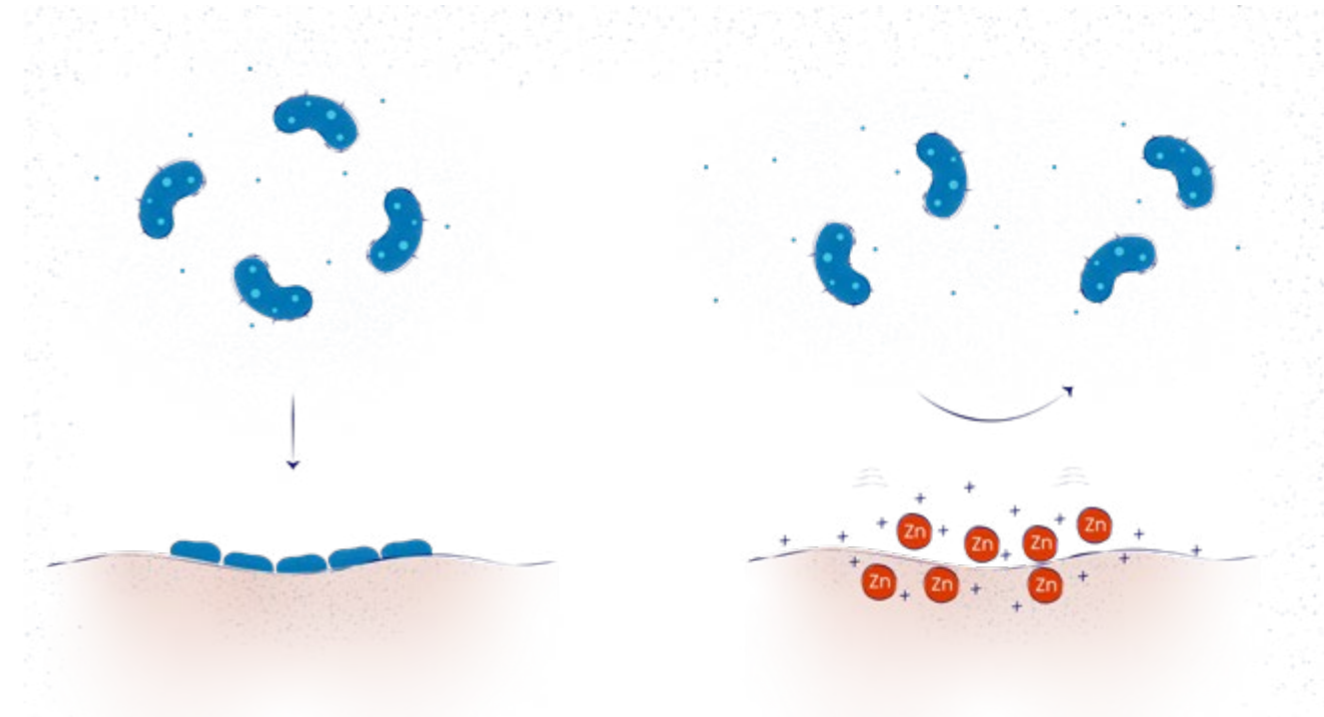
Dr. Kenneth Van Stralen, Dr. Minas Leventis, Dr. Alexander De Greef, Prof. Wim Teughels,
Dr. Mustafa Ozcan, Dr. Cristiano Caleffi, Dr. Bernardo Passoni, Dr. Yasmina Miss,
Dr. Stuart Kilner, Dr. Alexandre Rovisco, Dr. Federico Mandelli, Dr. Ira Reiz, Dr. Marcus Engelschalk,
Dr. Delia Irani, Dr. Violeta Claus, Dr. Fabio Manuel Filannino, Dr. Alina Lazar, Dr. Fabrizia Luongo,
Dr. Andrew Johnson, Dr. Eleonora Solyom, Dr. Cleopatra Nacoupulos, Prof. Roberto Crespi,
Dr. Koromantzos, Dr. Yin Hui, Dr. Peter Brabant, Dr. Mohammed El Farouki, Dr. Sofia Karapataki

LAST UPDATED: NOVEMBER 2022

Background: zinc (Zn^{2+}) has anti-inflammatory, antibacterial and wound healing properties.



Elemental leverages the antibacterial, anti-inflammatory and wound-healing properties of zinc by incorporating Zn^{2+} ions in our dental polymers.



The Elemental technology inhibits bacterial & biofilm growth.

Zinc in Wound Healing Modulation: <https://www.ncbi.nlm.nih.gov/pmc/articles/PMC5793244/?report=classic>

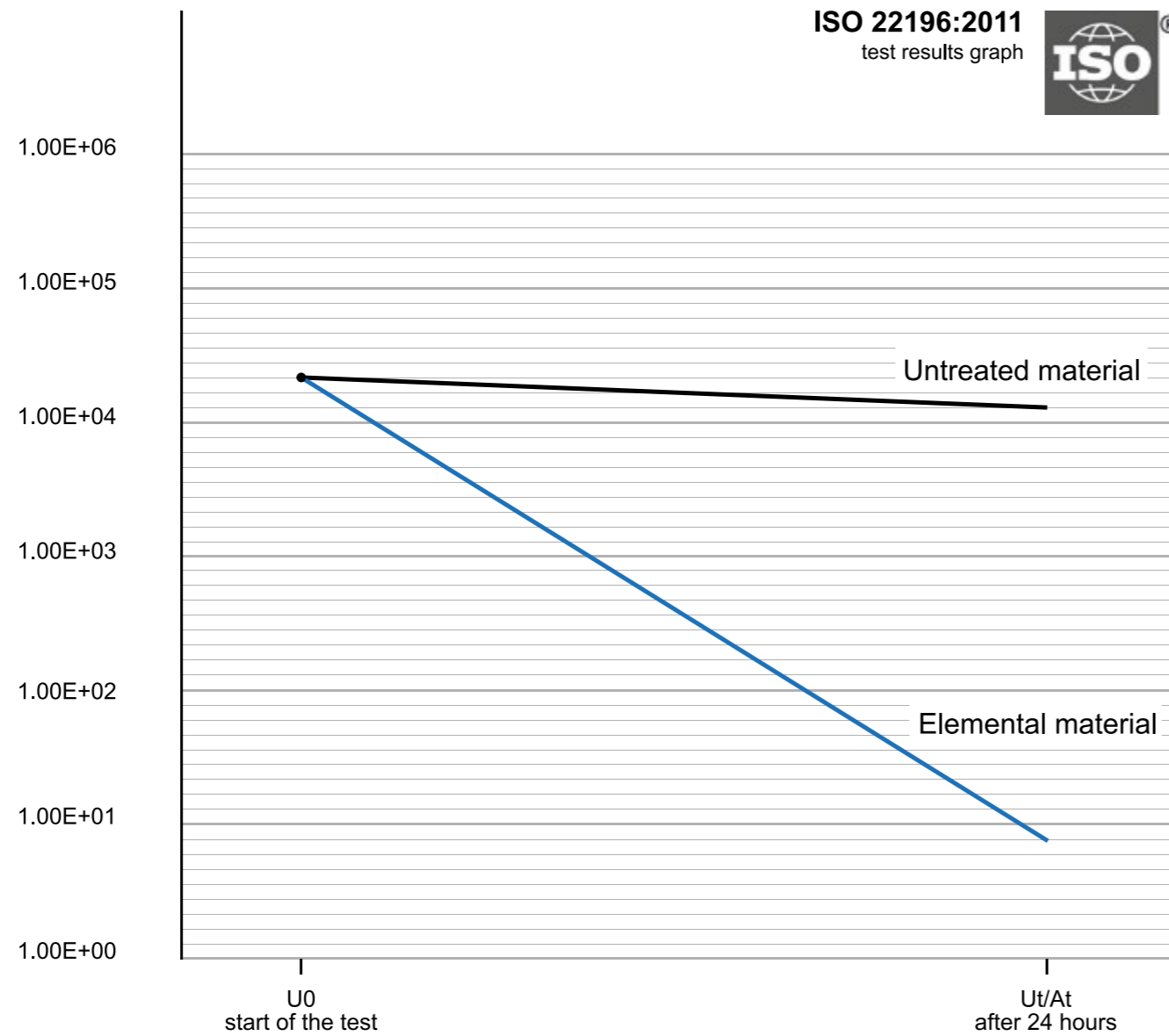
Zinc in wound healing: theoretical, experimental, and clinical aspects: <https://pubmed.ncbi.nlm.nih.gov/17244314/>

A systematic review on antibacterial activity of zinc against Streptococcus mutans: <https://www.ncbi.nlm.nih.gov/pmc/articles/PMC6128804/>

Zinc in Infection & Inflammation: <https://pubmed.ncbi.nlm.nih.gov/28629136/>

Determination of antimicrobial activity.

Determination of Antimicrobial Activity against Gram-Negative Bacteria

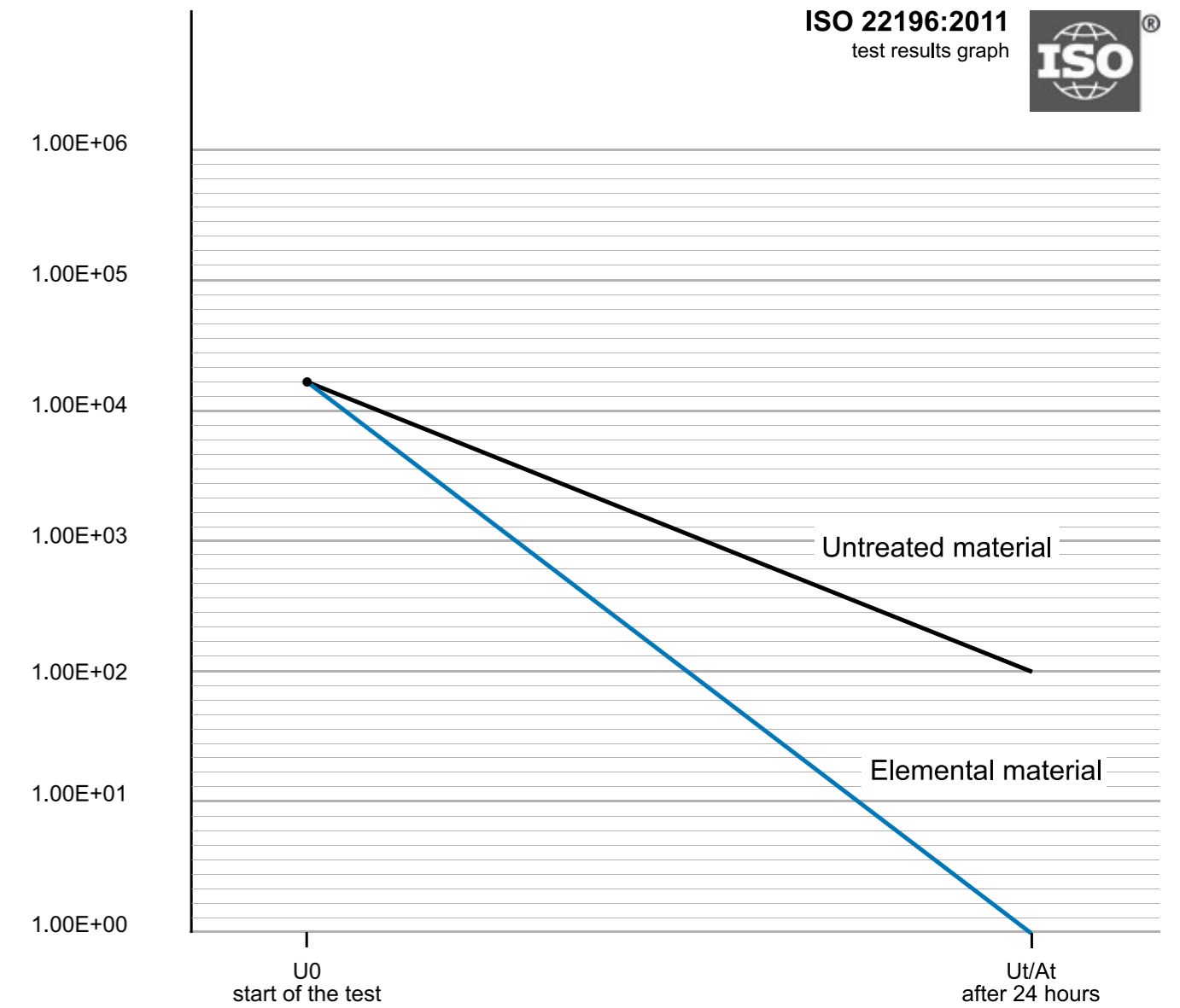


- Gram-negative bacteria development on untreated material
- Gram-negative bacteria development on Elemental material

Determination of Antimicrobial Activity

Determination of antibacterial activity (R) = **3,3 log microbial growth reduction**
 Determination of antibacterial activity (R) = **>99.9%**

Determination of Antimicrobial Activity against Gram-Positive Bacteria



- Gram-positive bacteria development on untreated material
- Gram-positive bacteria development on Elemental material

Determination of Antimicrobial Activity

Determination of antibacterial activity (R) = **>2,0 log microbial growth reduction**
 Determination of antibacterial activity (R) = **>99%**



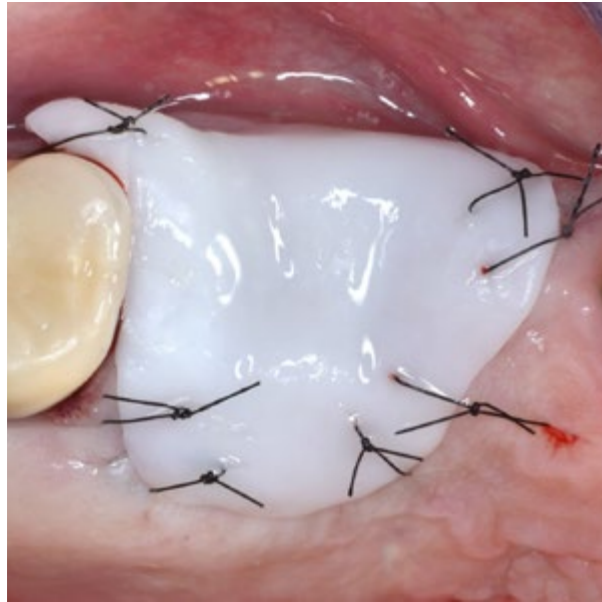APPLICATION

**Socket seal in extraction socket
management, alveolar ridge preservation
techniques.**

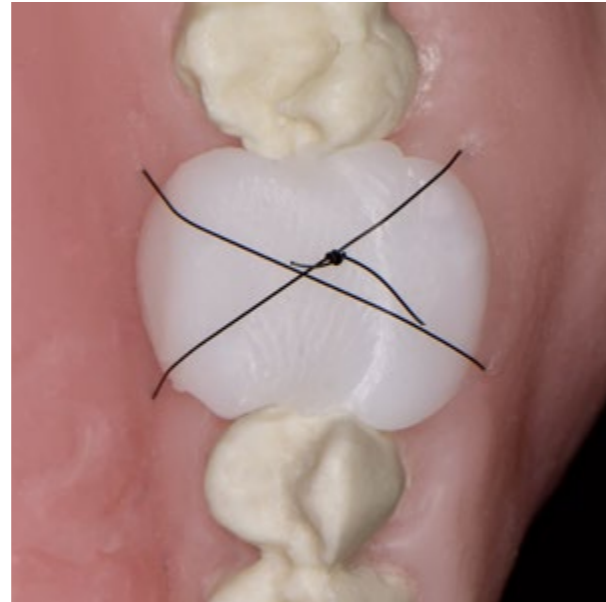


Socket seal

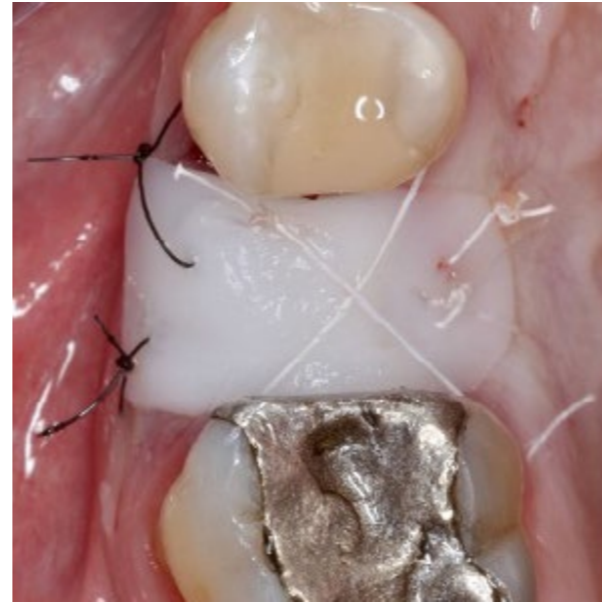Techniques for retention



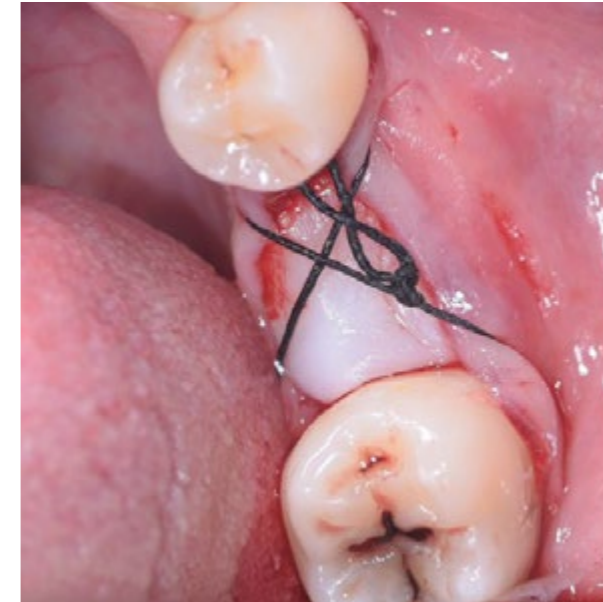Sutured through the polymer after placement of bone substitute.



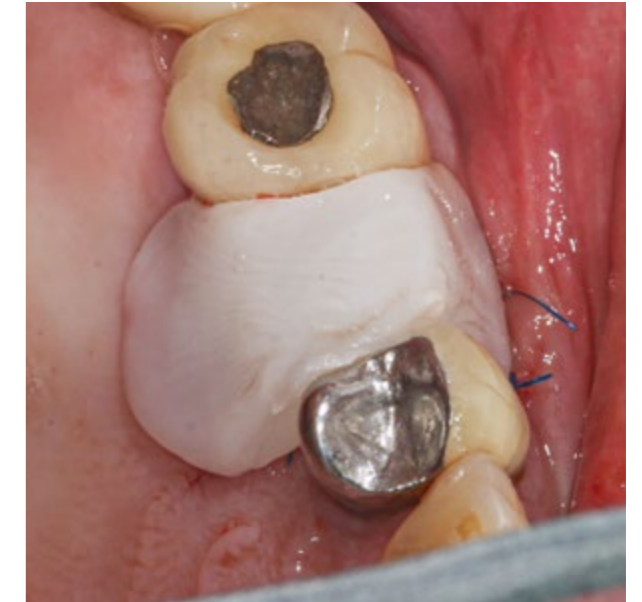Crisscross sutured over the polymer + mechanical retention under the curvature of the adjacent teeth, after placement of bone substitute.



Combination of crisscross, through the polymer and mechanical retention under the curvature of the adjacent teeth, after placement of bone substitute.

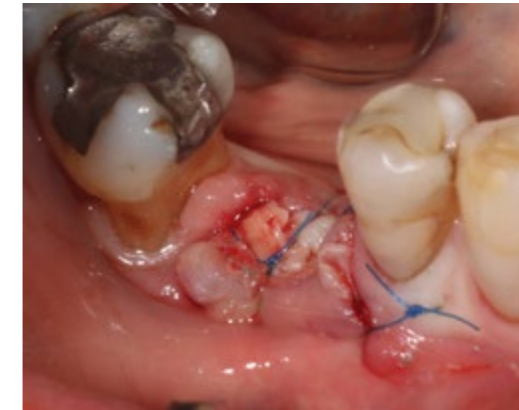

Sutured over the polymer, after placement of PRF.

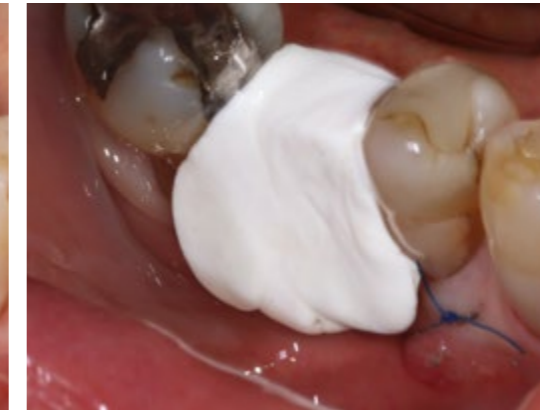

Mechanical retention on the adjacent teeth and tissue after placement of PRF.

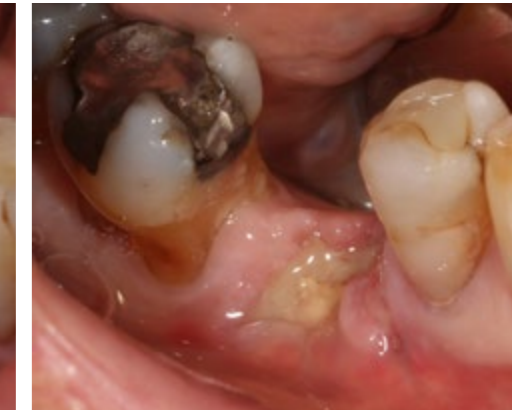Socket seal Healing results



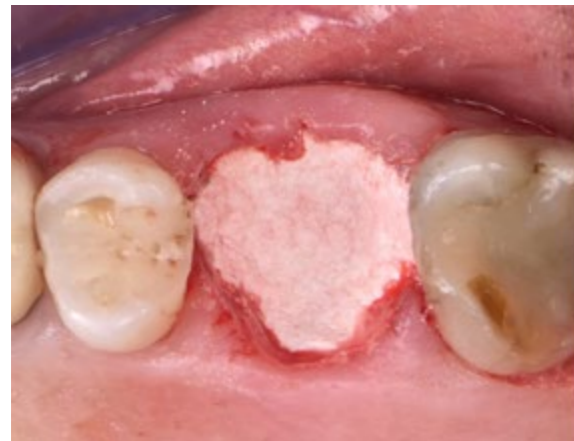Platelet-Rich Fibrin



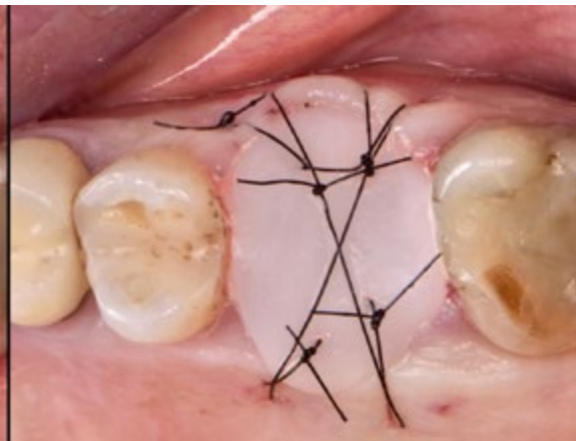Elemental polymer dressing



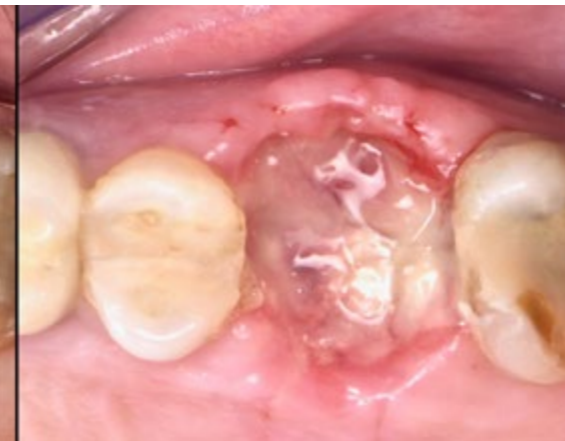7 days post-operative



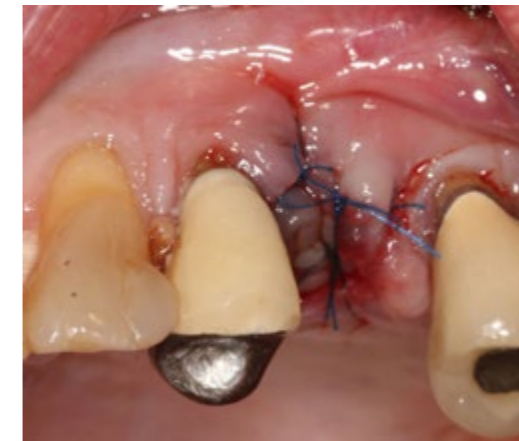Synthetic bone substitute



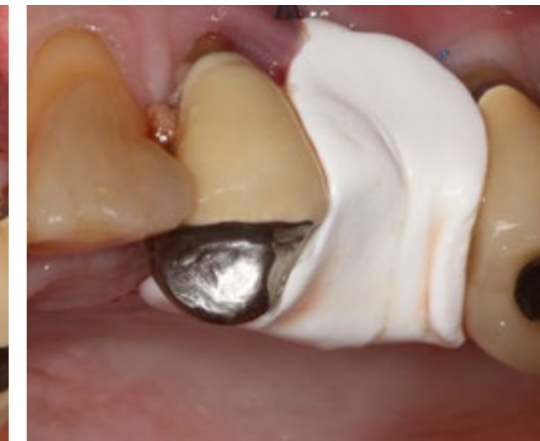Elemental polymer dressing



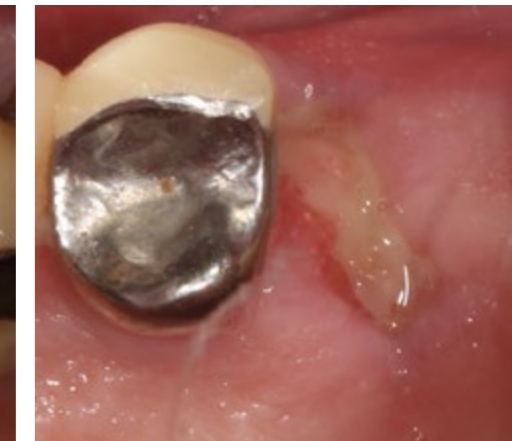8 days post-operative



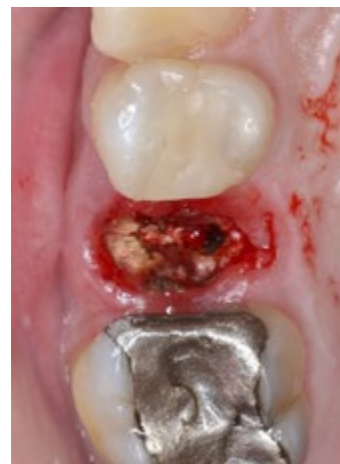Platelet-Rich Fibrin



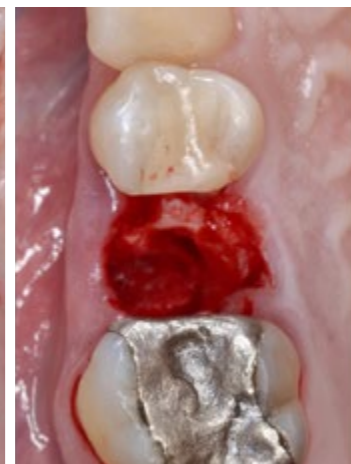Elemental polymer dressing



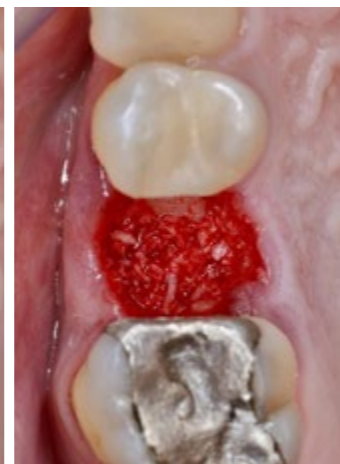10 days post-operative



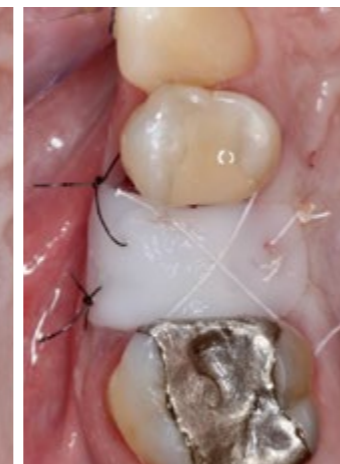Allogenic cancellous bone



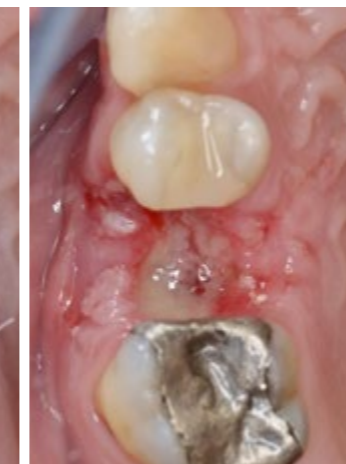Allogenic cancellous bone



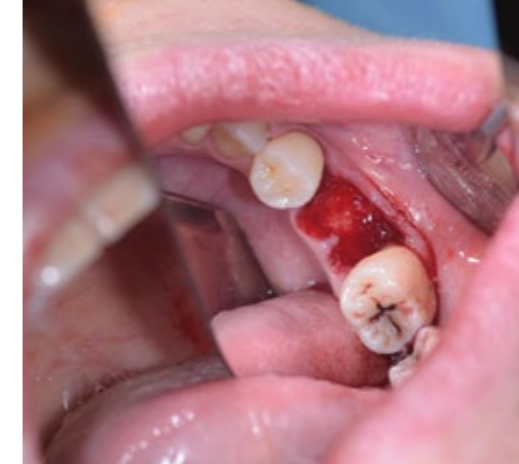Allogenic cancellous bone



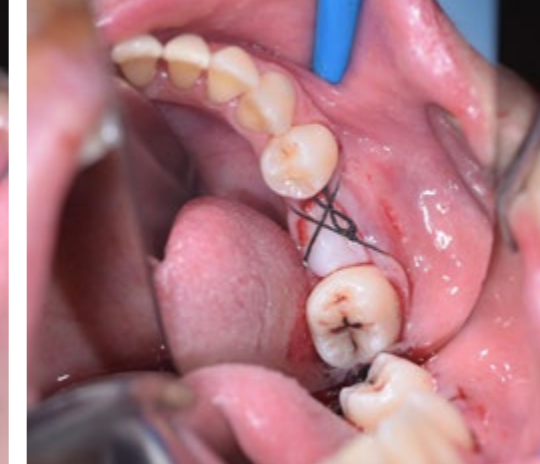Elemental polymer dressing



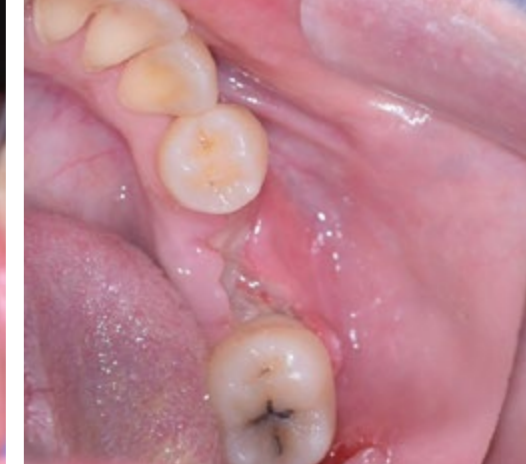3 days post-operative



PRF & Elemental polymer dressing



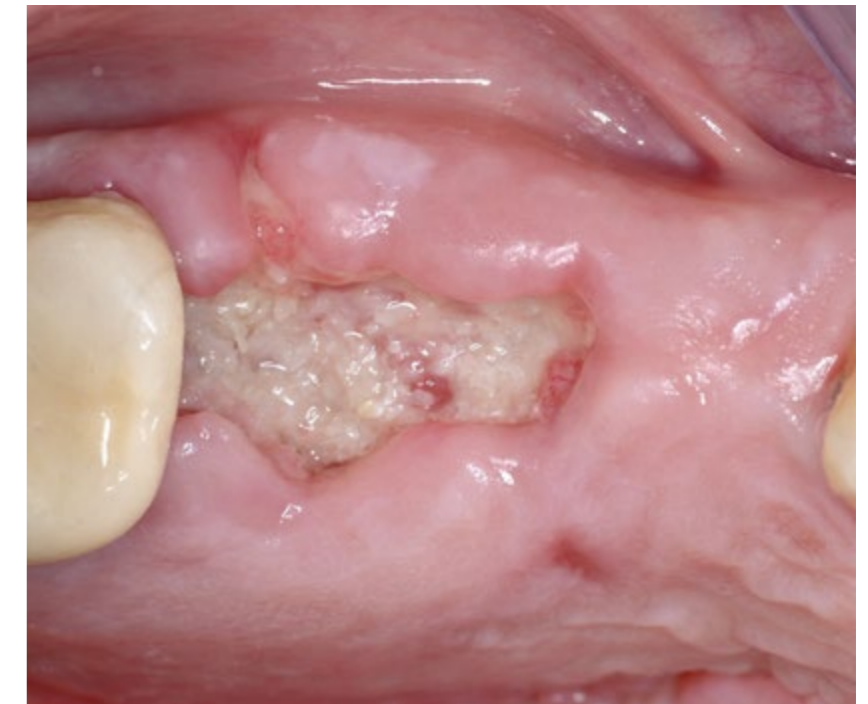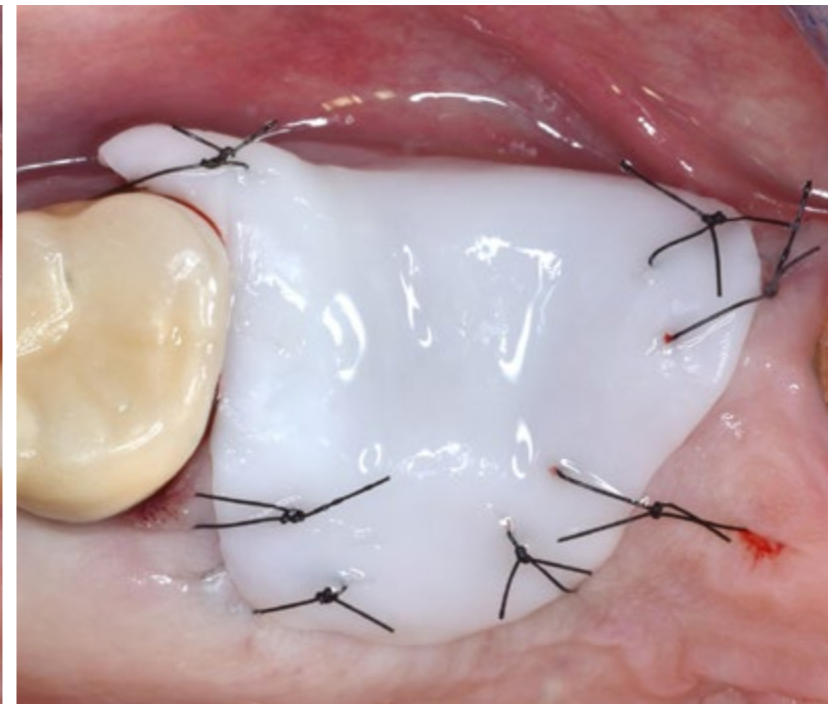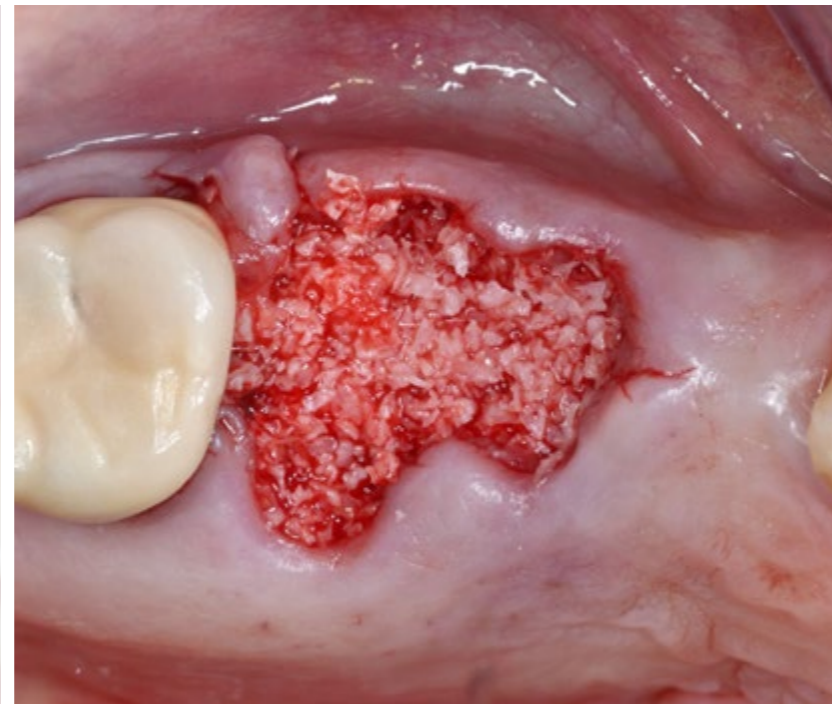
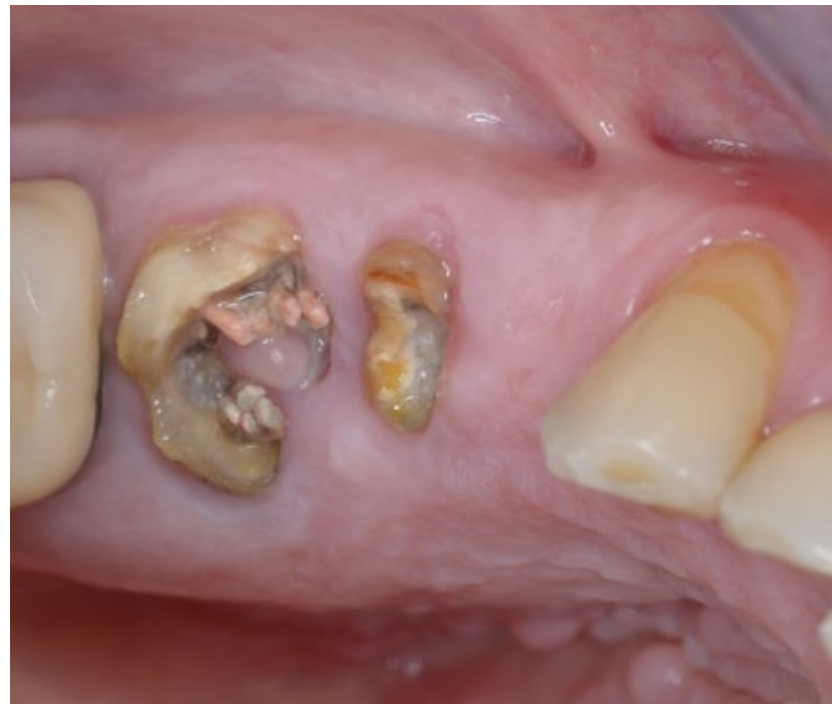PRF & Elemental polymer dressing



7 days post-operative

Application

Elemental barrier for open healing socket grafting



Day of surgery

"No membrane, no sutures over the graft. Just the bone graft, protected by Elemental barrier."

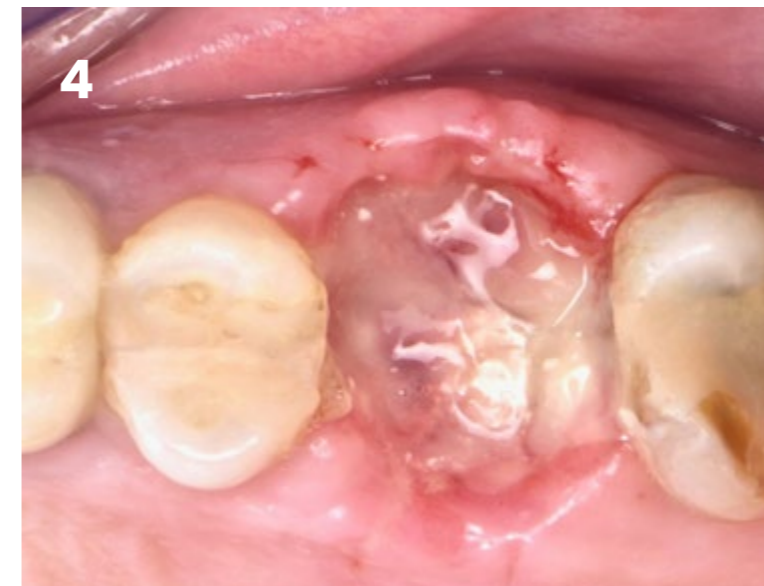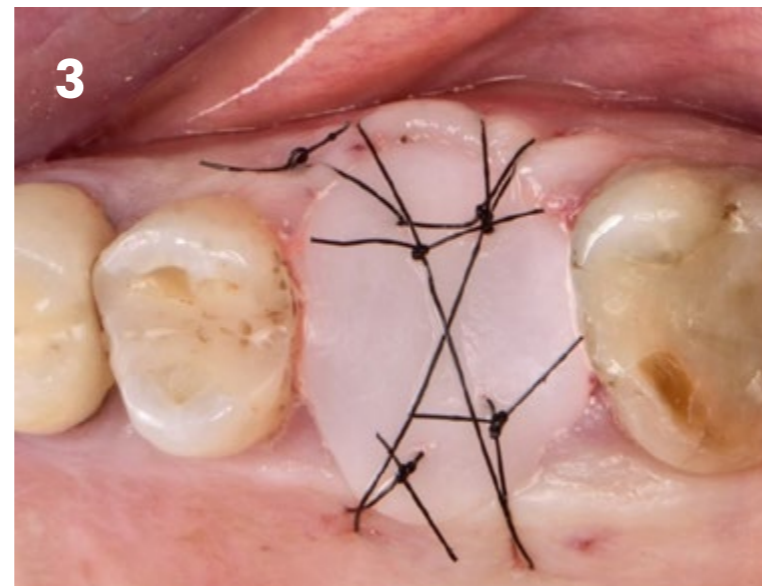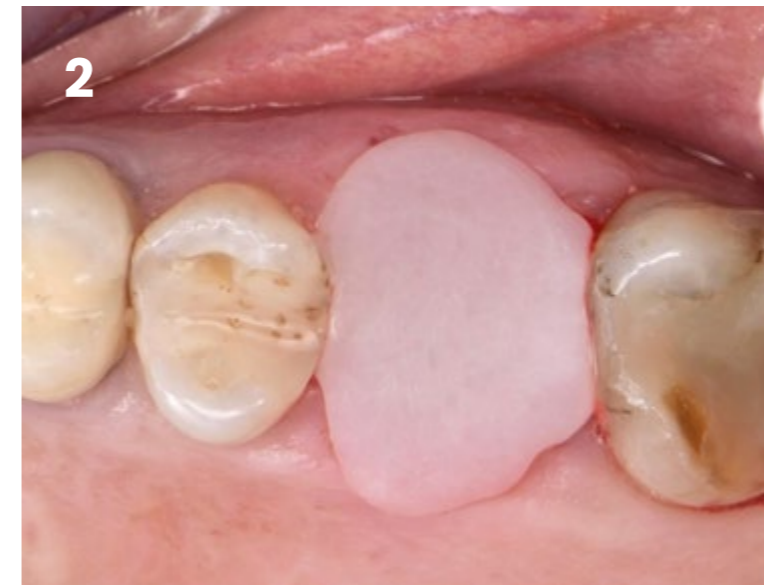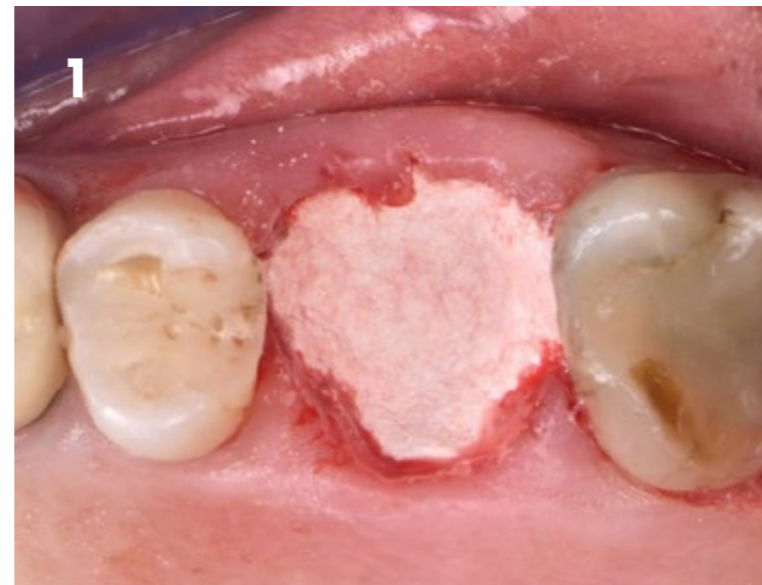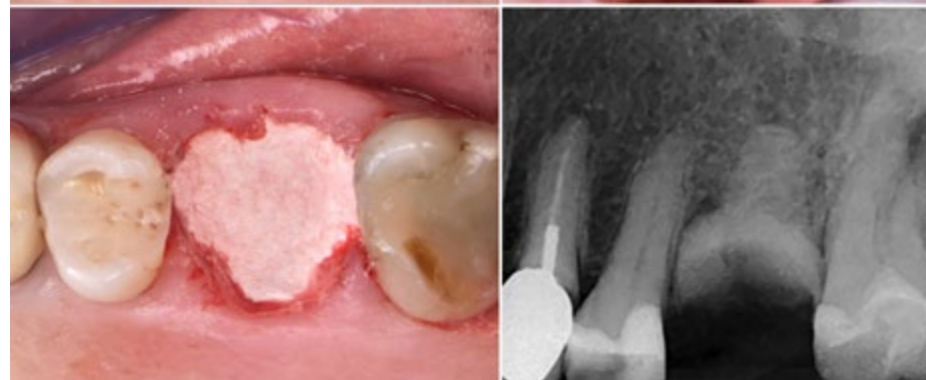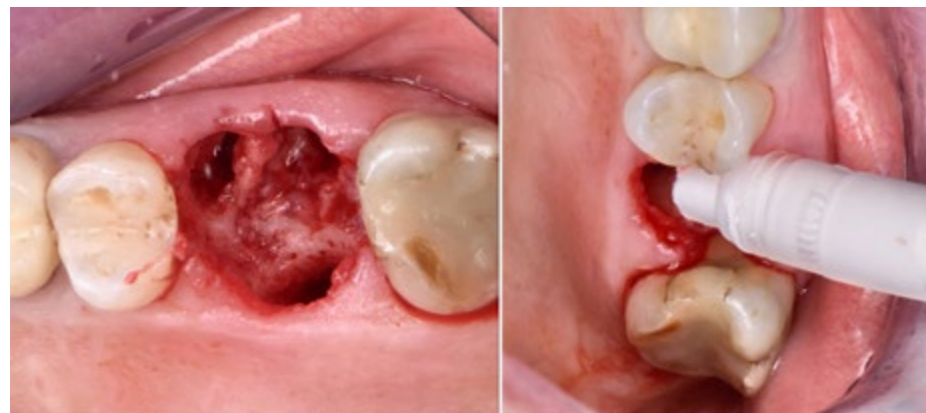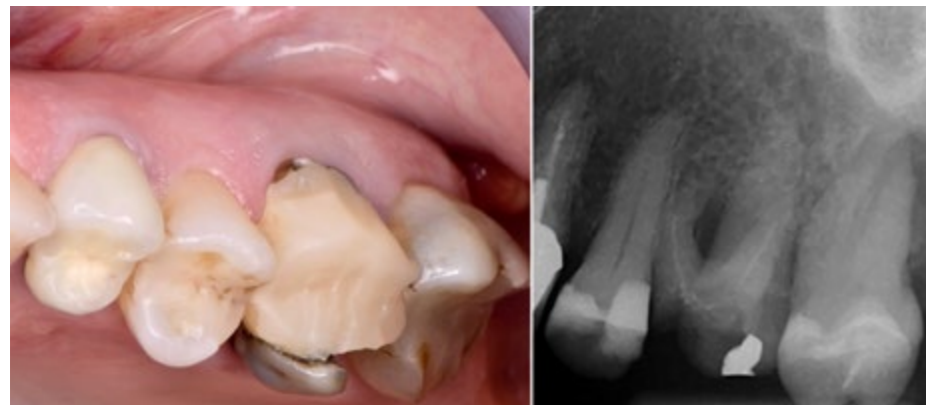"The Elemental polymer stayed in place the first 3 days. My plan was to remove it the 10th post-op day, but the patient had no pain at all so he decided to take scissors and removed by himself at home"

10 day follow-up

"10 days after the extraction and the socket grafting with cancellous allograft. All the graft is in place, fully covered, and embedded in newly-formed connective tissue. Already there is new epithelium proliferating from the periphery. No inflammation, no infection, no pain, no swelling."

Application


“Using Elemental Oral Surgical Granulate as a Novel Socket Barrier Concept” – Clinical report by Dr. Minas Leventis



The Elemental polymer dressing was placed over the grafted extraction site, and by applying gentle tactile pressure, it formed a barrier over the grafted socket (fig. 2), covering completely the underlying graft, and extending approximately three millimeters over the surrounding soft tissues. In a few seconds, polymer dressing had hardened in situ and a small number of sutures (SKD monofilament 5-0) were placed to stabilize it further (fig. 3).

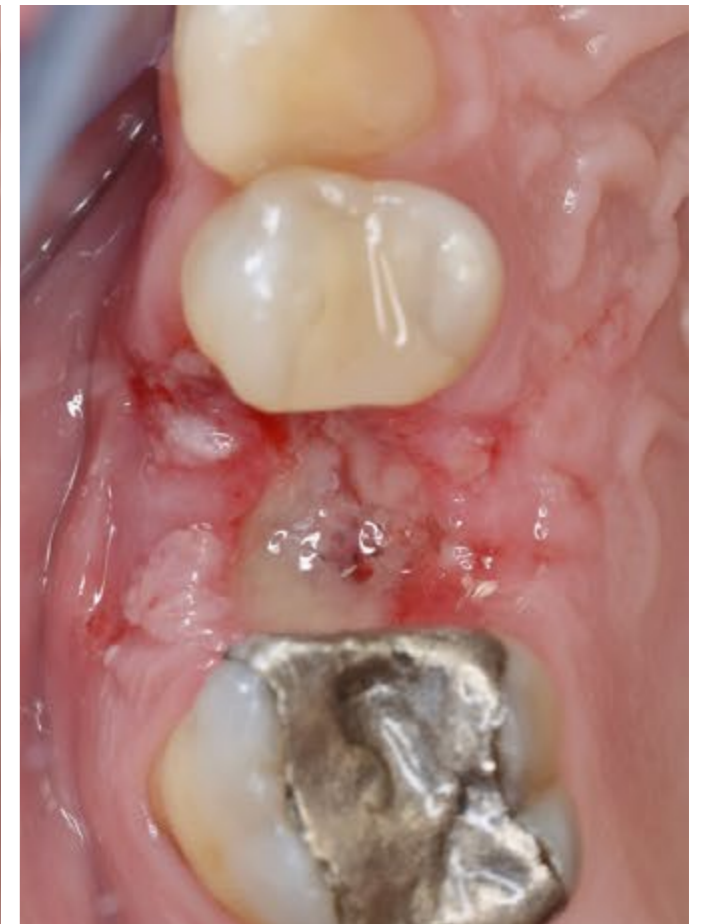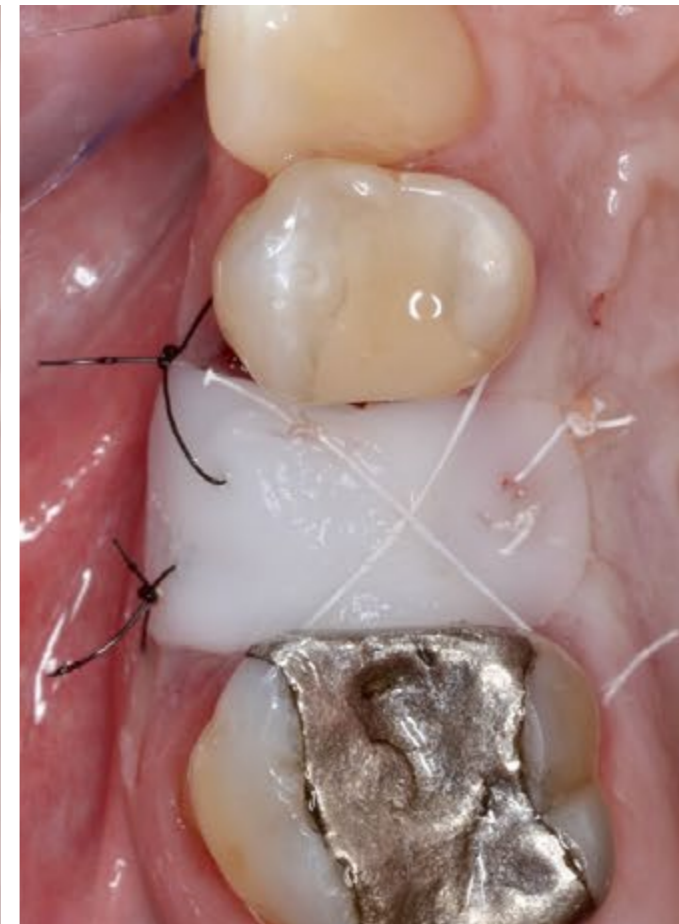
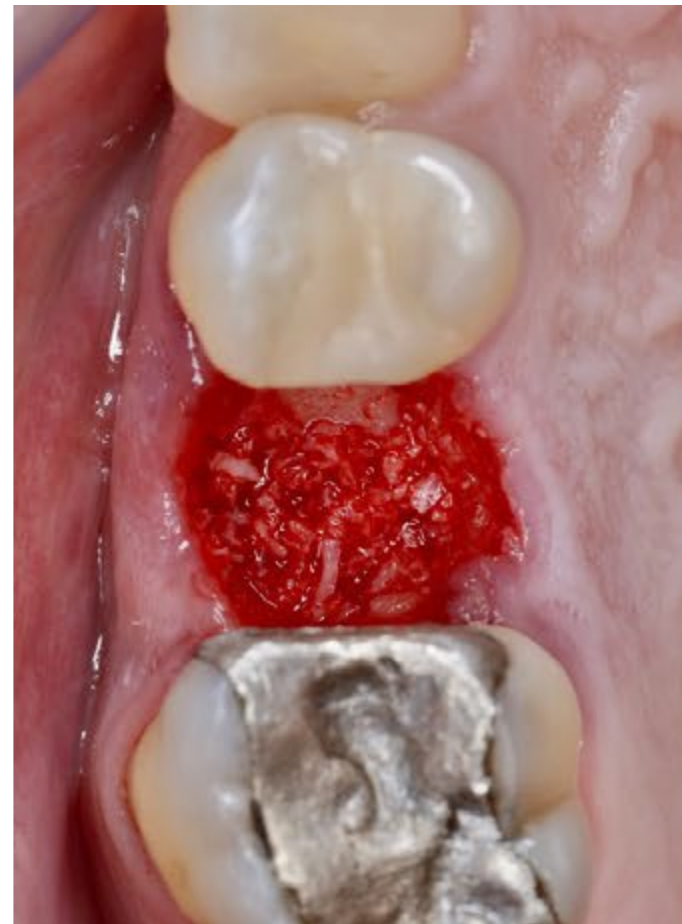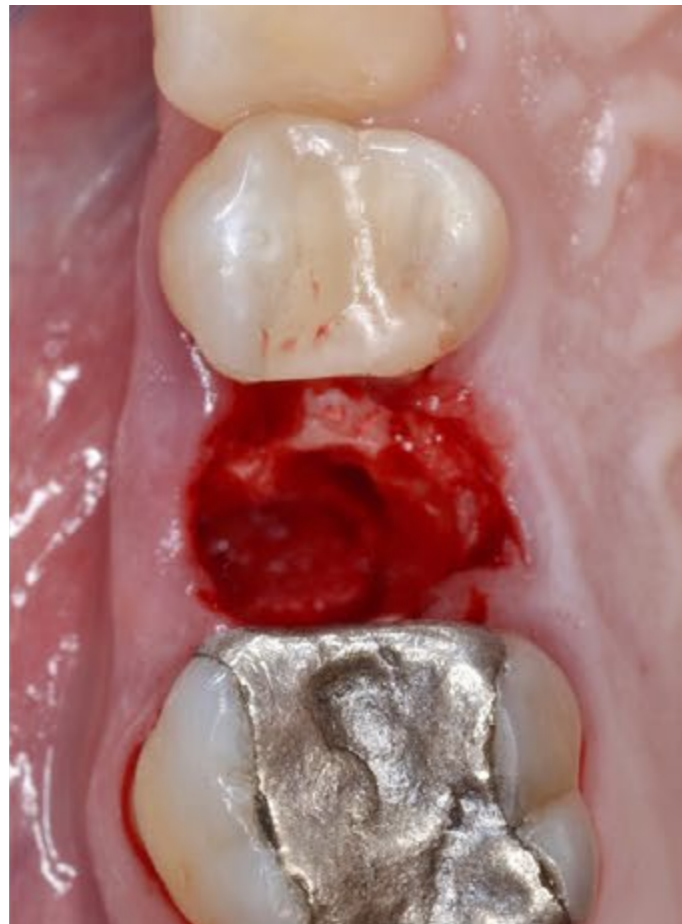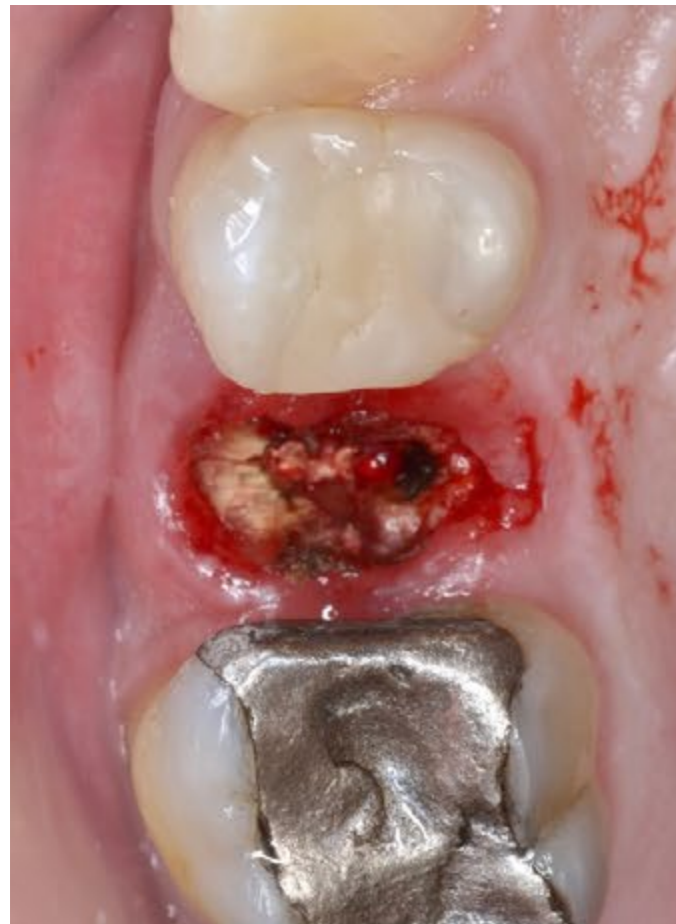Eight days post-op, the Elemental polymer barrier was removed (fig. 4), revealing excellent healing of the area, with no signs of infection, tissue collapse or loss of the graft. The grafted socket was already covered completely by newly-formed uninflamed connective tissue, which proliferated rapidly over the protected bone substitute.

[Read full clinical report](#)



Application

Using Elemental Oral Surgical Granulate as a Novel Socket Barrier Concept



Allogenic cancellous bone

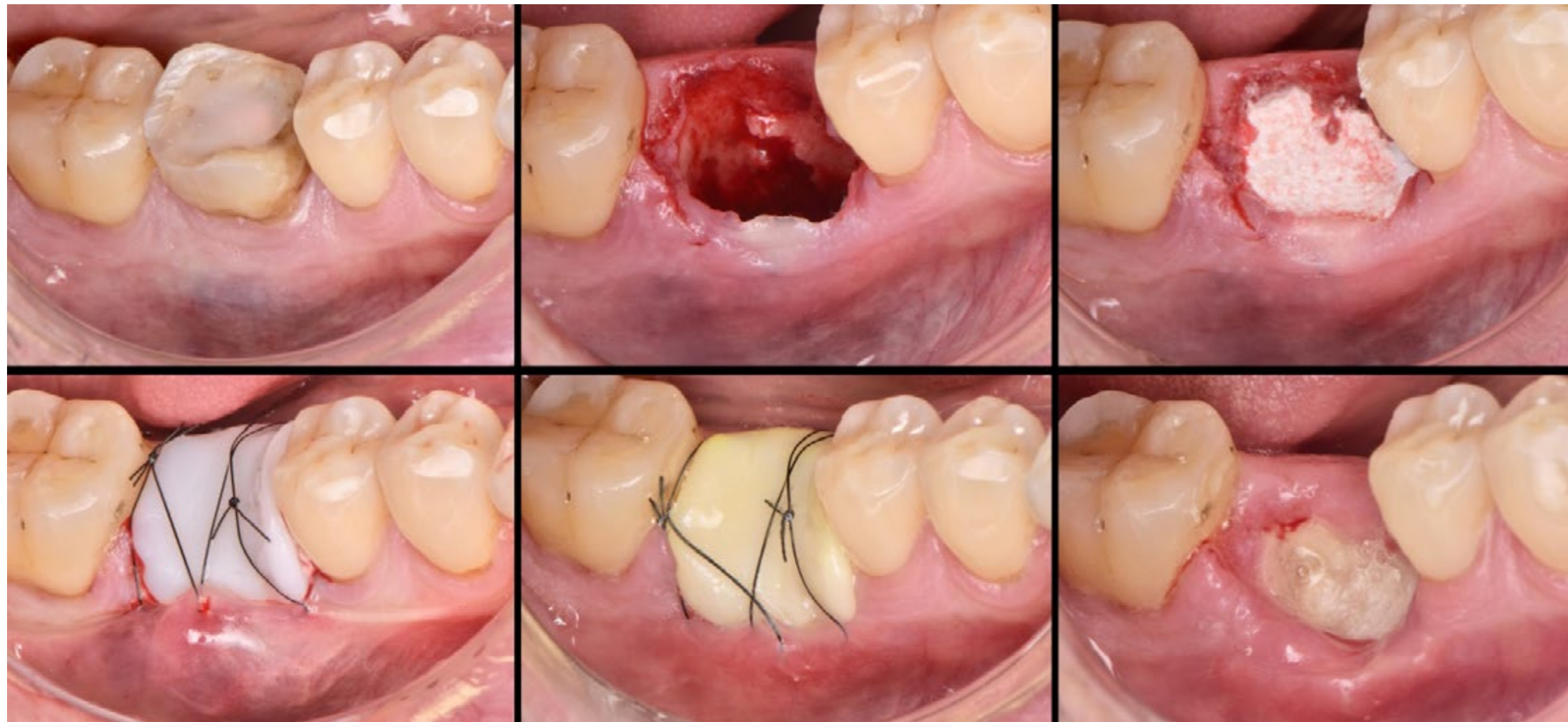
Elemental polymer dressing

3 days post-operative

“Here is a socket graft case where I left the Elemental polymer dressing only for 3 days post-op. Not an easy extraction, there was a small bone dehiscence buccally. I used only allogenic cancellous bone for grafting, no membranes. The major benefit is that in just 3 days the site is covered by connective tissue and we secure the graft in place. I don't think that there is any need to keep the polymer any longer.”

Application

Using Elemental Oral Surgical Granulate as a Novel Socket Barrier Concept



“Here I left the Elemental 6 days. Very difficult extraction as the roots were ankylosed, I managed to remove it without raising a flap, no septal bone and defective buccal plate.

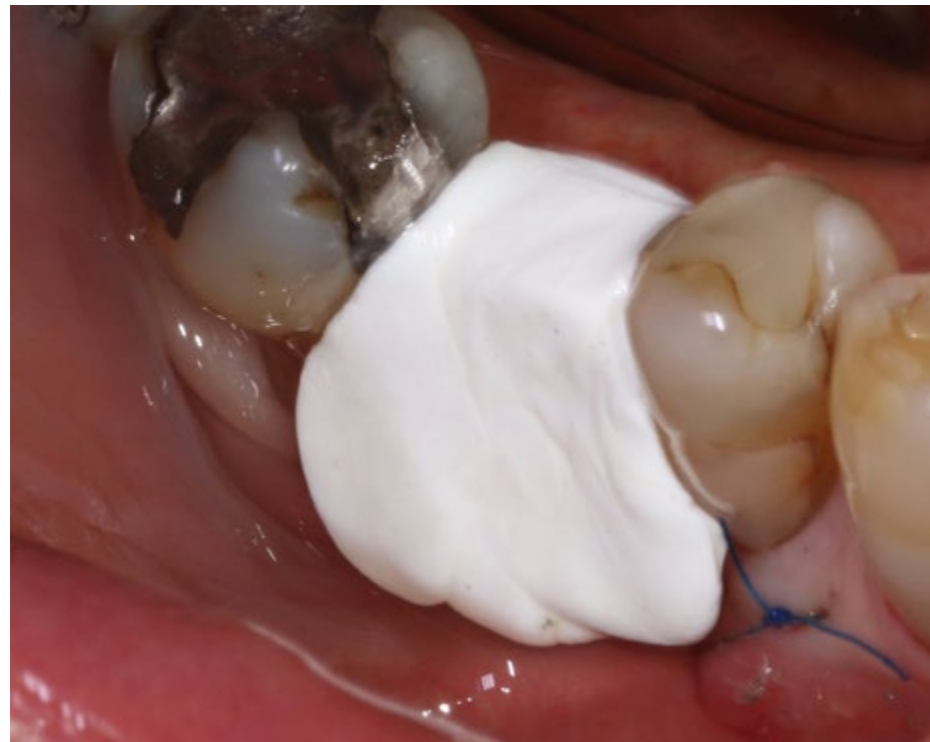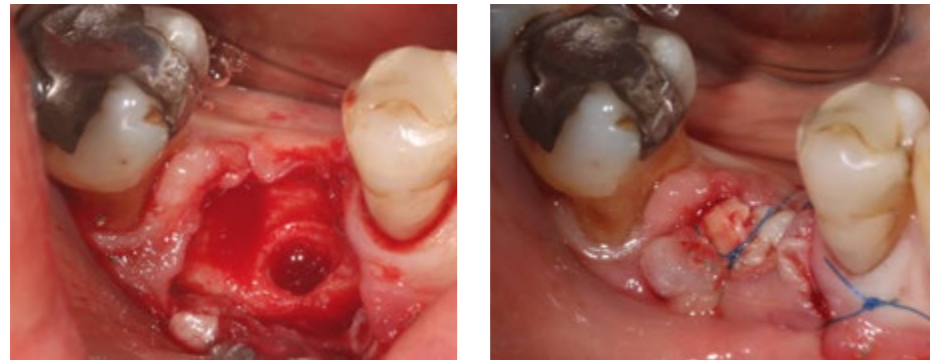Grafted with 0.5 cc synthetic silicate b-TCP, no collagen on top, no membrane, no flap to cover it. I stabilised the elemental with two criss cross 5-0 sutures and removed it after 6 days. Even without the stitches it was nicely stable and blocked between the adjacent teeth. The patient had no pain, no swelling, no discomfort, just the area was slightly tender the first days. Excellent result considering it was not an easy extraction.

In my opinion the outcome in this case and clinical scenario is excellent and the polymer fulfilled it’s role perfectly: It protected the graft and improved the open healing of the site. So there was no graft loss, which is the main issue, and in 6 days we can observe clinically that the graft is embedded into a rich fibrin network and which is already getting covered by healthy granulation tissue and new epithelium, migrating from the margins of the socket. I believe that the graft is now safe and stable, and the area will heal perfectly by secondary intention, without the need for the polymer anymore.

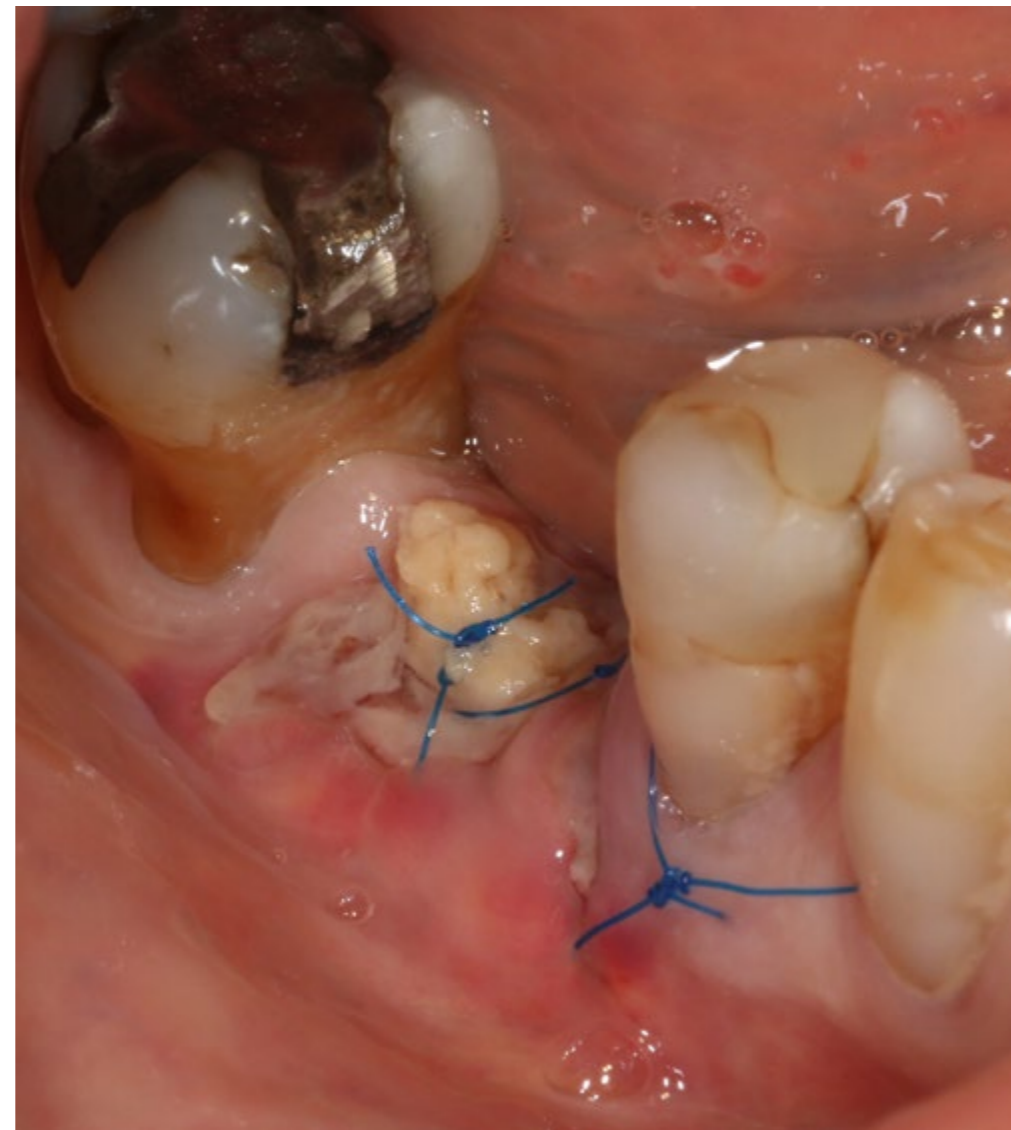
In conclusion, I believe that the Elemental played a crucial role during the first days of healing of the grafted socket, and this first stage of healing is the most important.”

Application

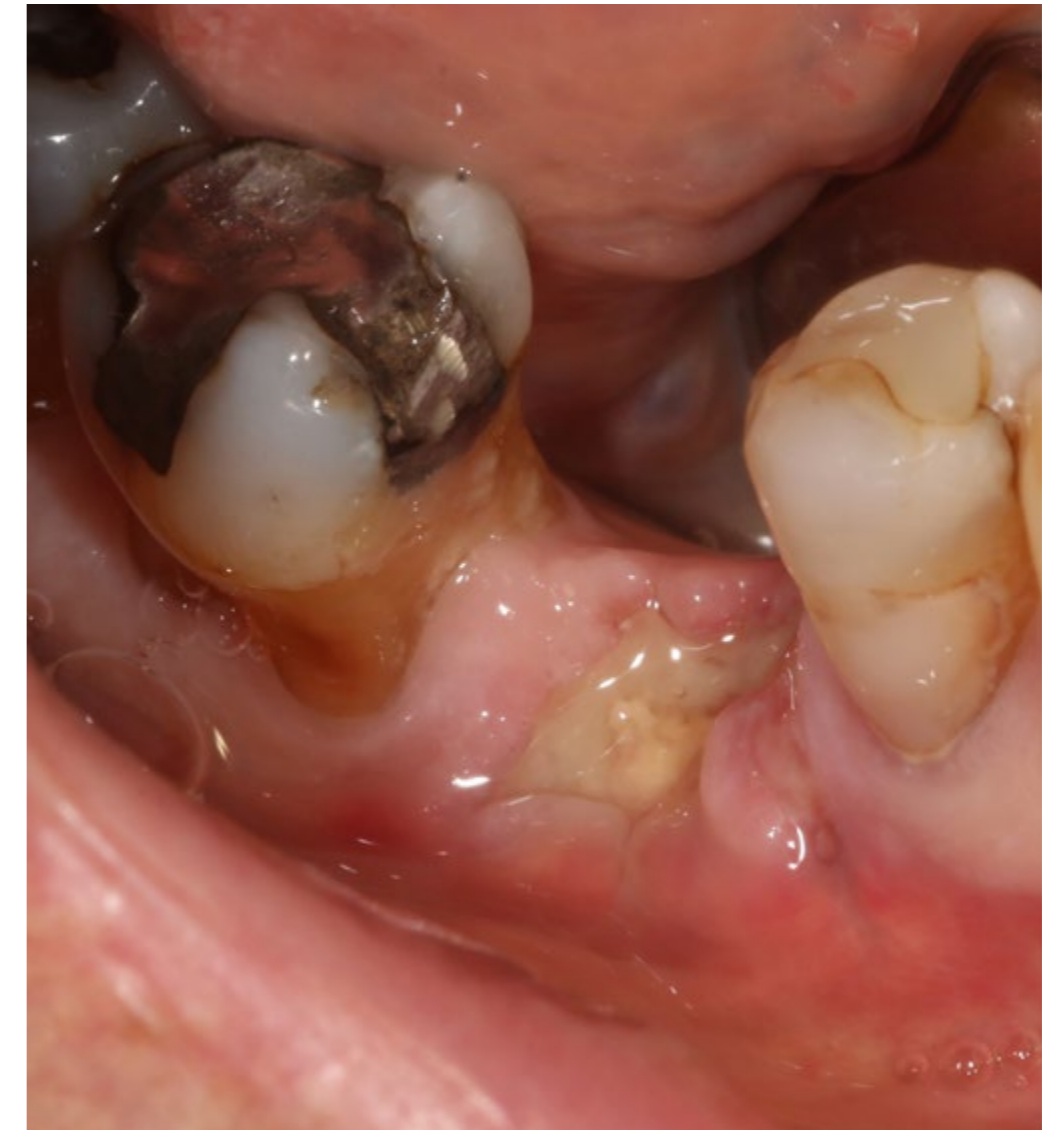Coverage of the extraction socket after explant and placement of PRF in implant case.



Day of surgery



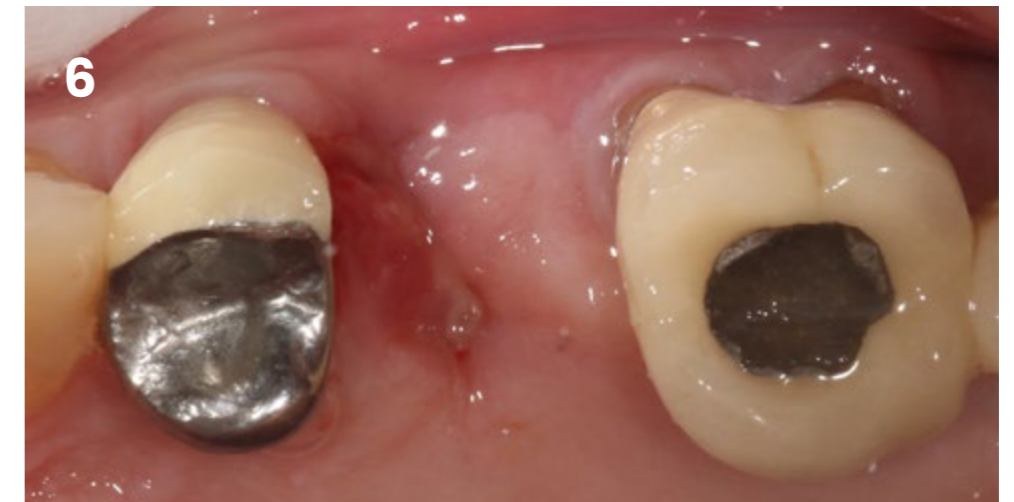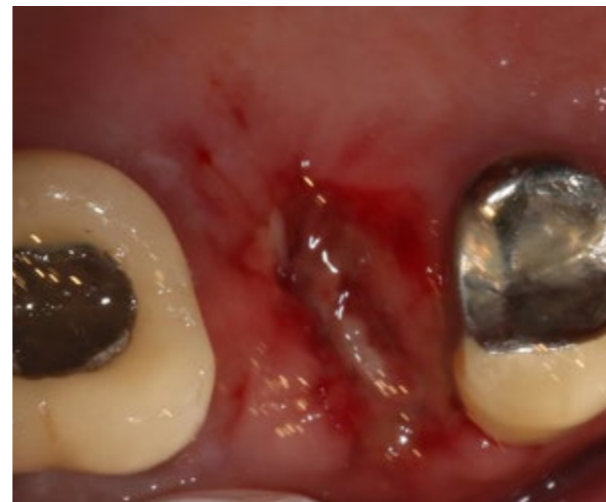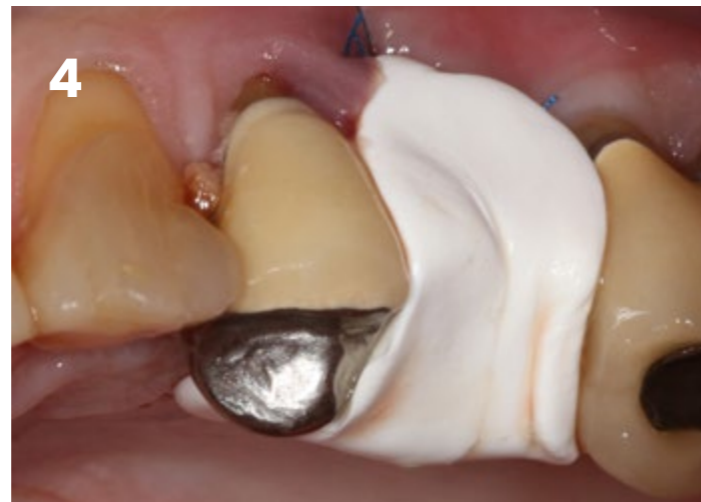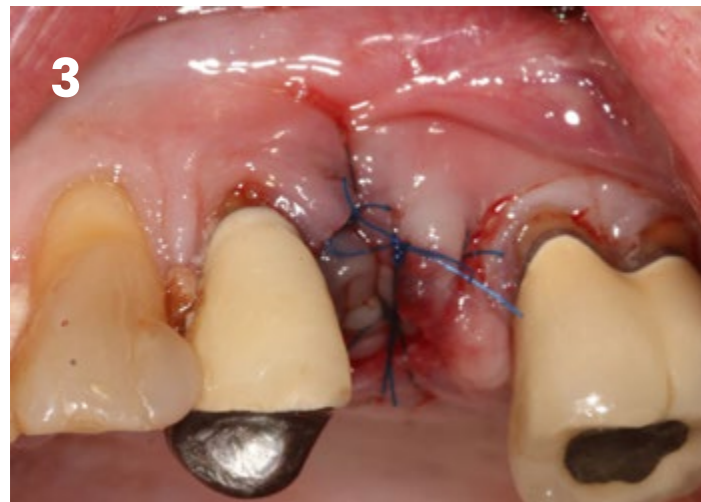
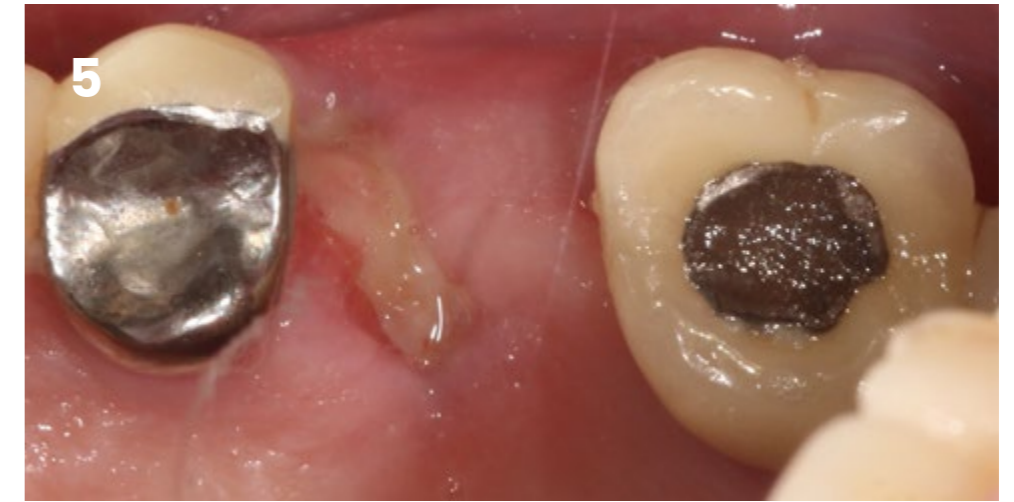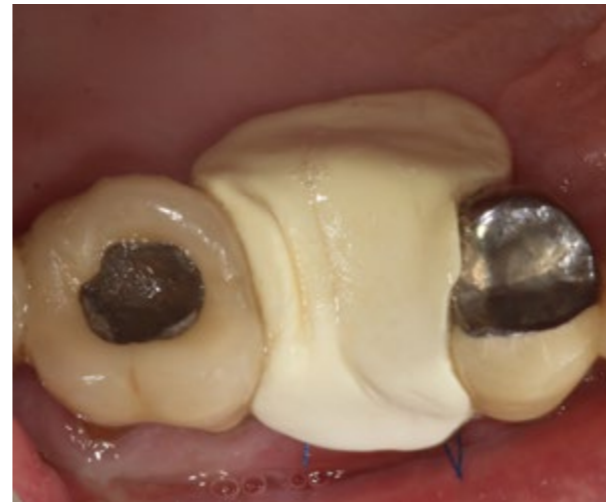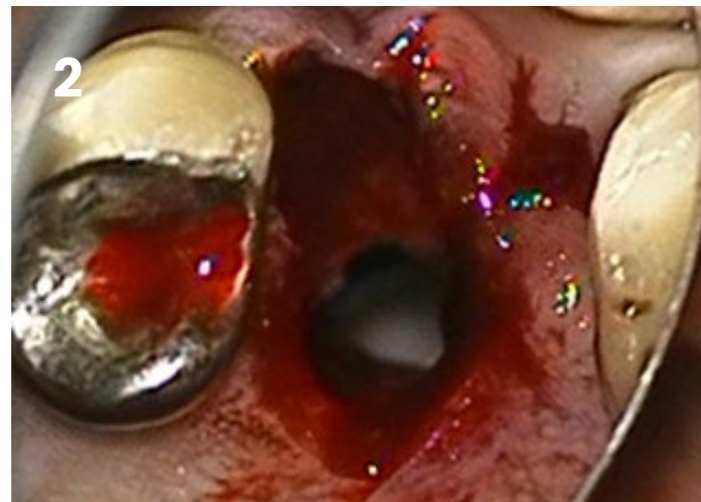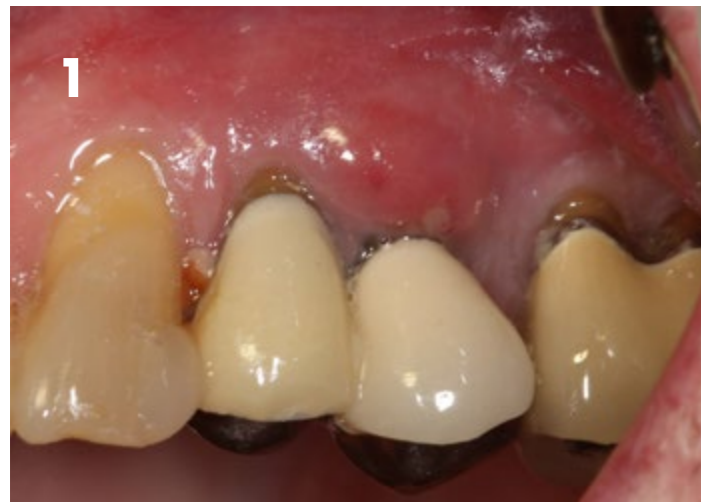4 days post-operative



10 days post-operative

Application

Sealing of the extraction socket after PRF placement



Day of surgery

Fig 1: pre-operative, Fig 2: perforation, Fig. 3: placement of PRF, Fig. 4: coverage with Elemental

7 days post-operative

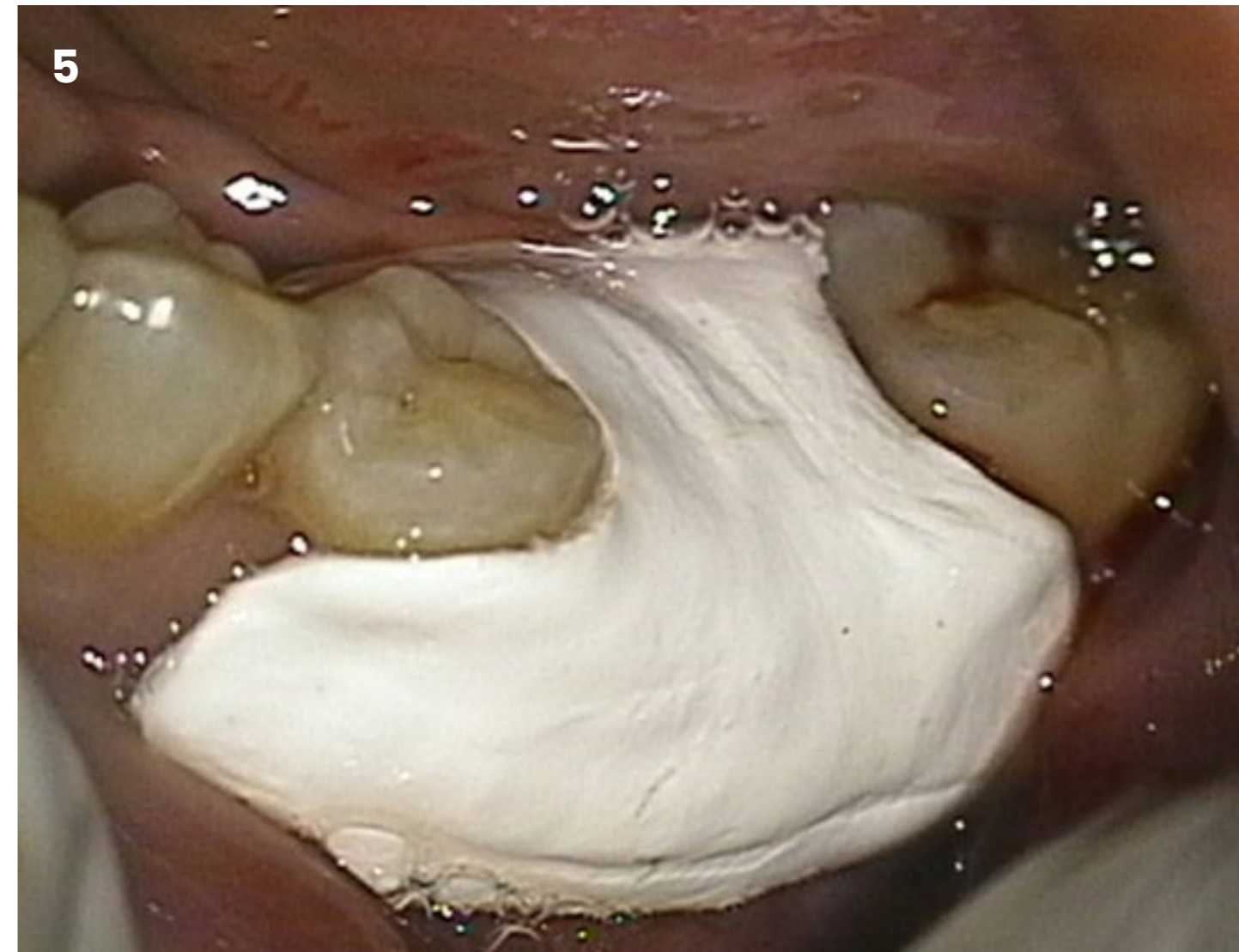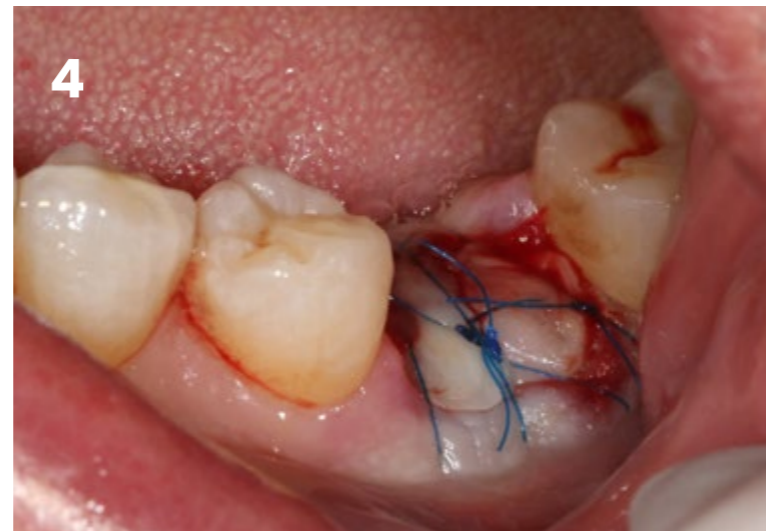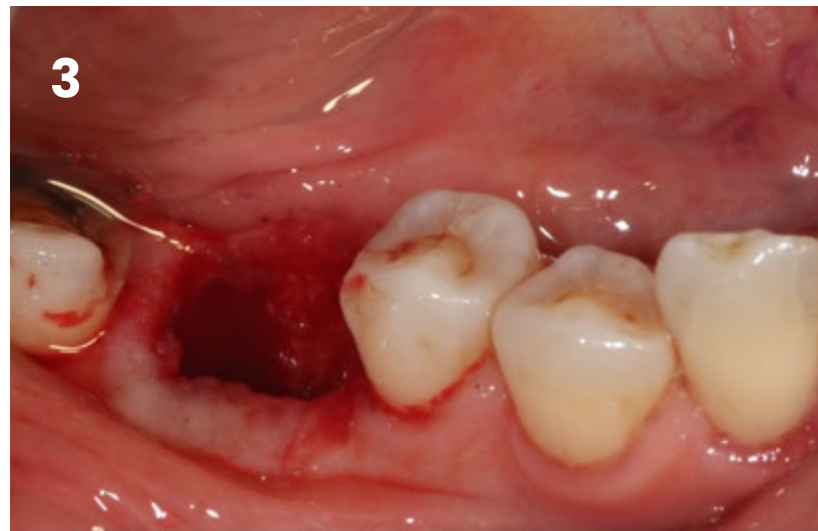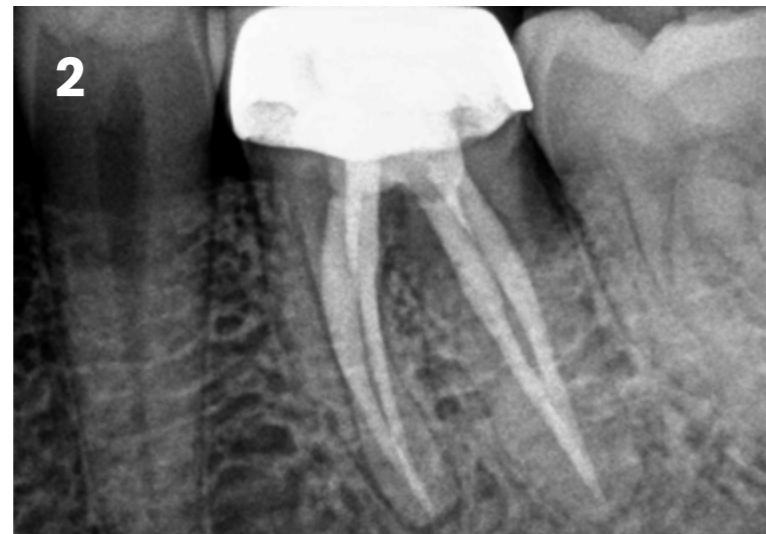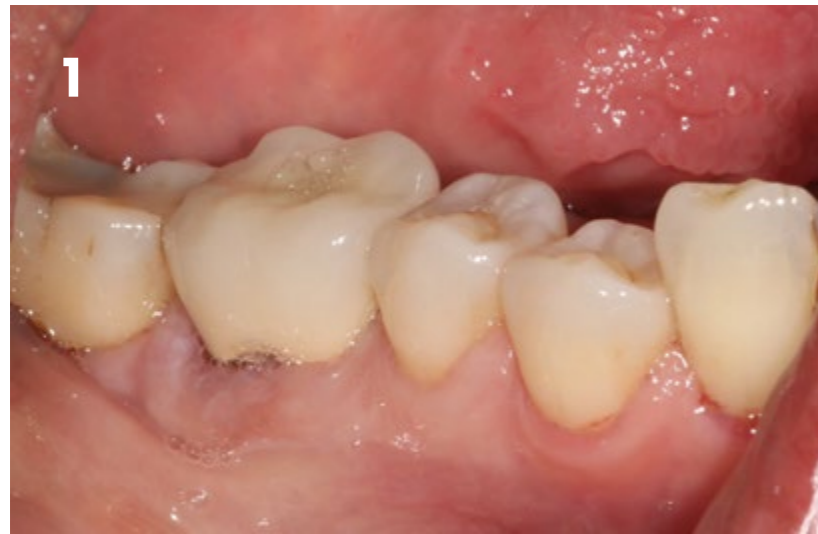Removal of Elemental

10 days, 16 days post-operative

10 days post-op (fig. 5), 16 days post-op (fig. 6)

Application

Sealing of the extraction socket after PRF placement

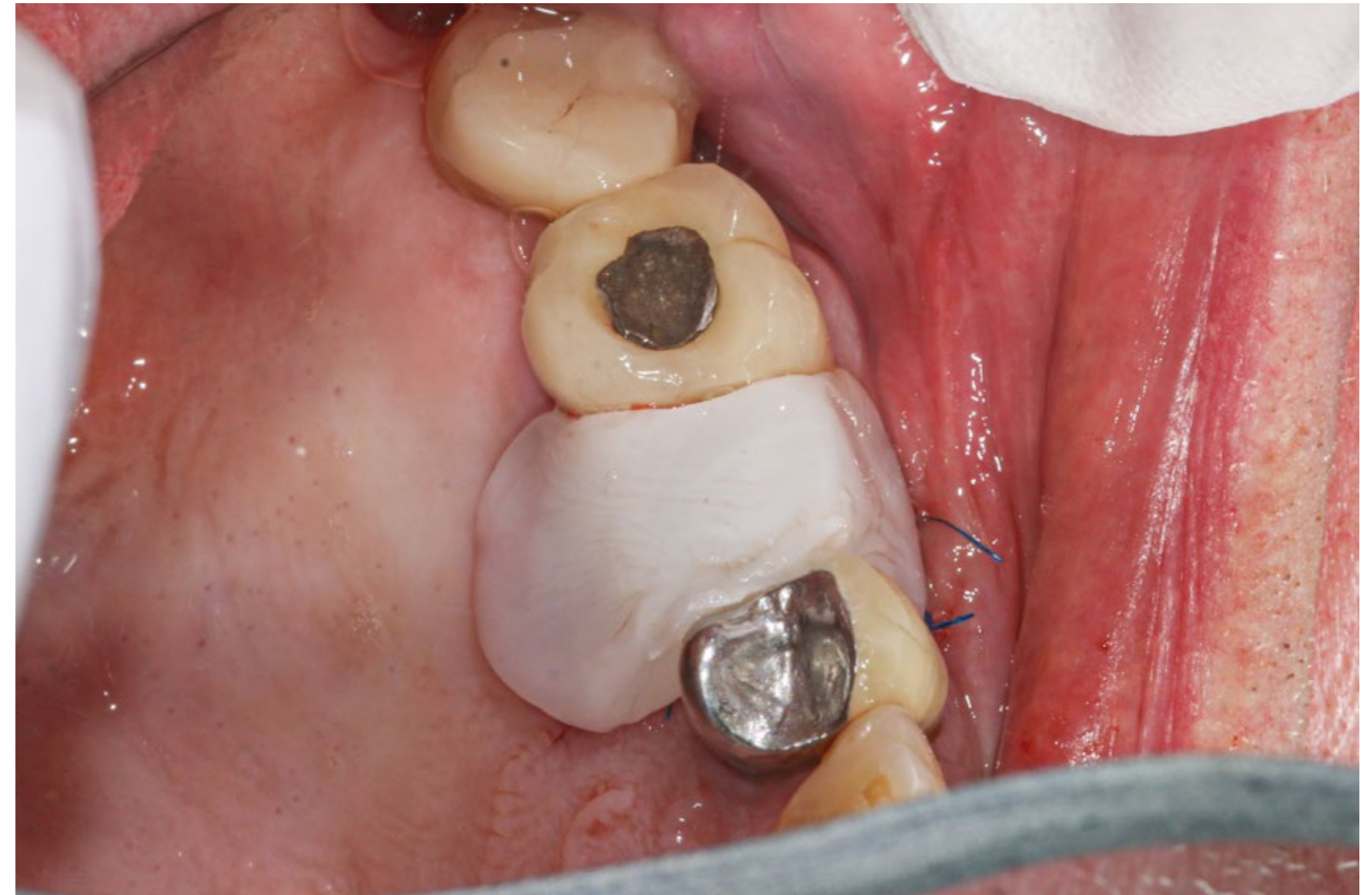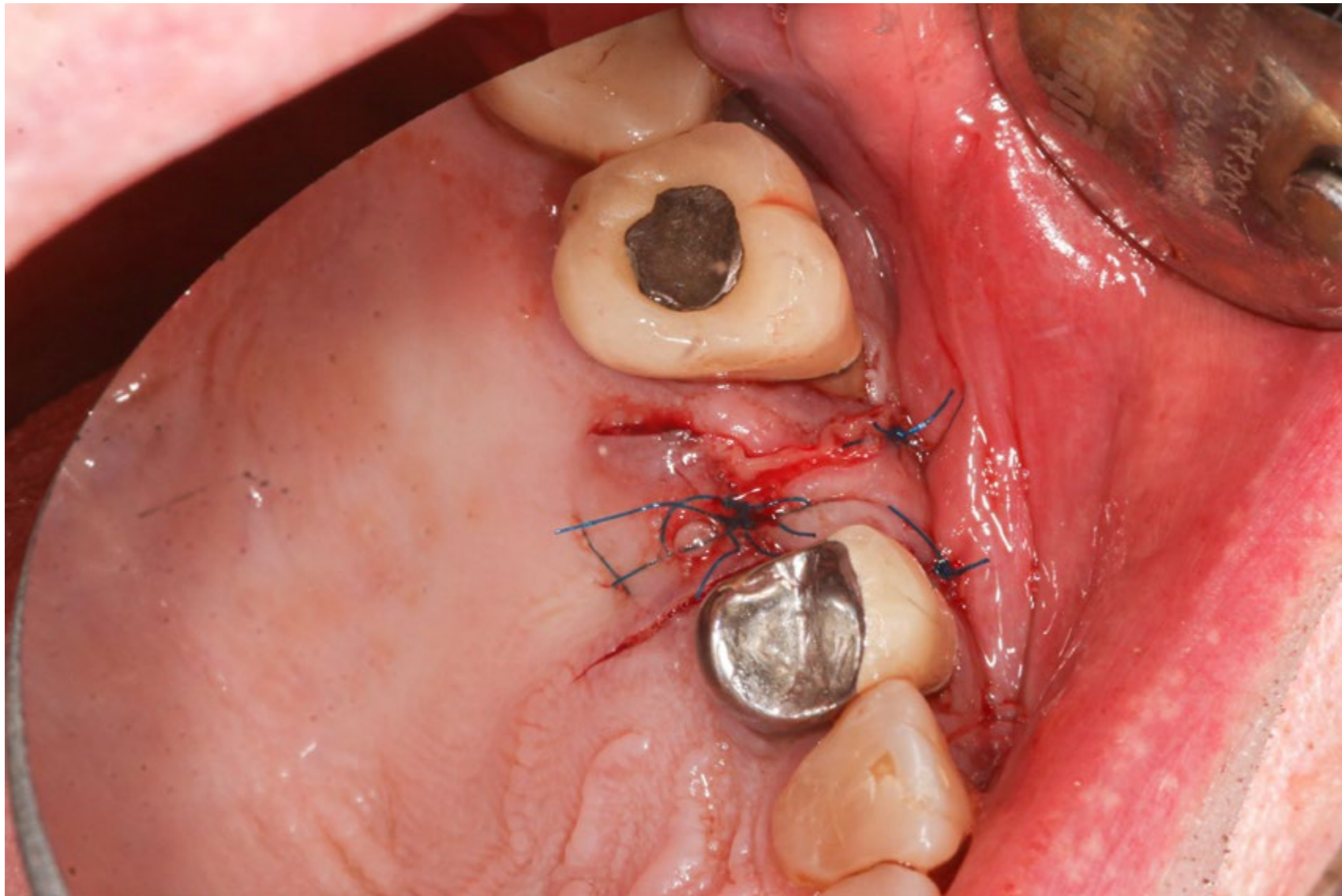


Day of surgery

Fig. 1: pre-operative view, Fig. 2: x-ray, Fig. 3: extraction, Fig. 4: PRF placed and sutured, Fig. 5: Elemental barrier placed.

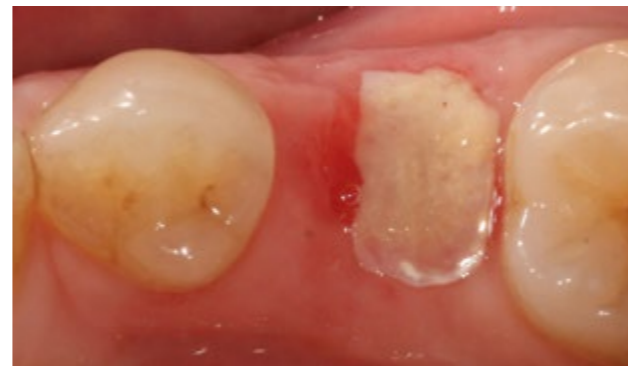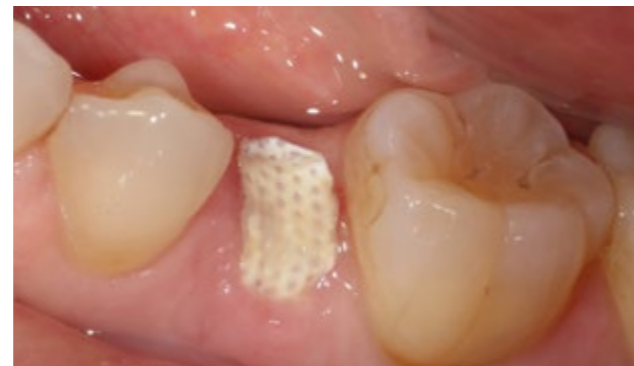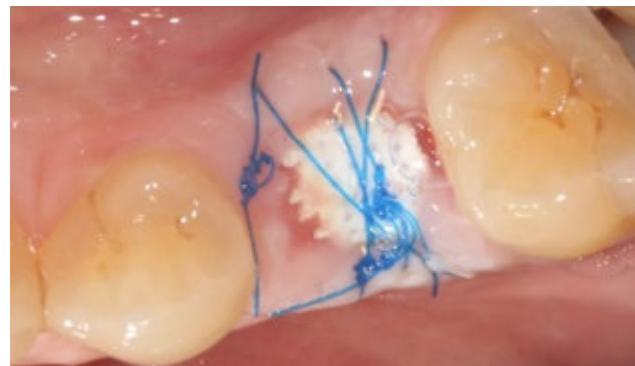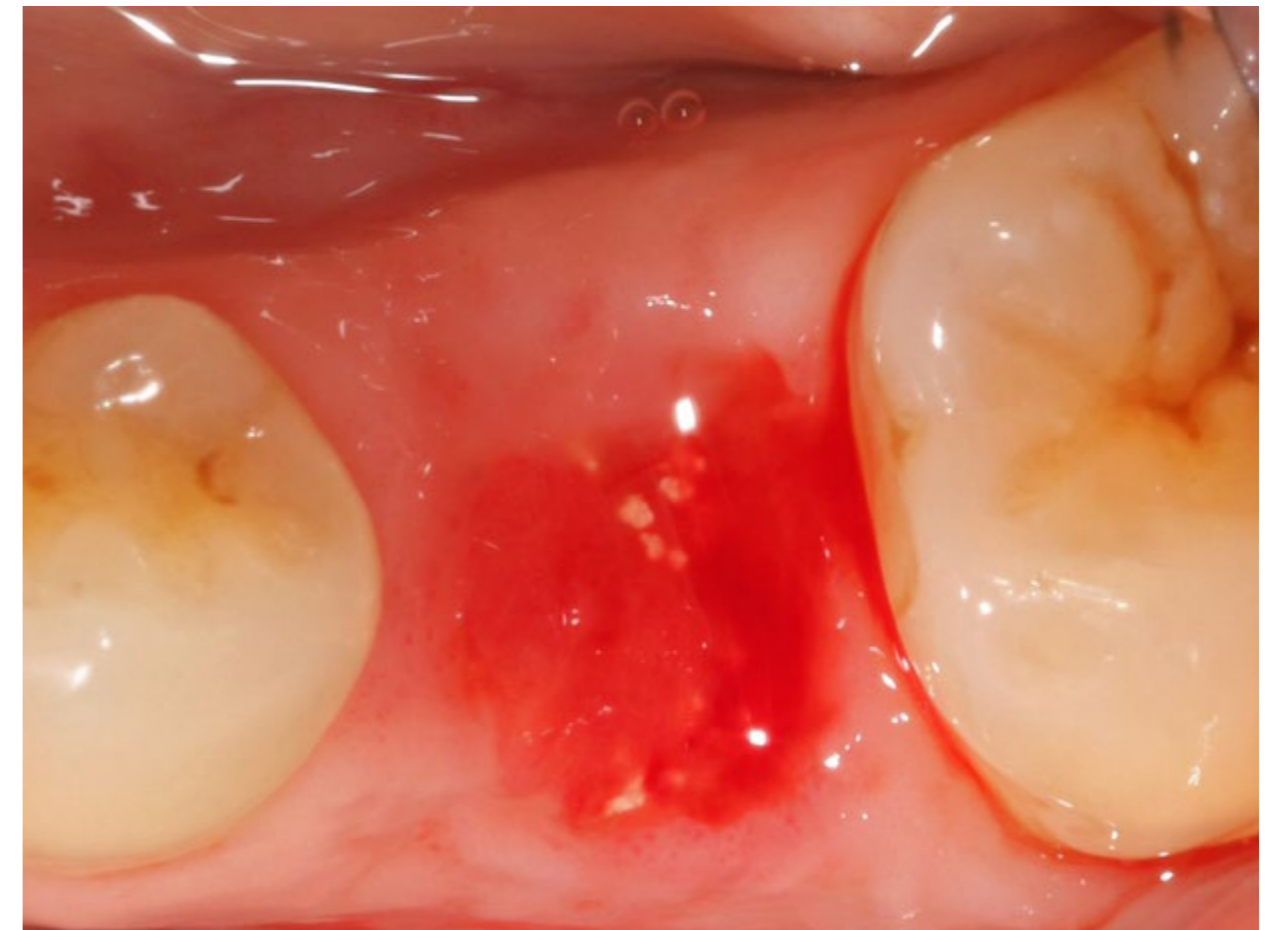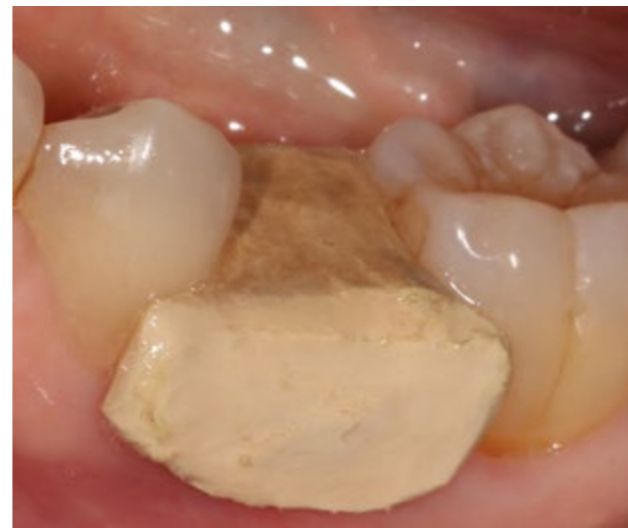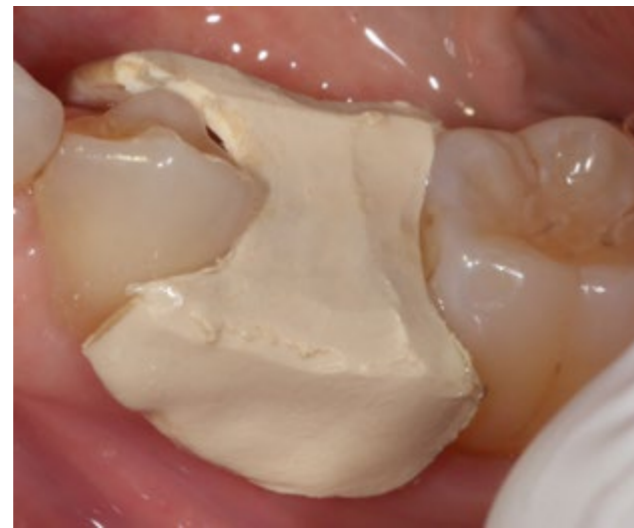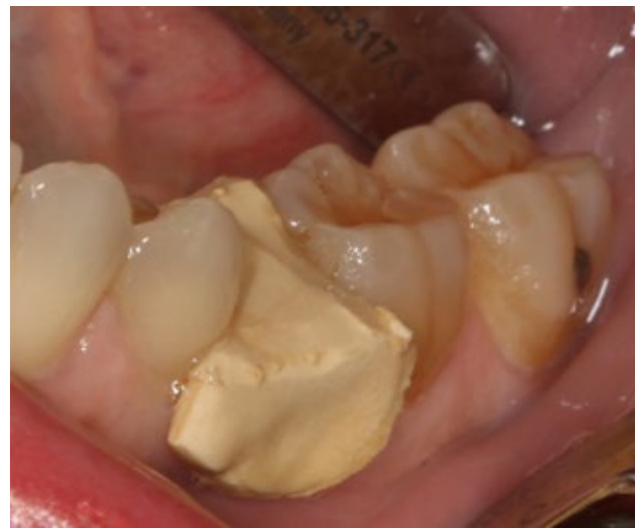Application

Sealing of the extraction socket after PRF placement



Application

Sealing of the extraction socket with membrane



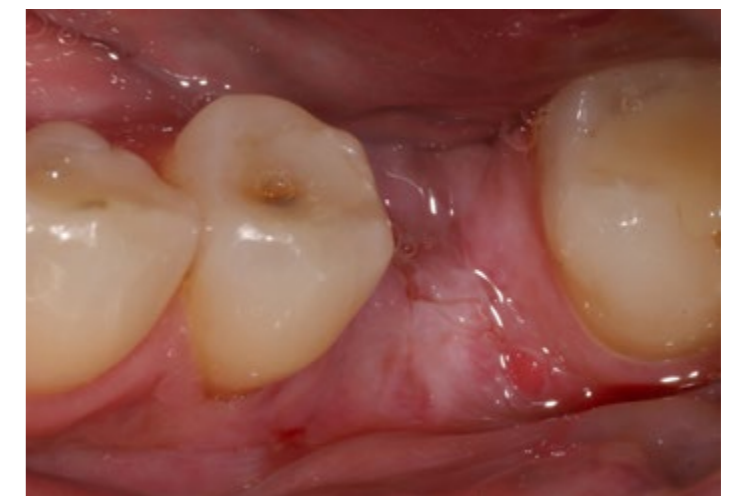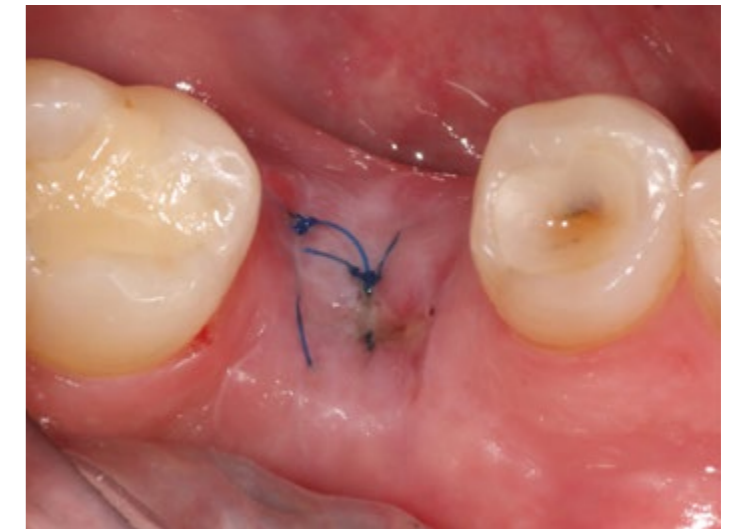
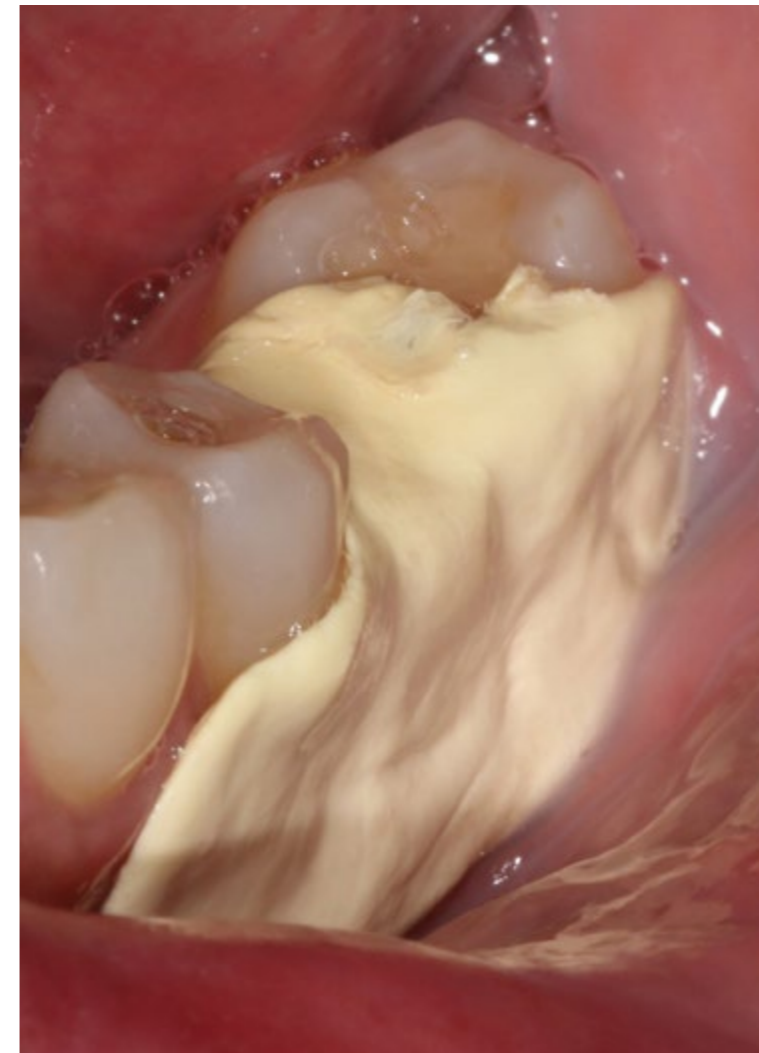
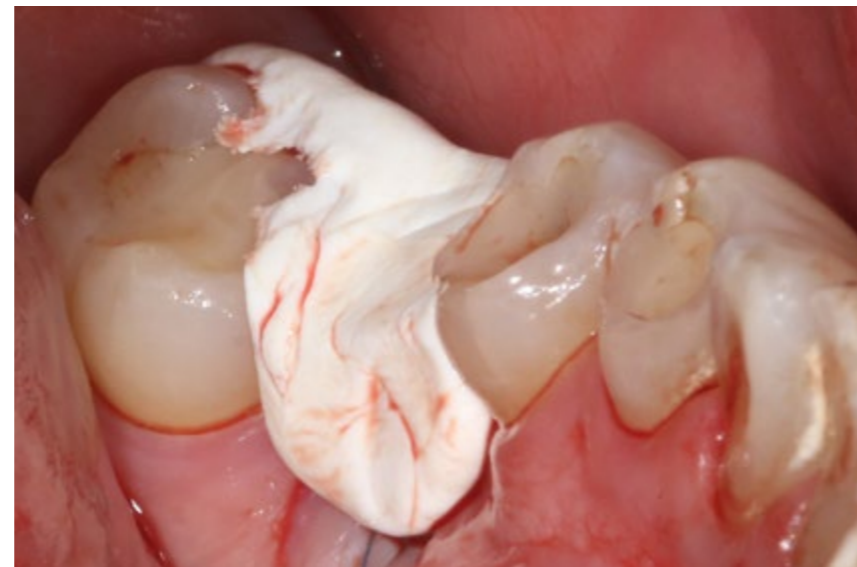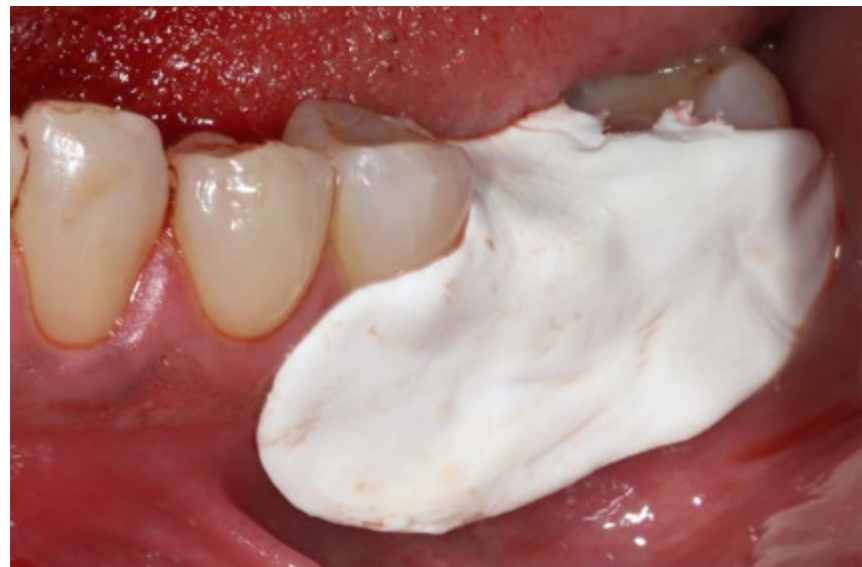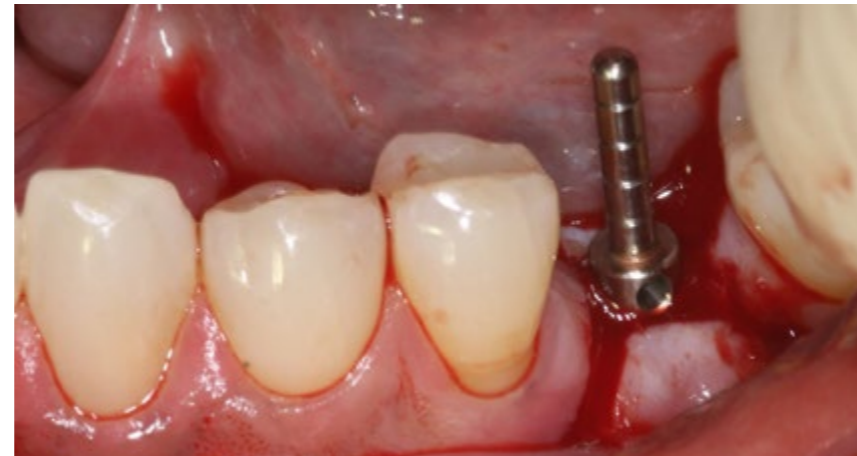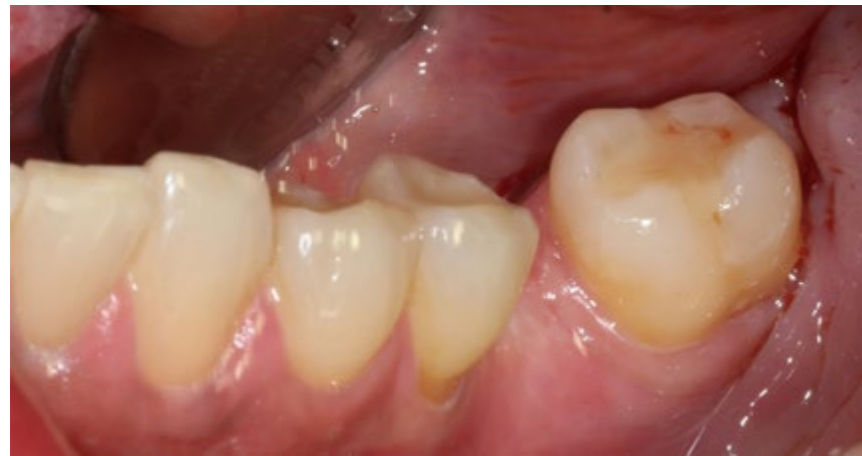4 days post-operative

3 weeks post-operative

4 weeks post-operative

Application

Sealing of extraction site before implant placement



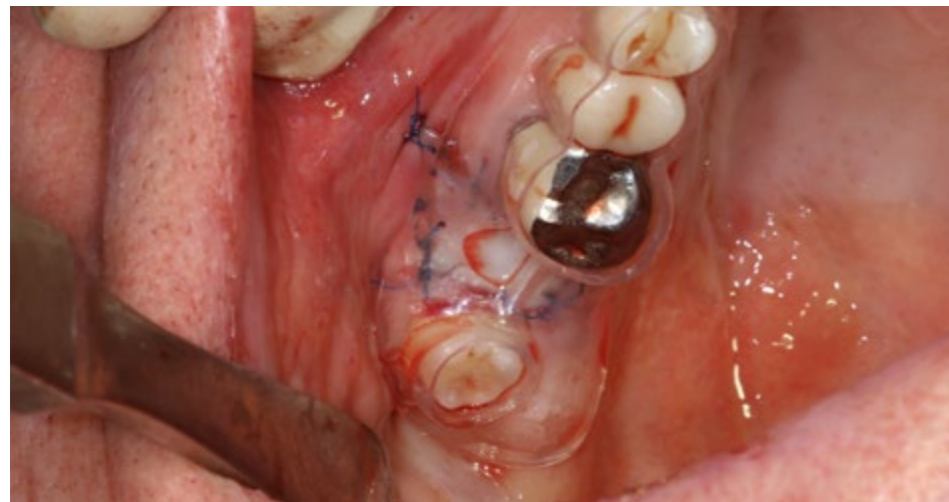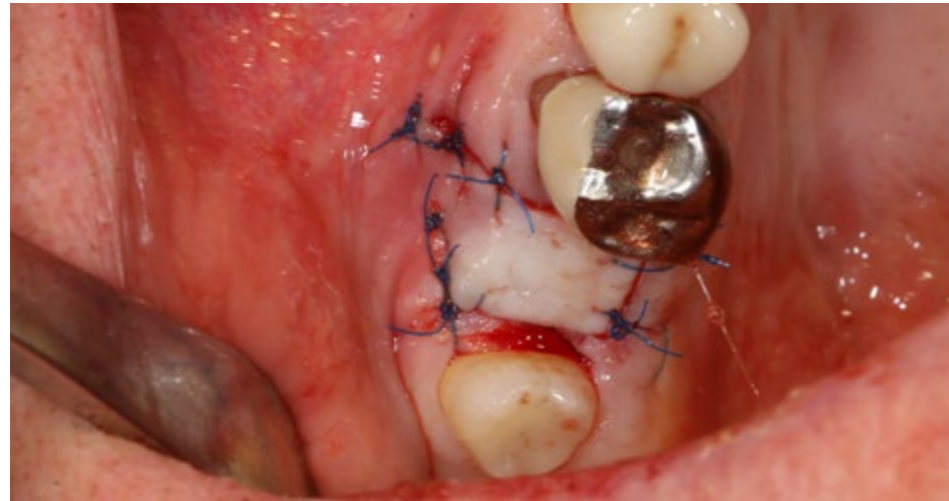
Day of surgery

9 days post-operative

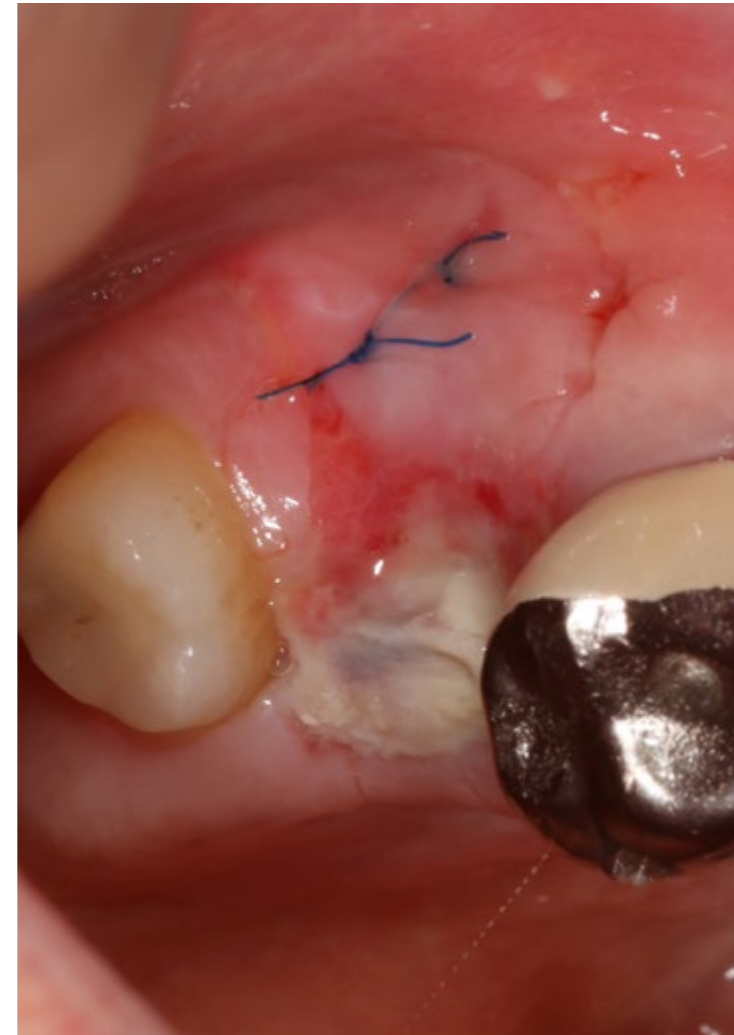

Application

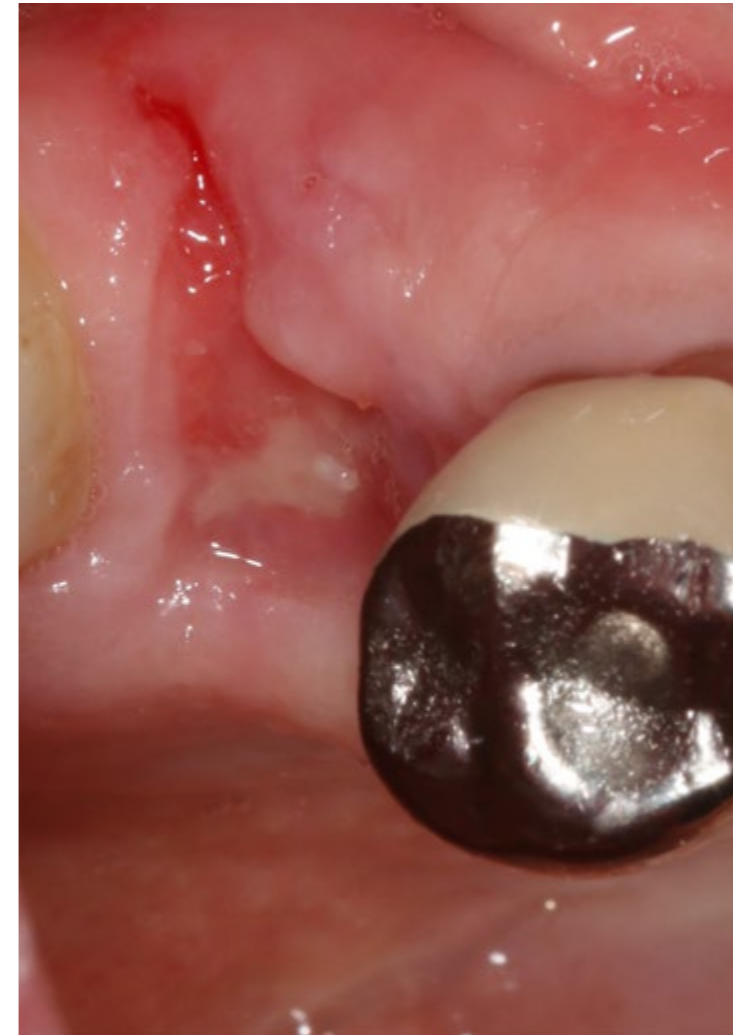Coverage of implant site



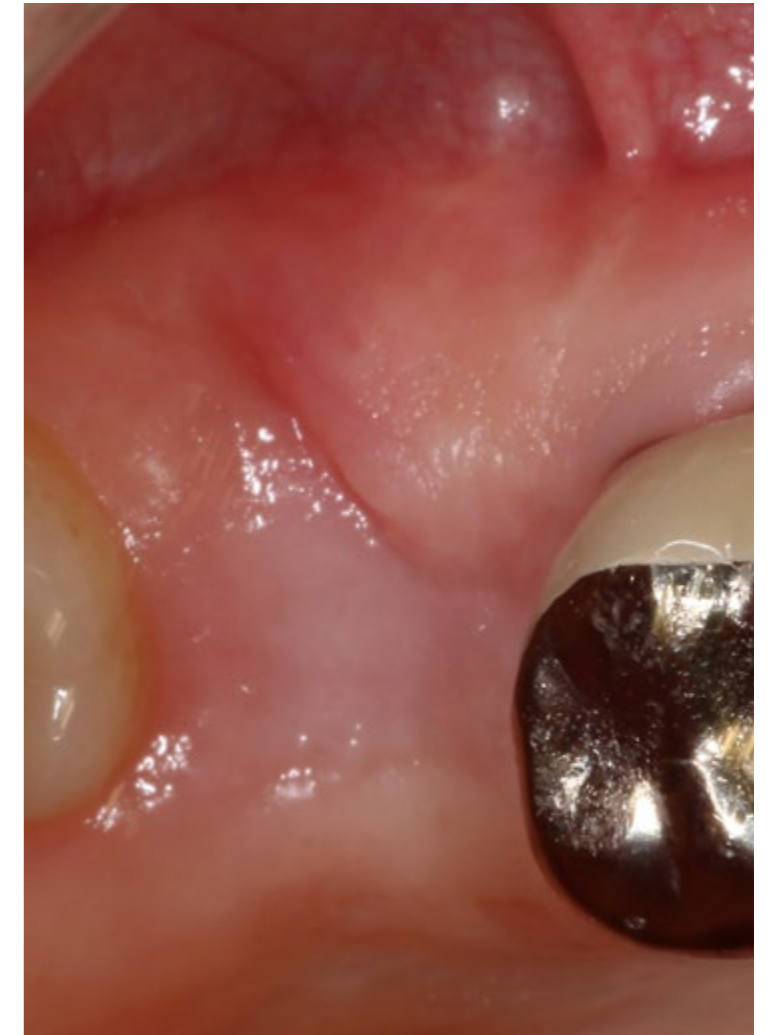
Day of surgery



5 days post-operative



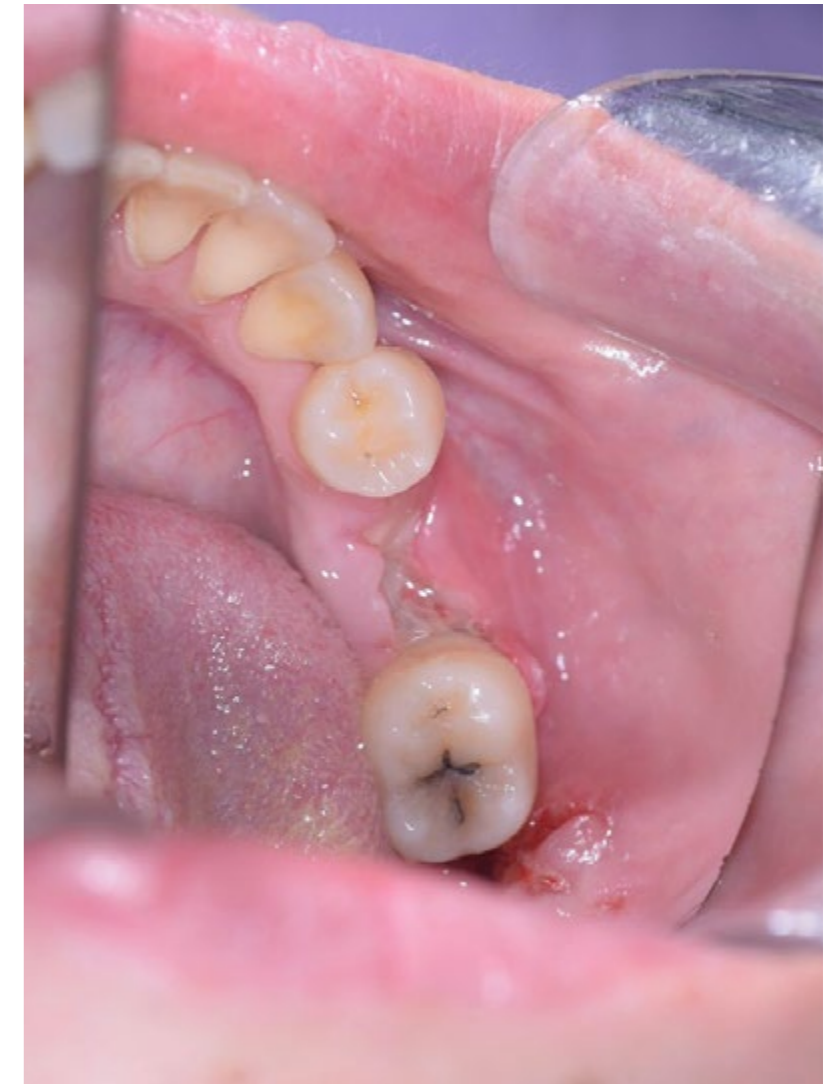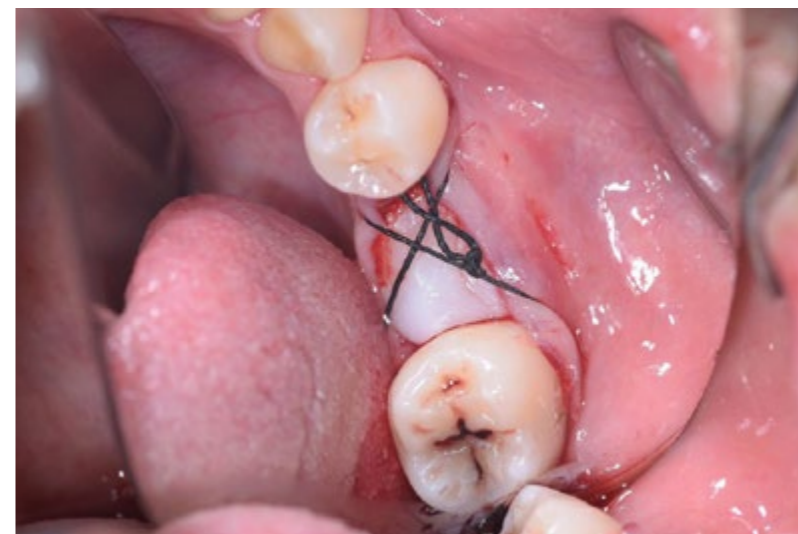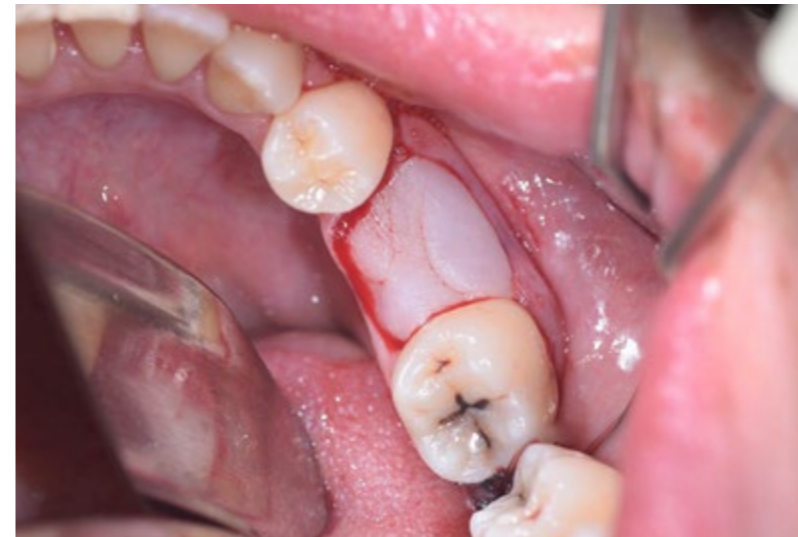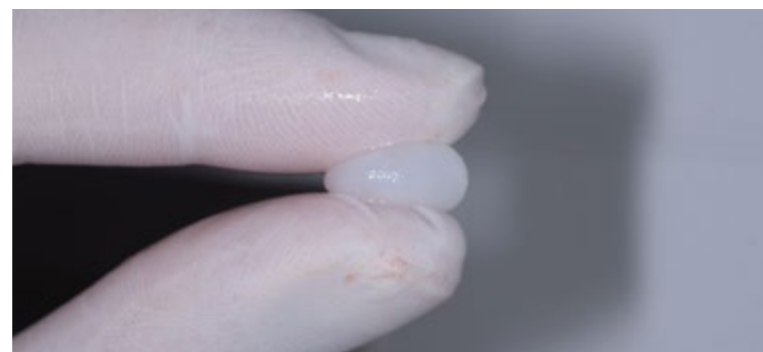
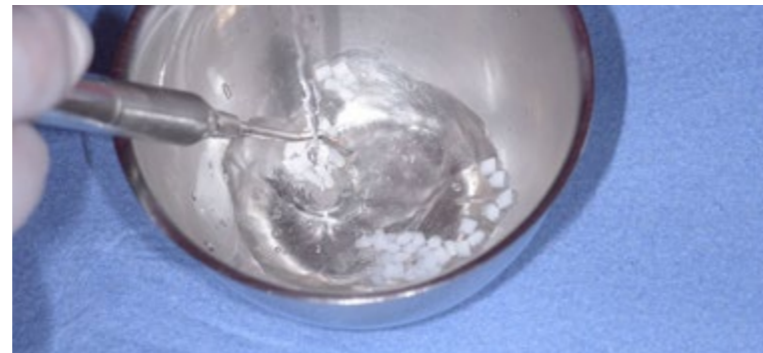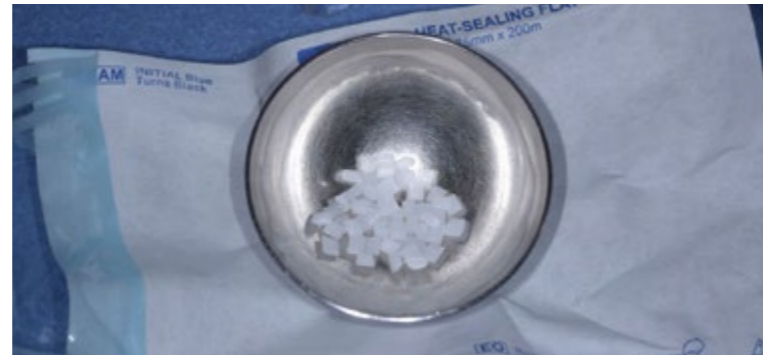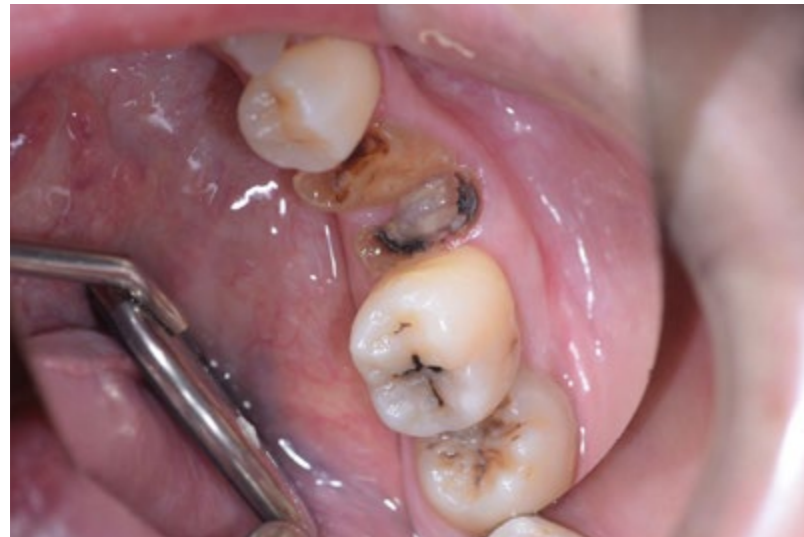4 weeks post-operative



8 weeks post-operative

Application

Sealing of extraction site after PRF placement

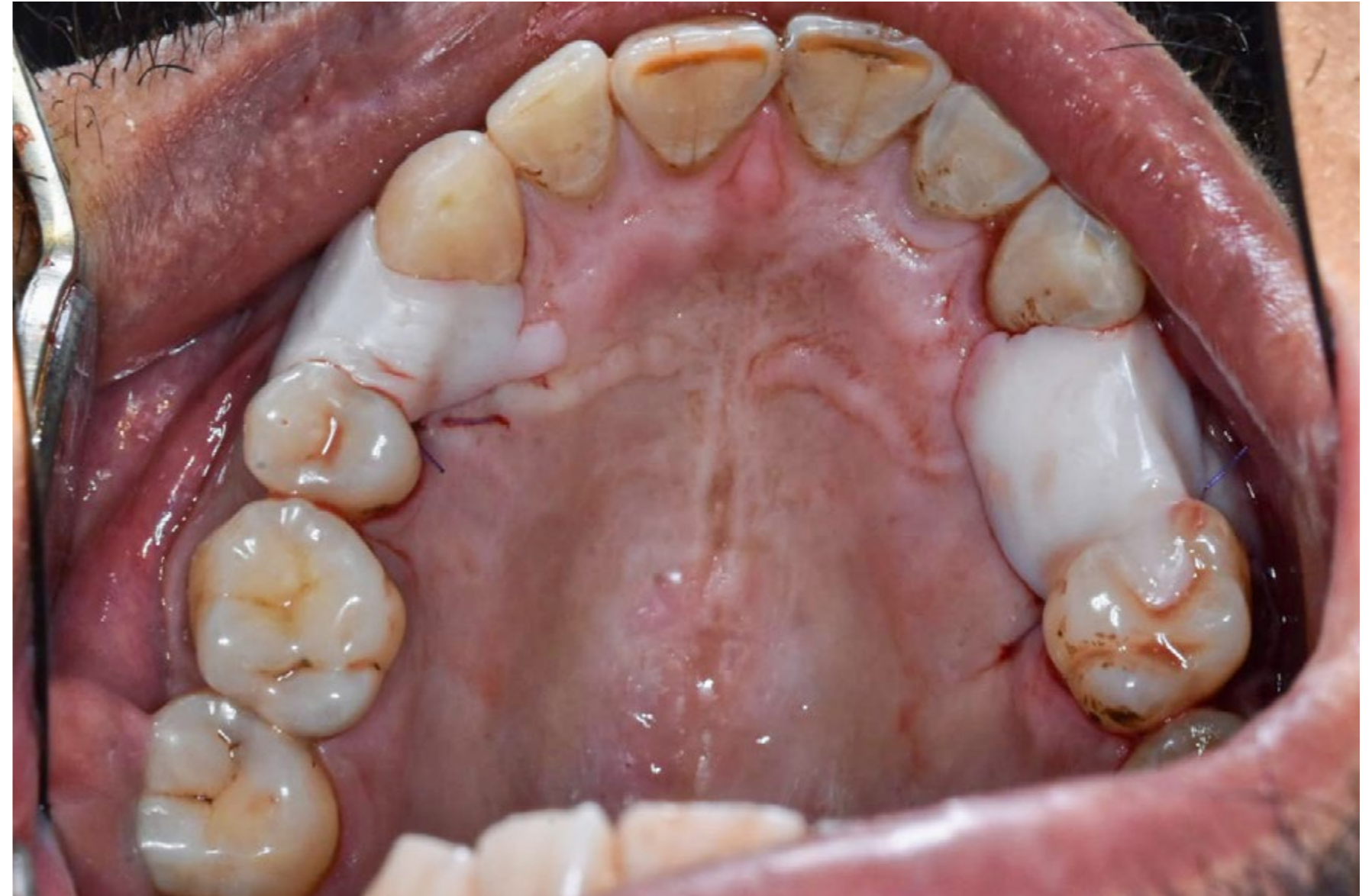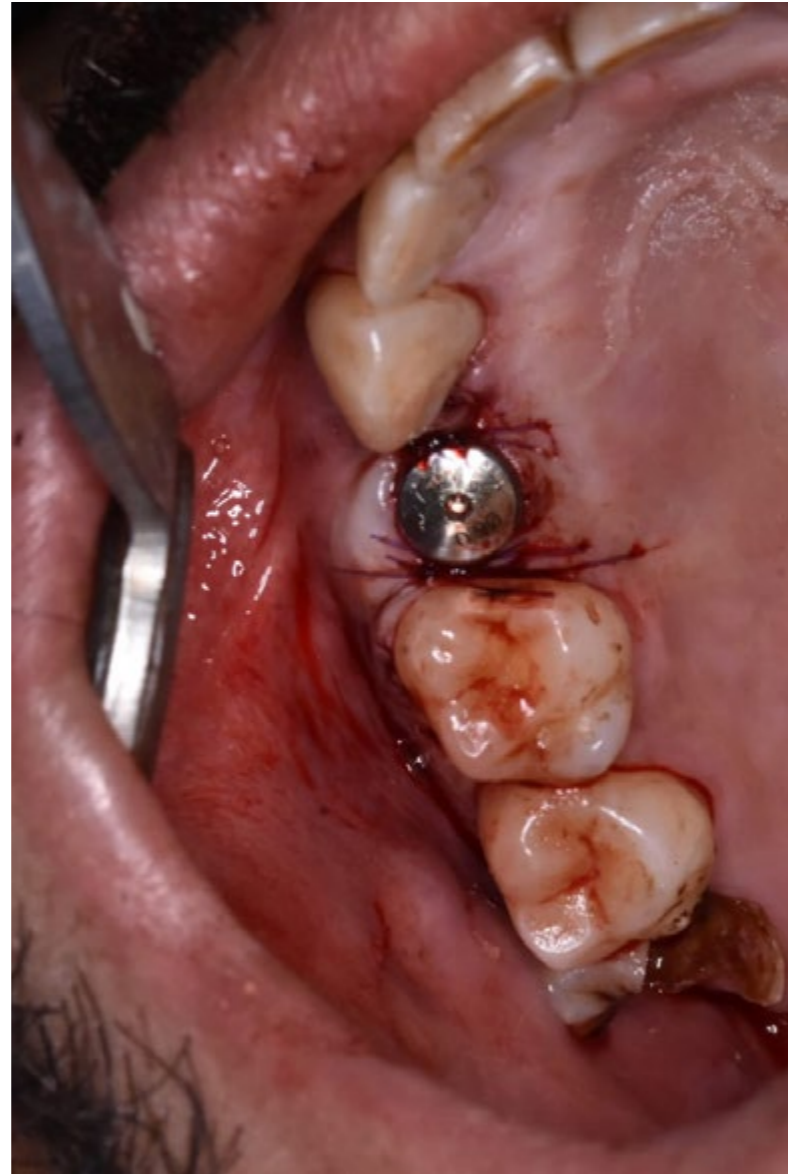
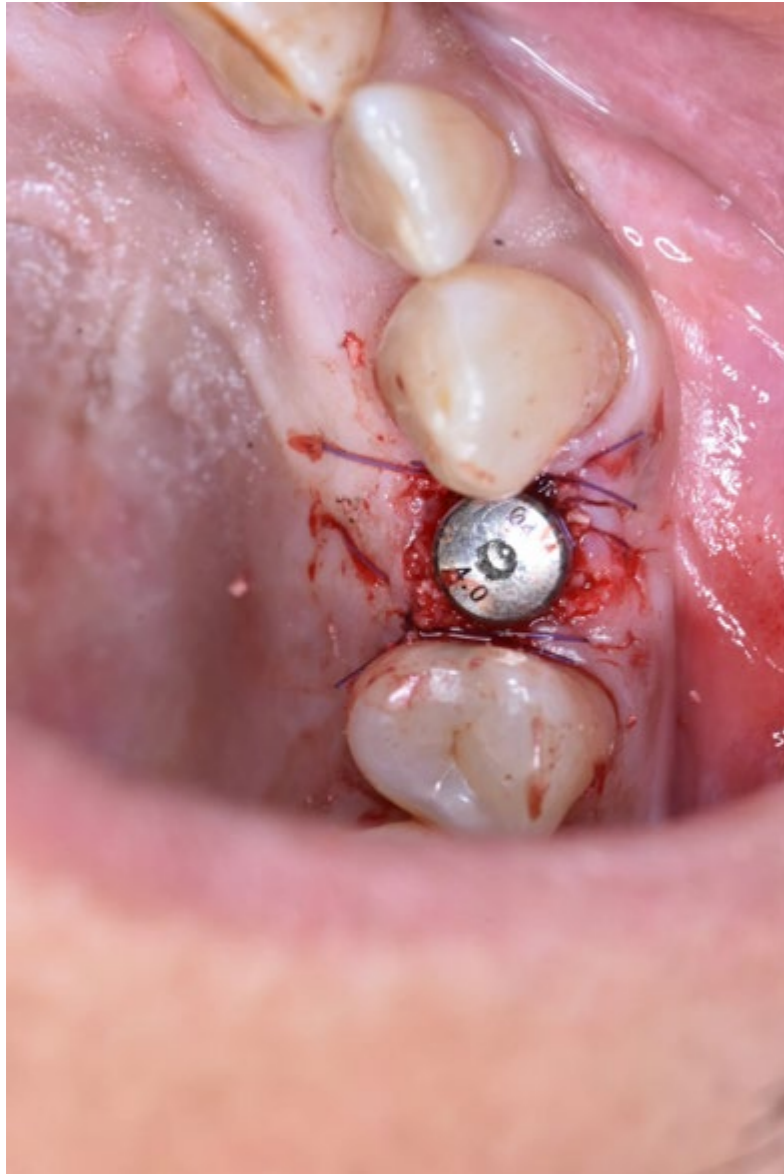


Day of surgery

1 week post-operative

Application

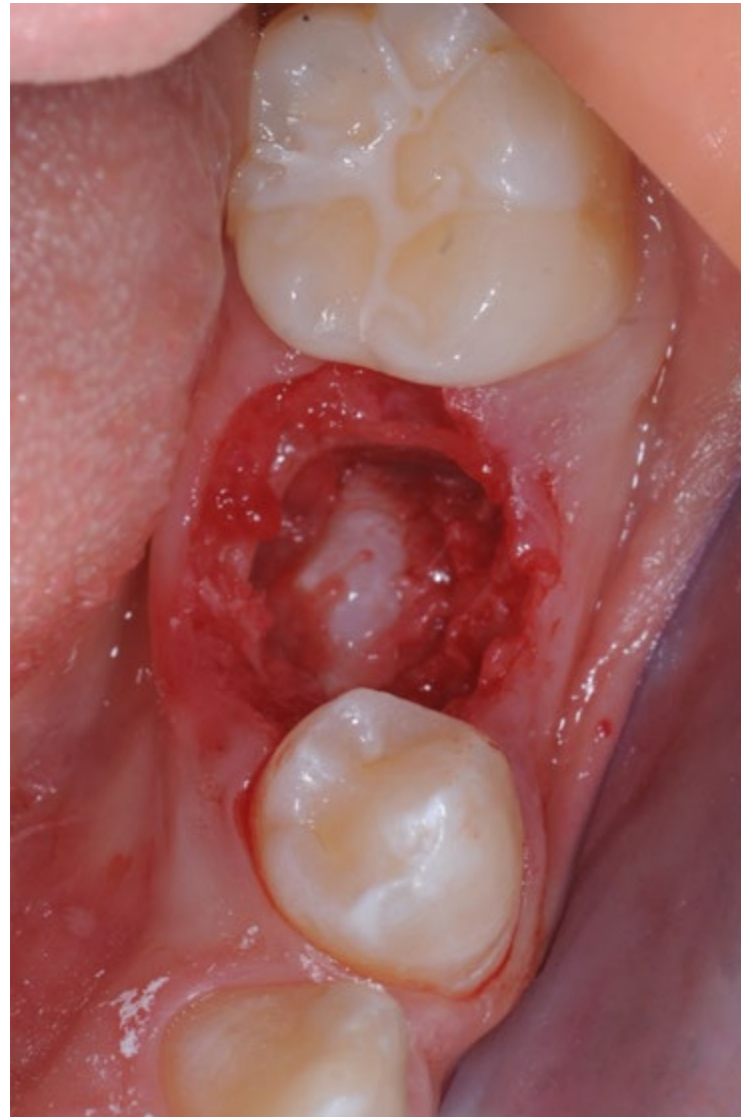
Antibacterial coverage of implant sites



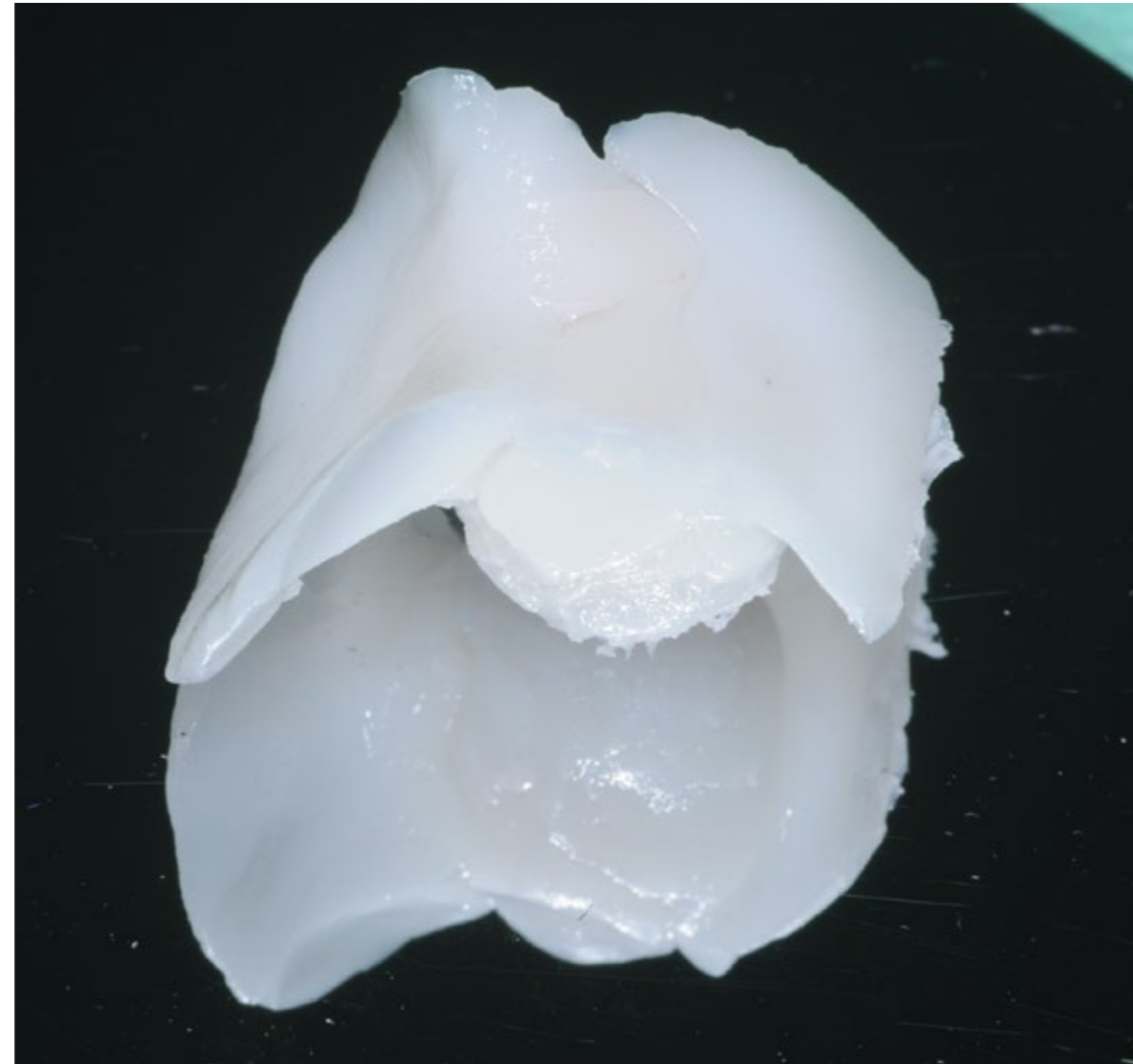


Application

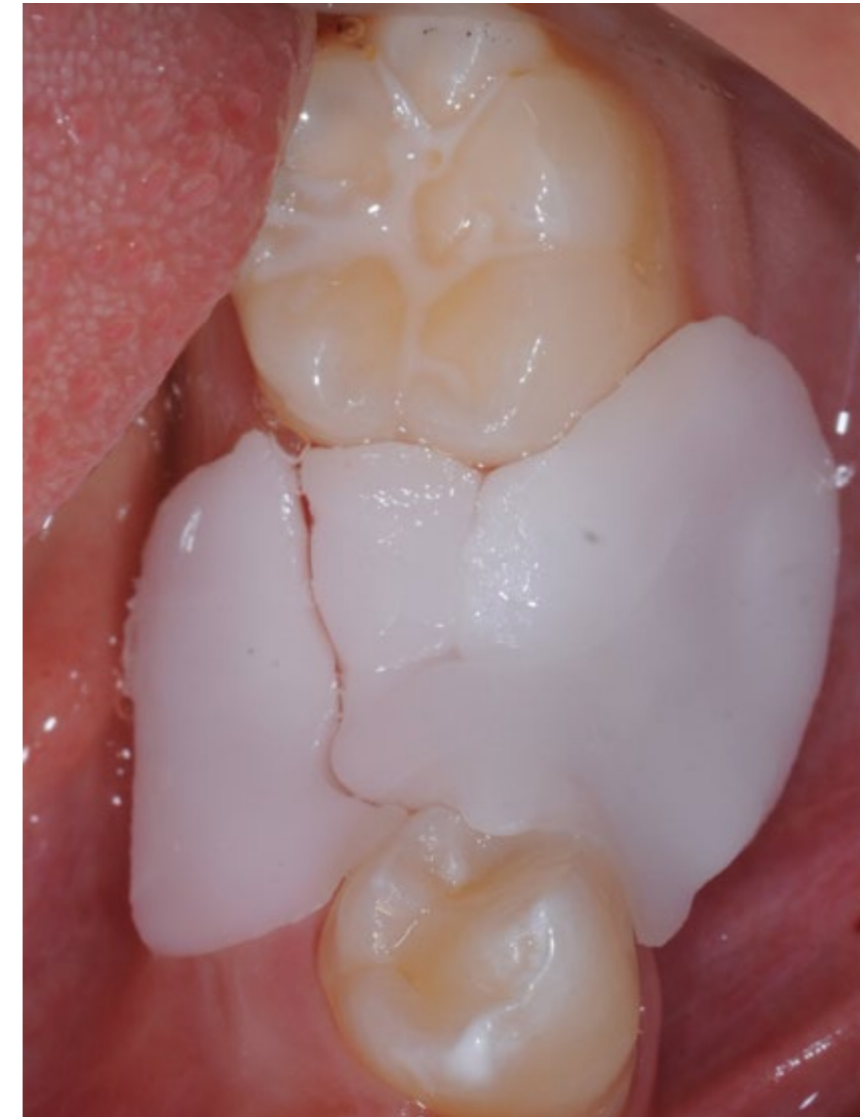Sealing of the extraction socket



1. Extraction



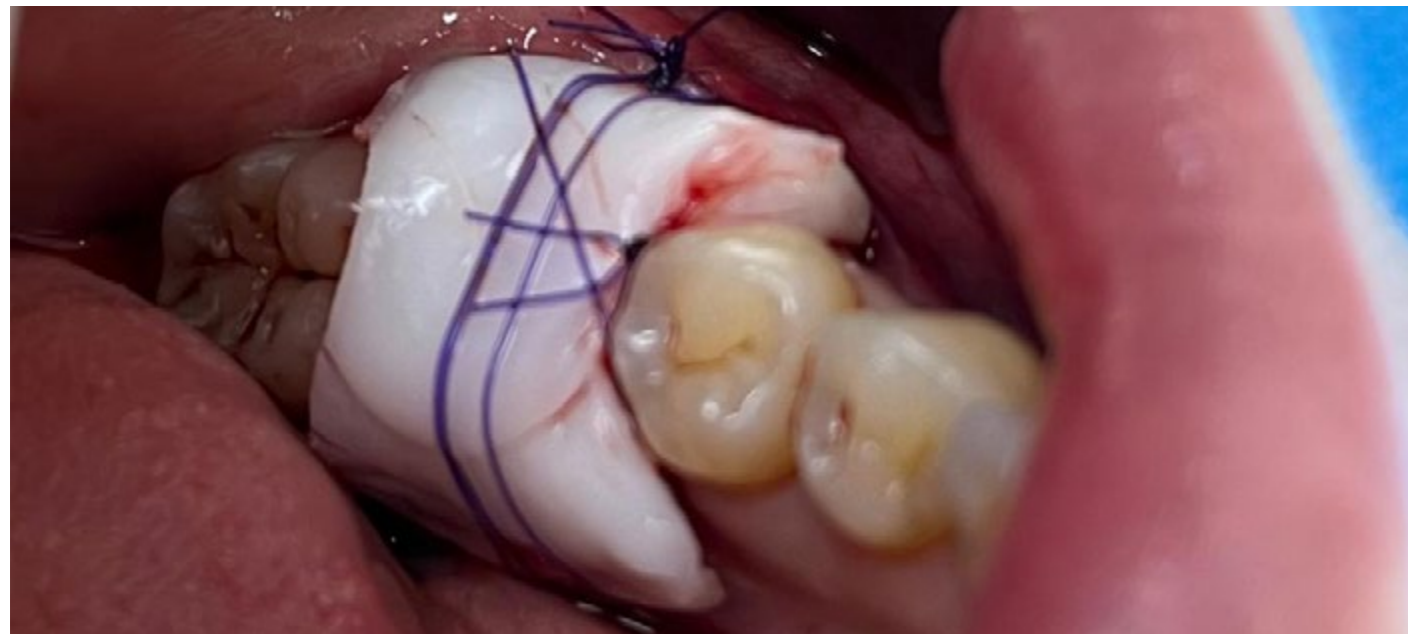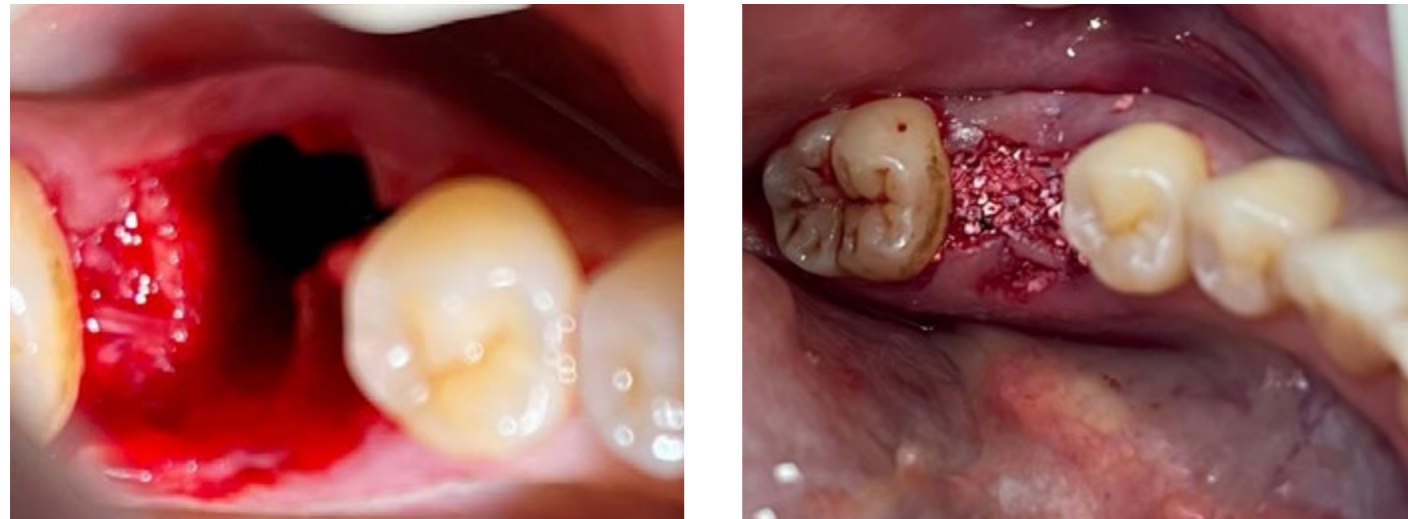
2. Creating socket seal with Elemental granulate



3. Placement of socket seal to protect extraction socket

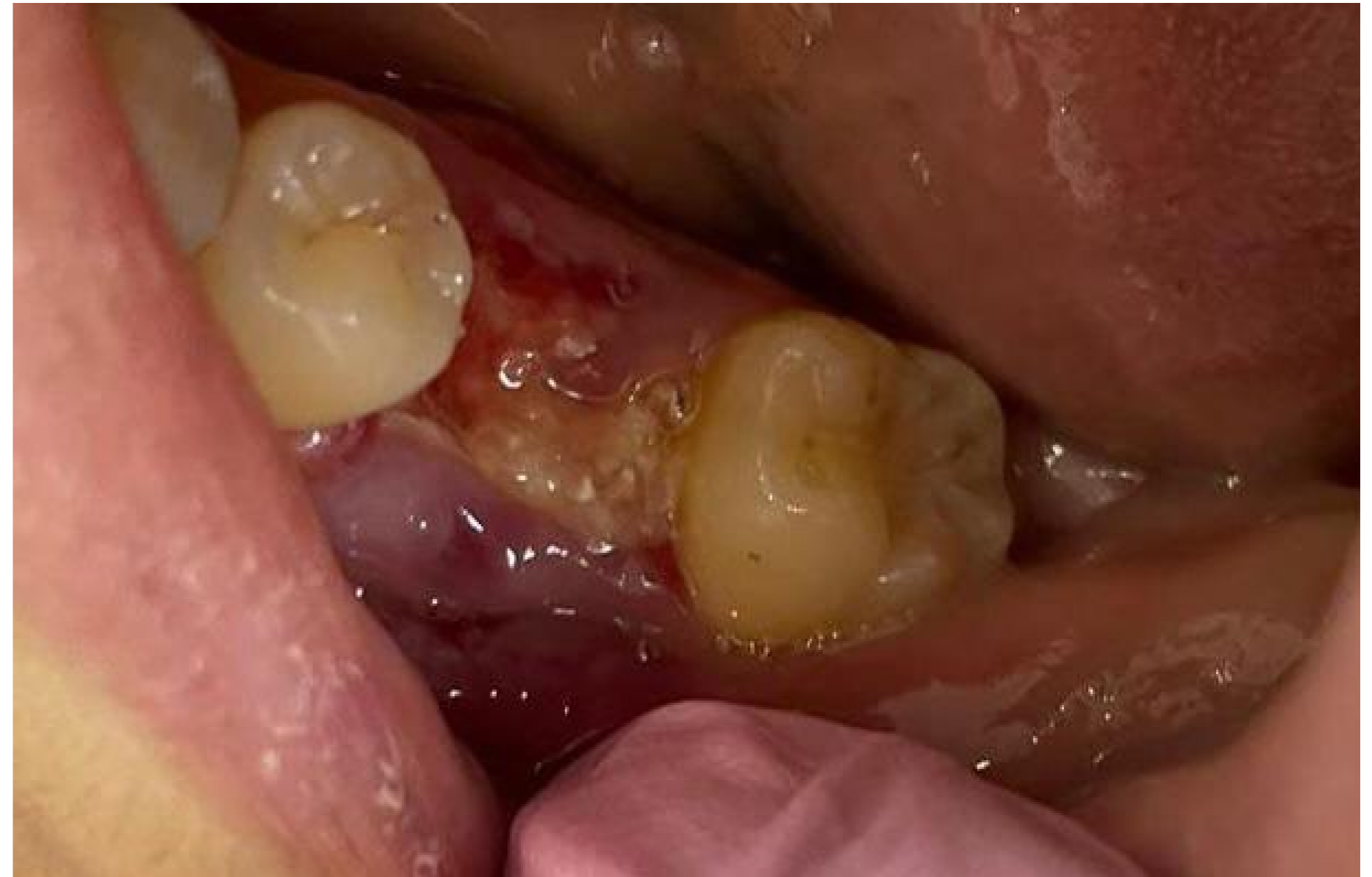Application

Sealing of the extraction socket after bone grafting



Day of surgery

1. extraction, 2. grafting the extraction socket, 3. sealing the socket with Elemental granulate.



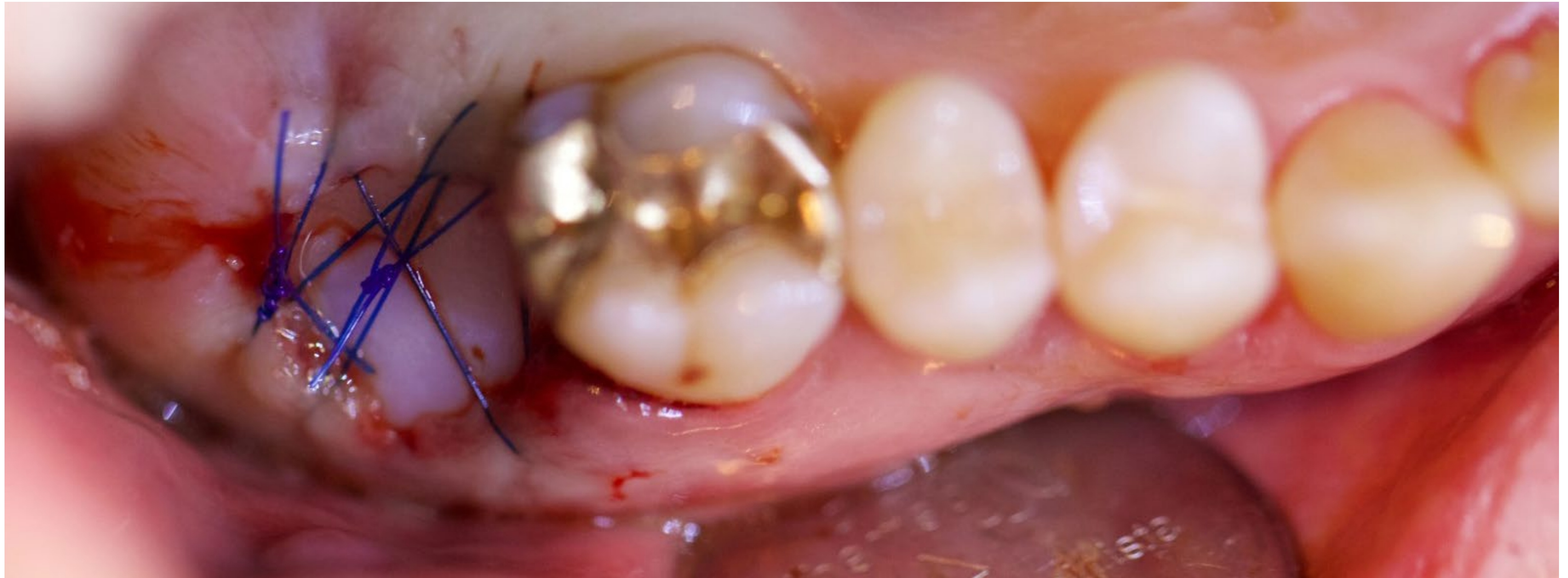7 days post-operative

Grafted socket covered by newly-formed connective tissue.



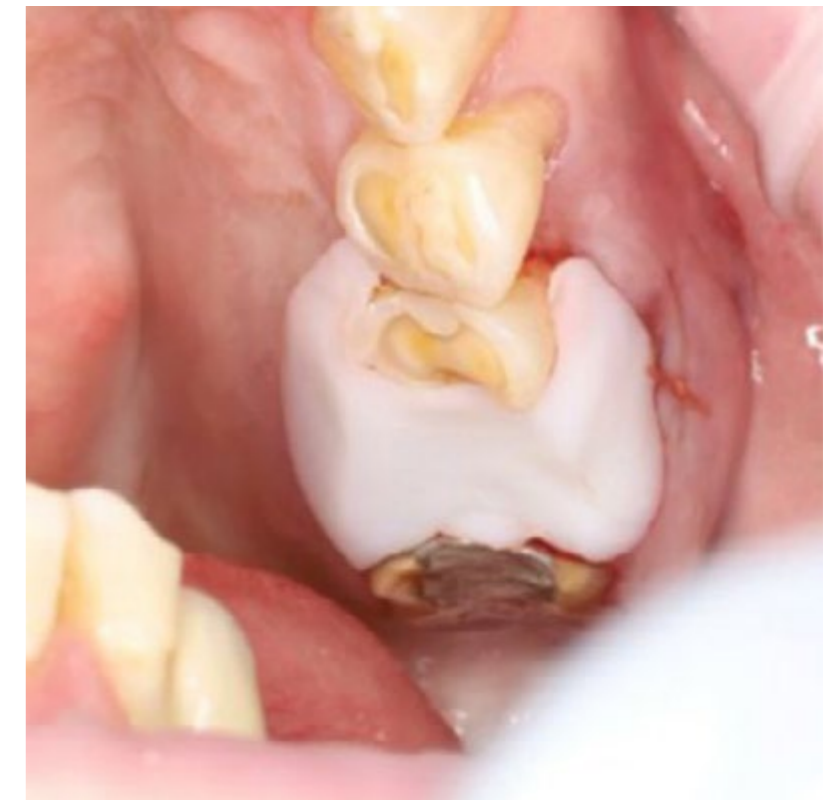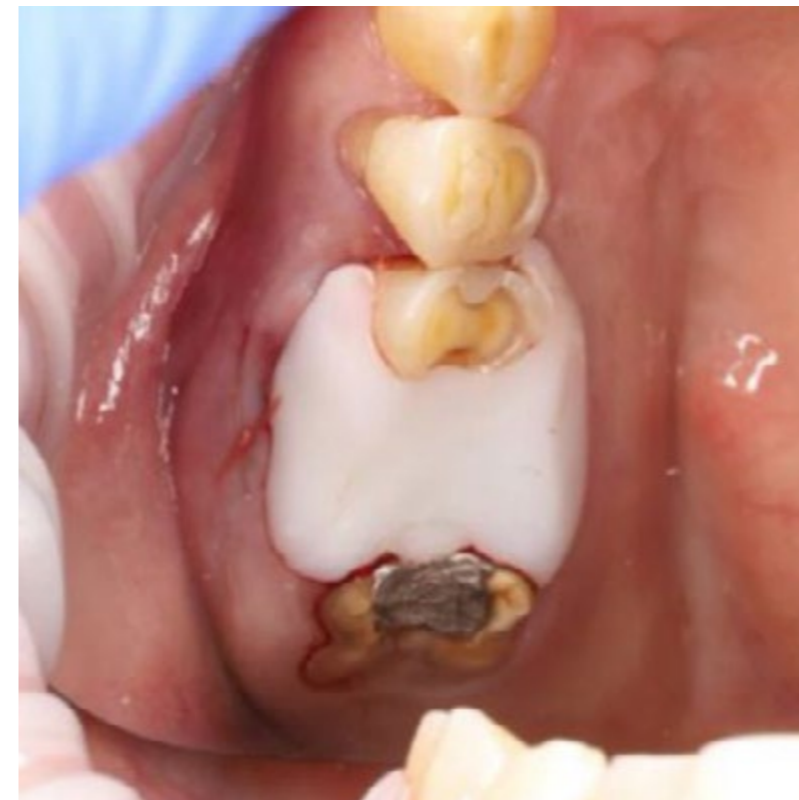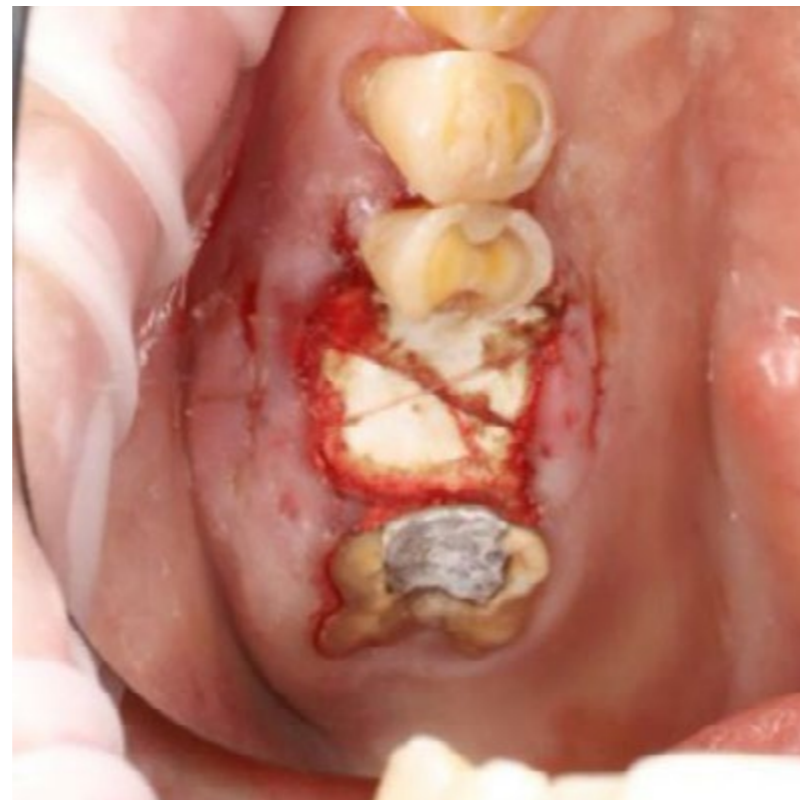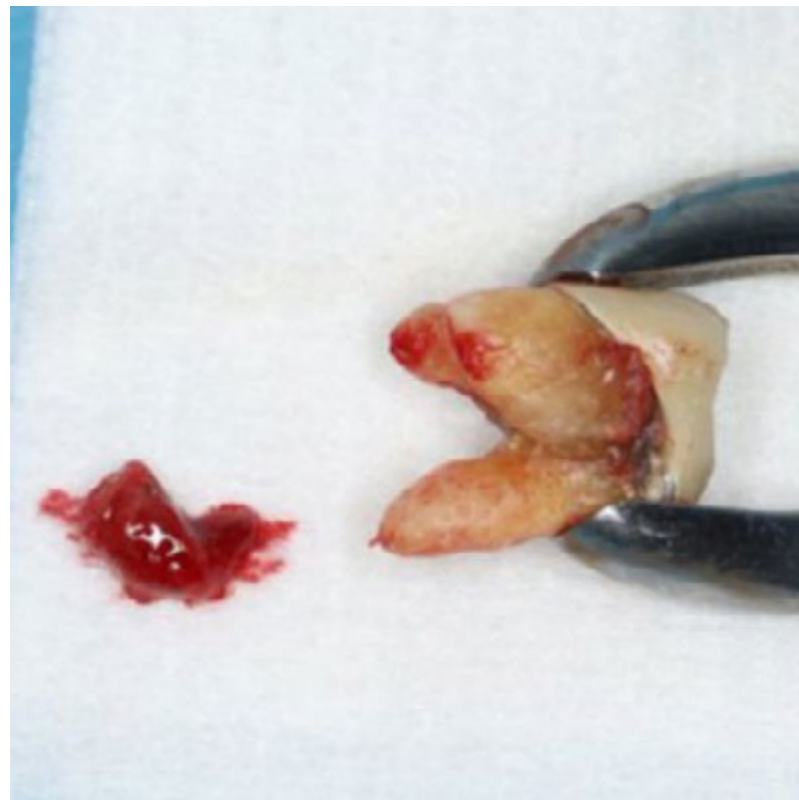
Application

Sealing of the extraction socket



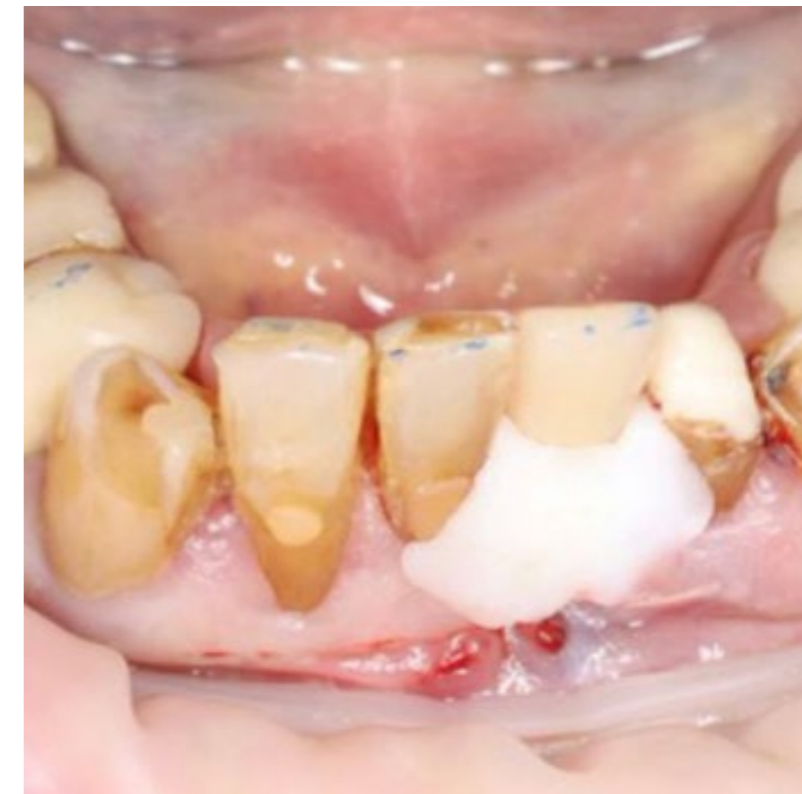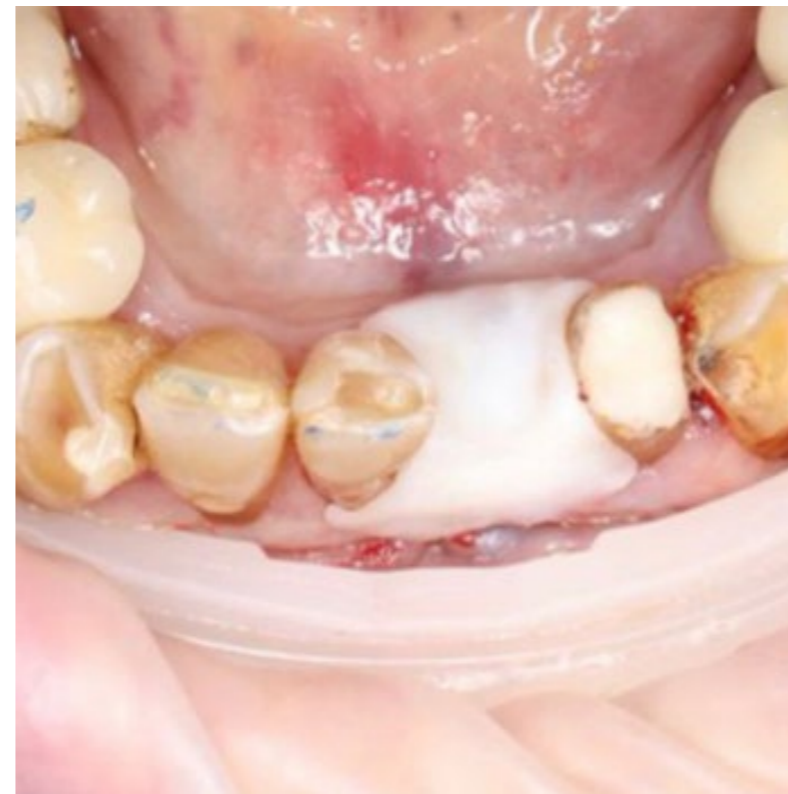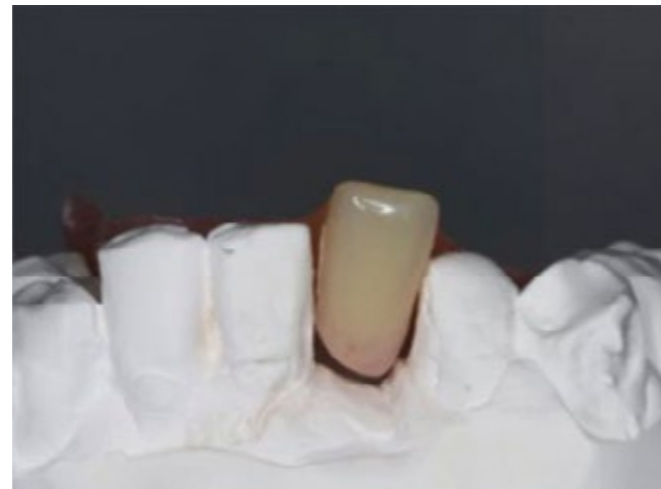
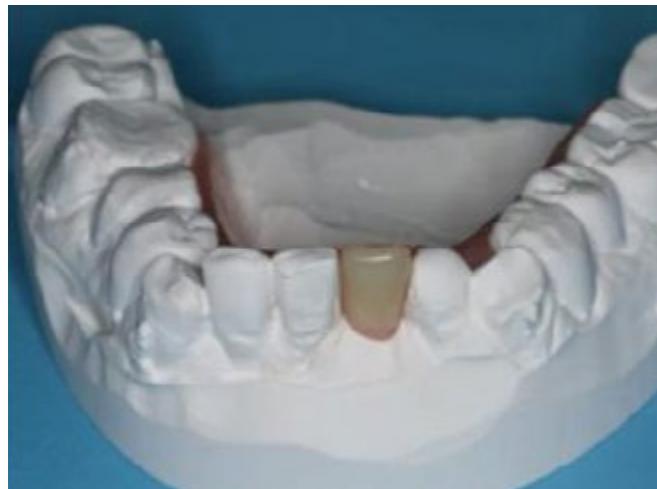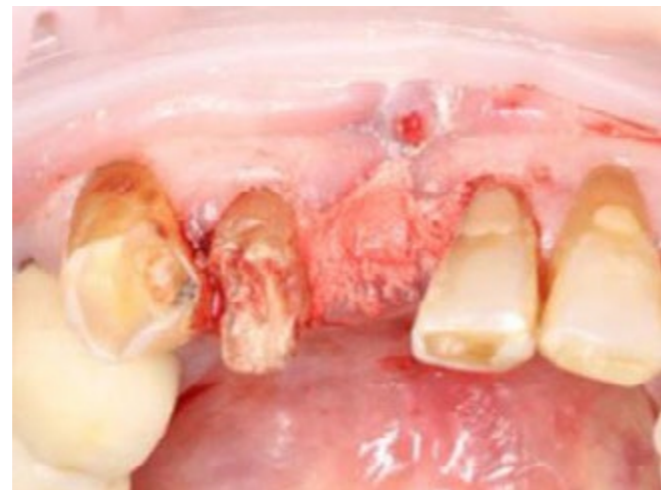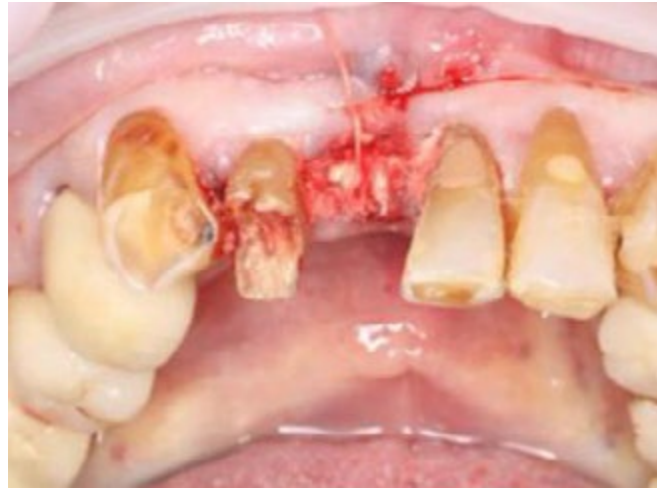Application

Sealing of the extraction socket after bone grafting



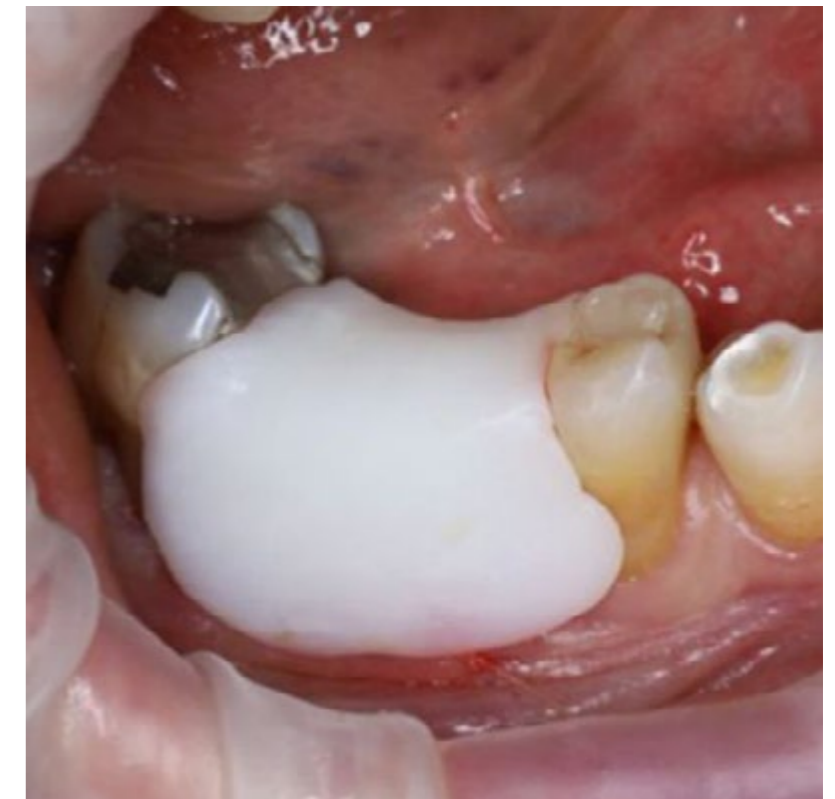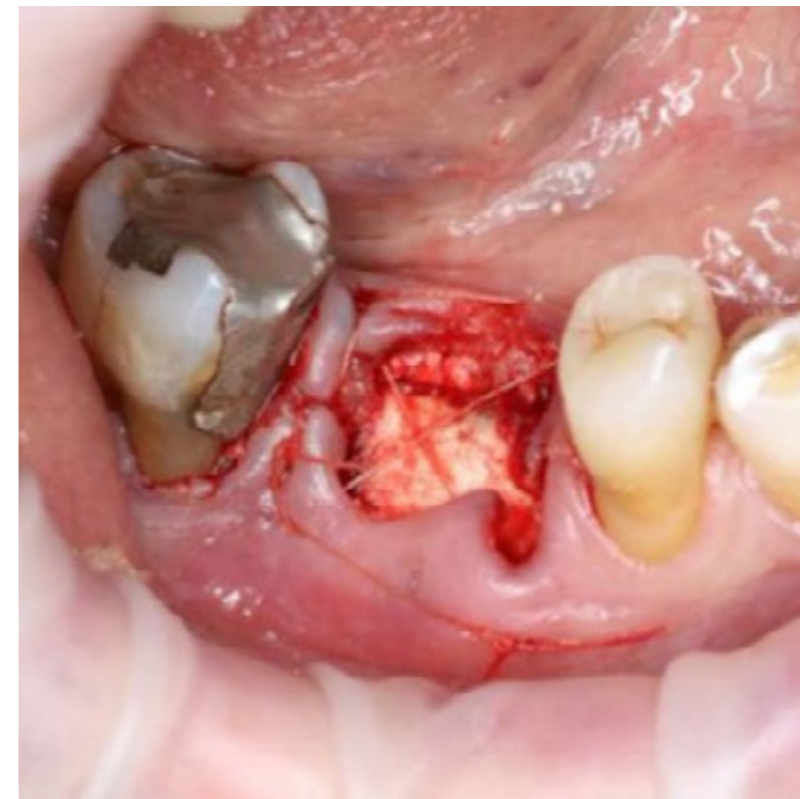
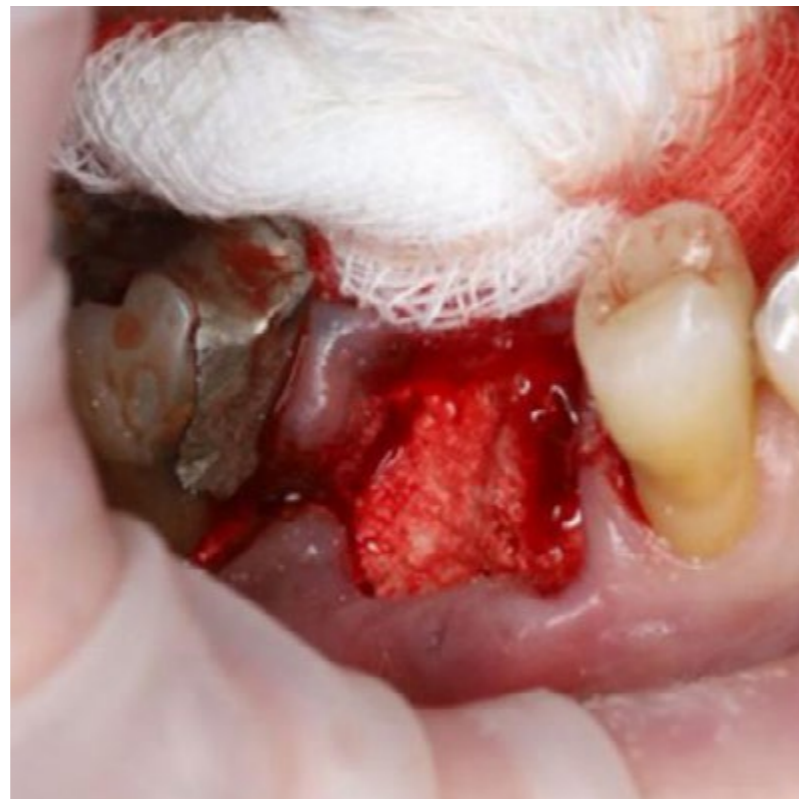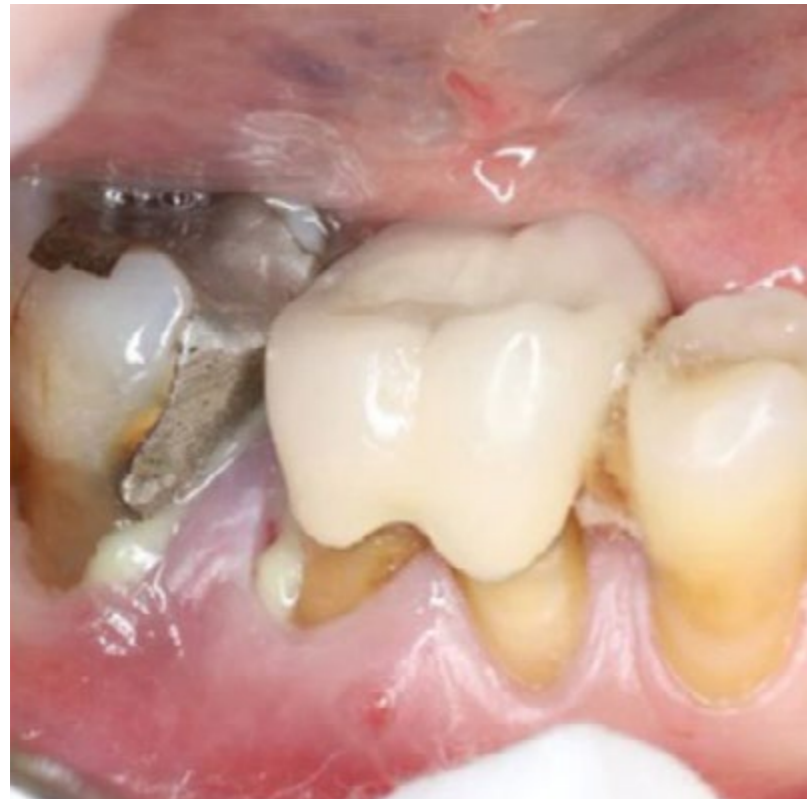Application

Sealing of the extraction socket



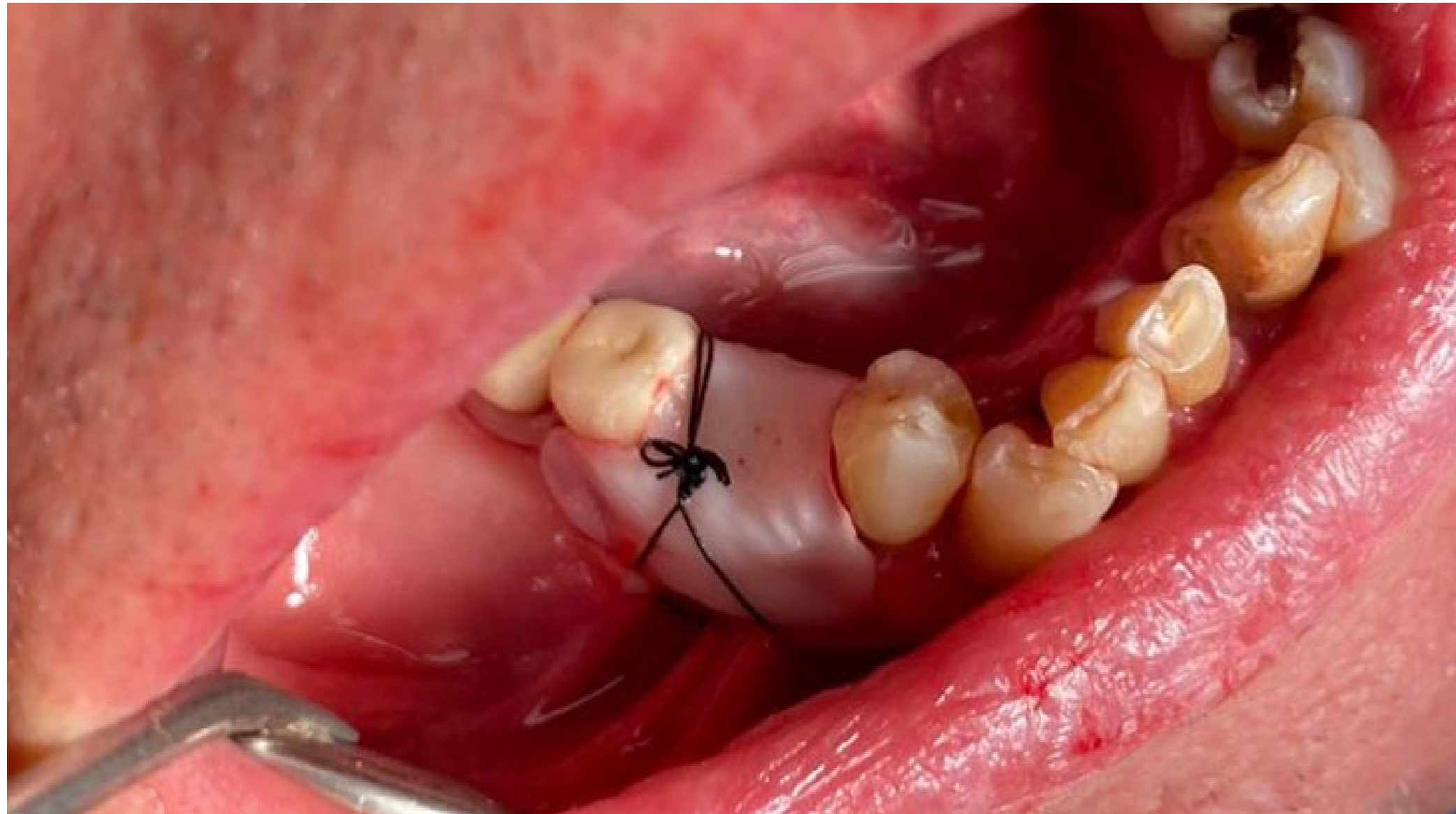
Application

Sealing of the extraction socket



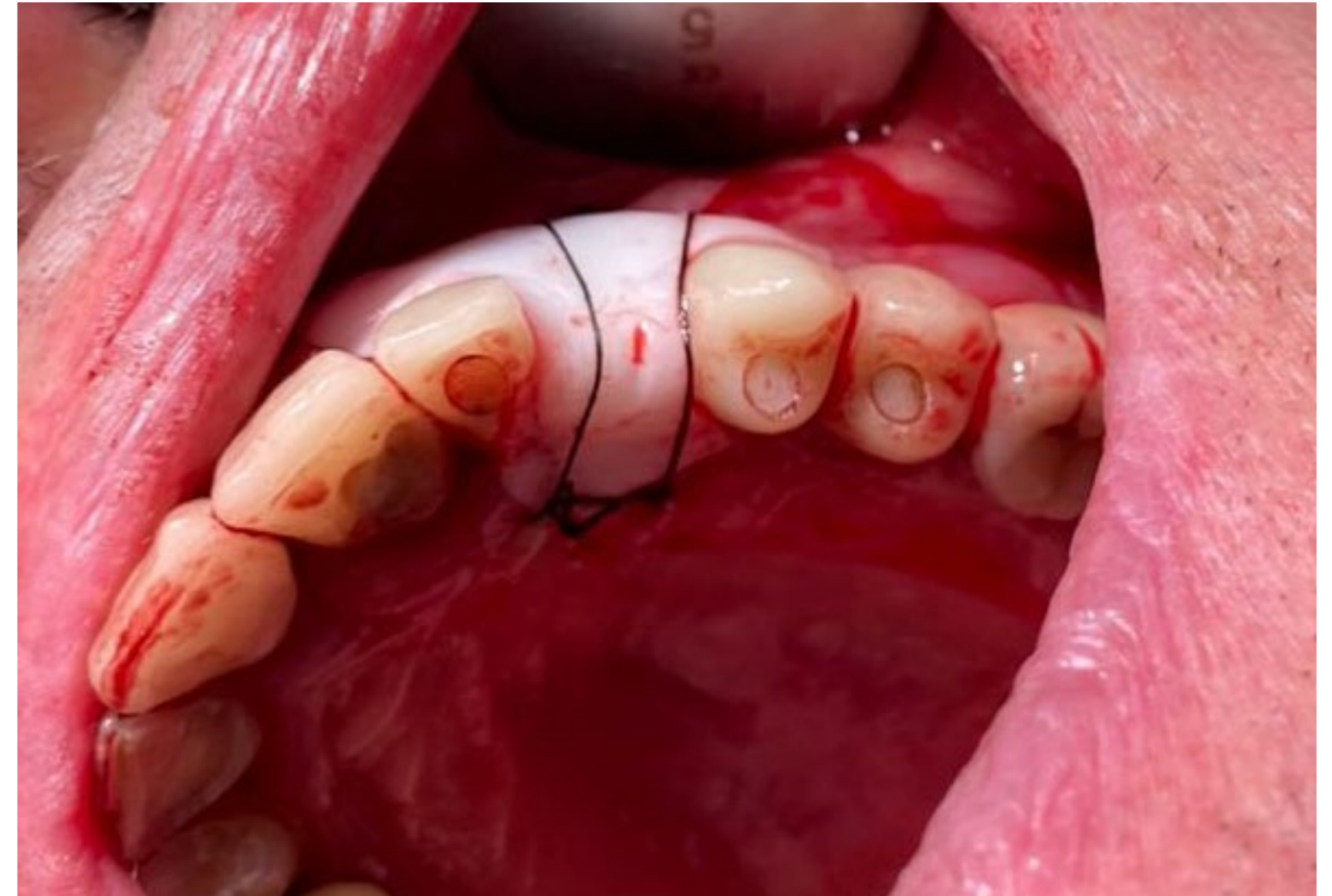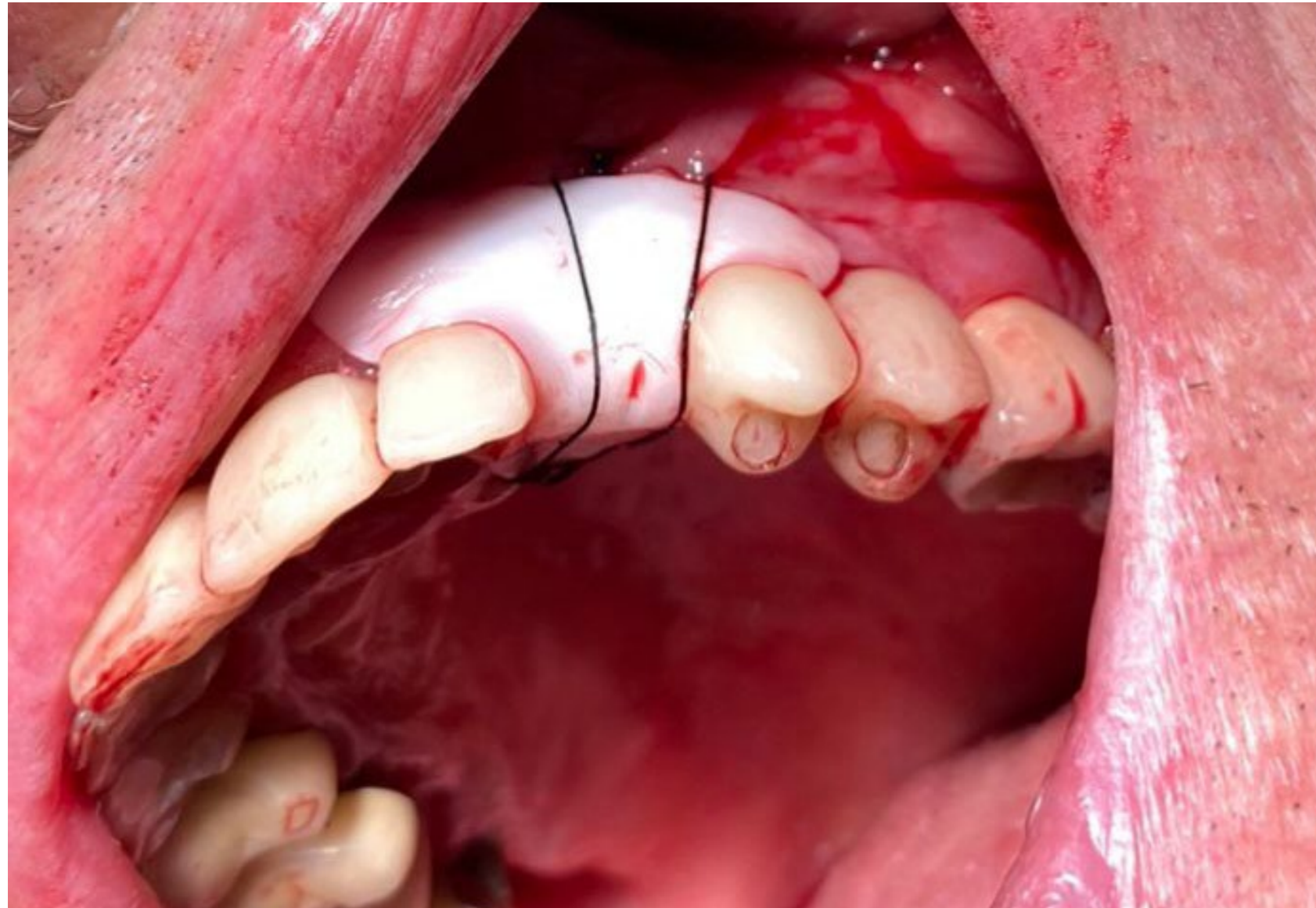
Application

Sealing of the extraction socket



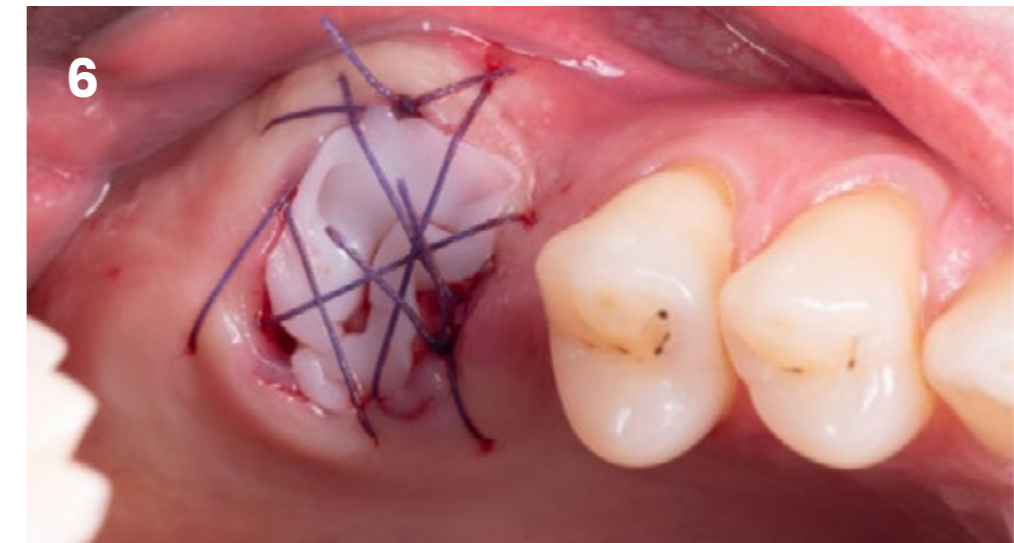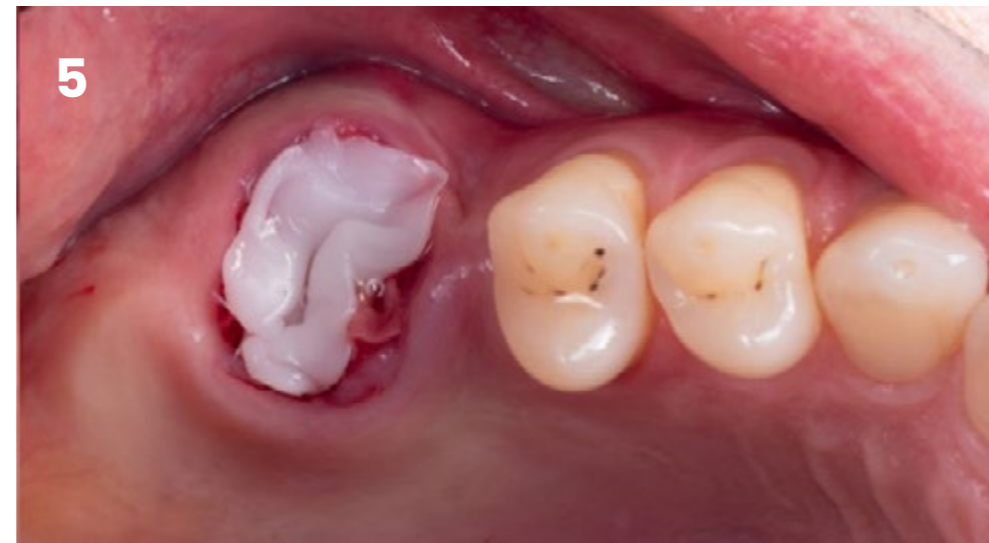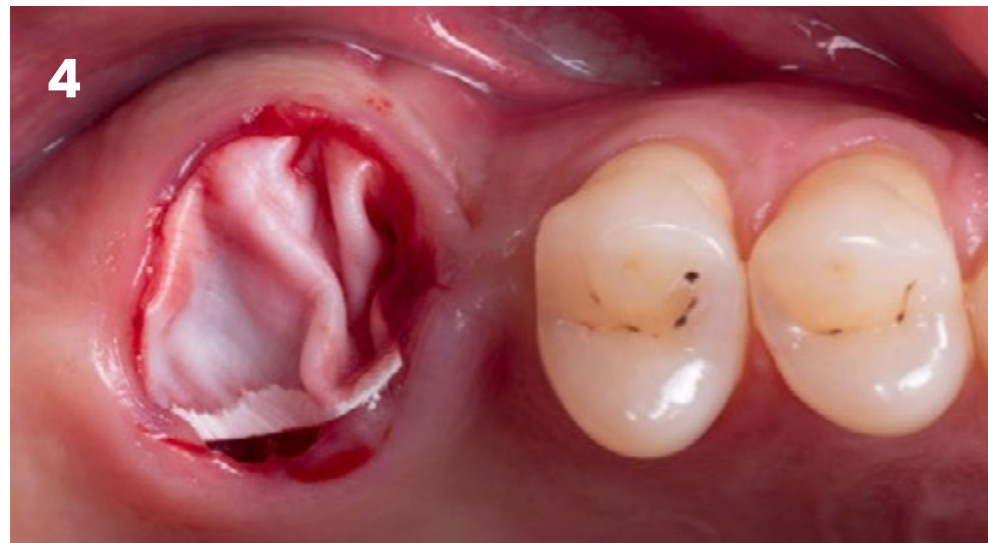
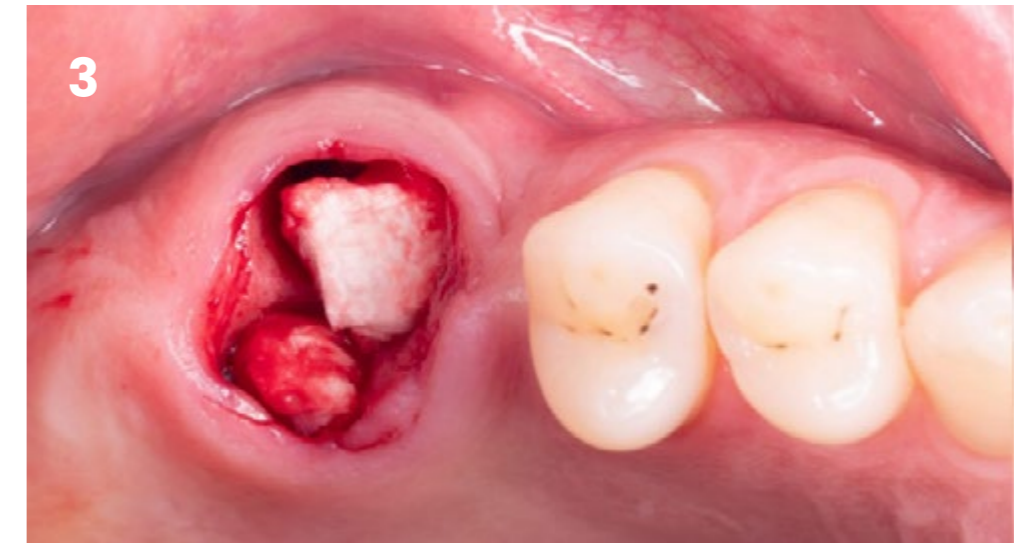
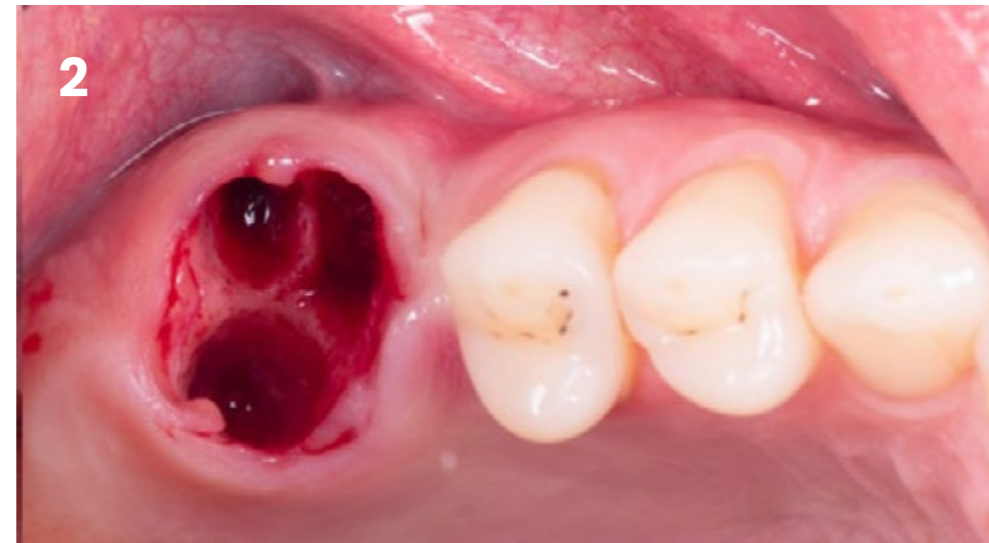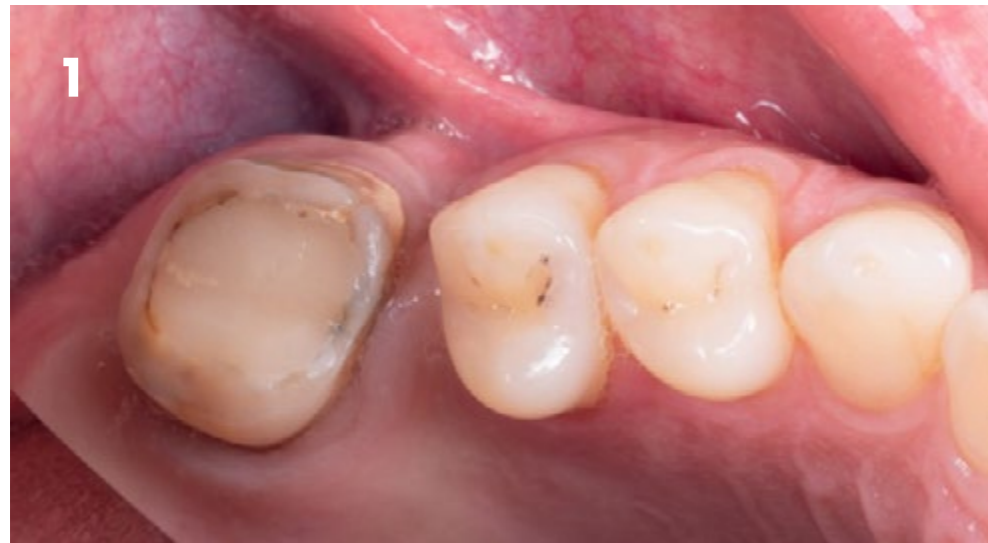Application

Sealing of the extraction socket



Application

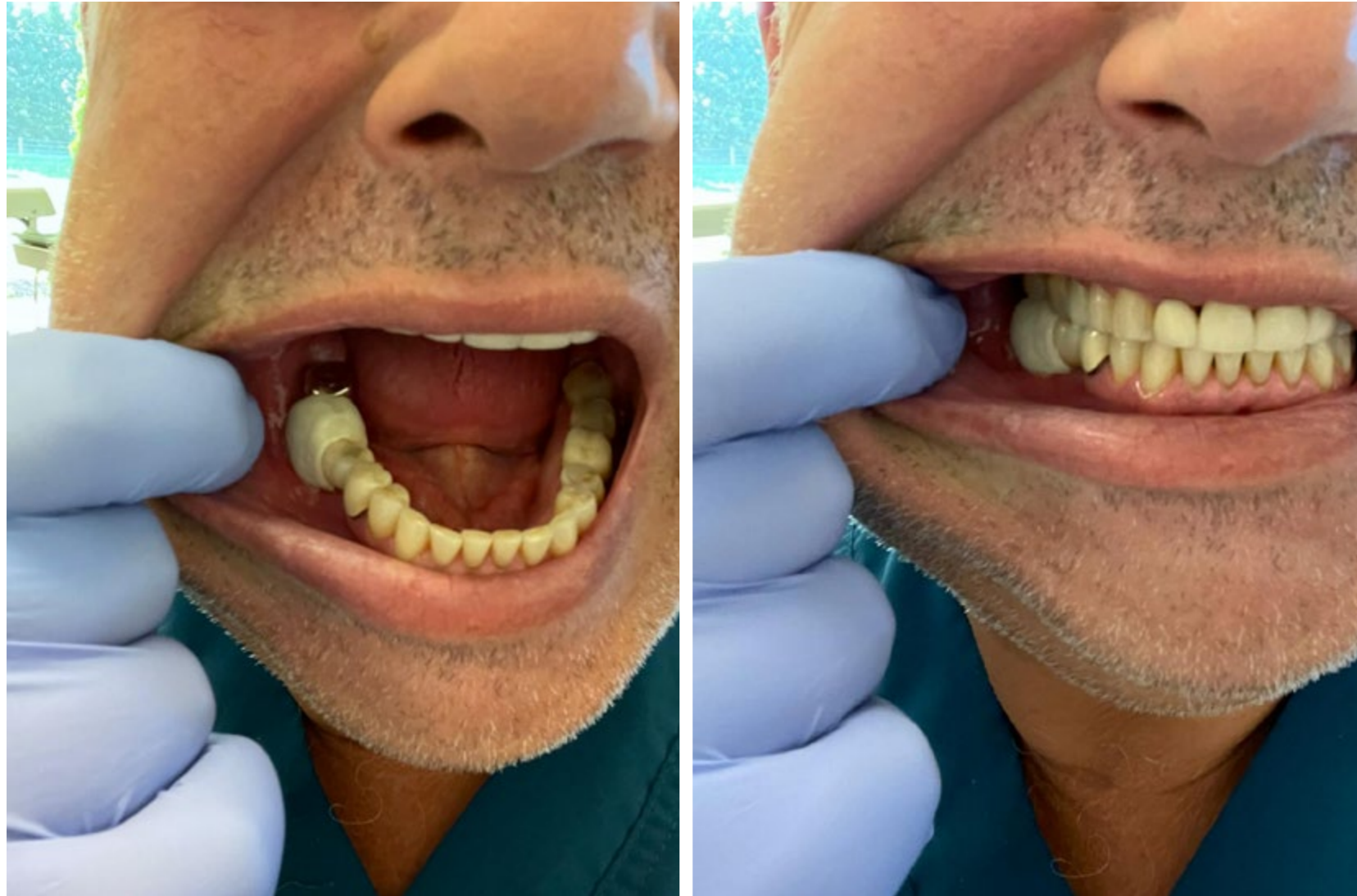Sealing of the extraction socket





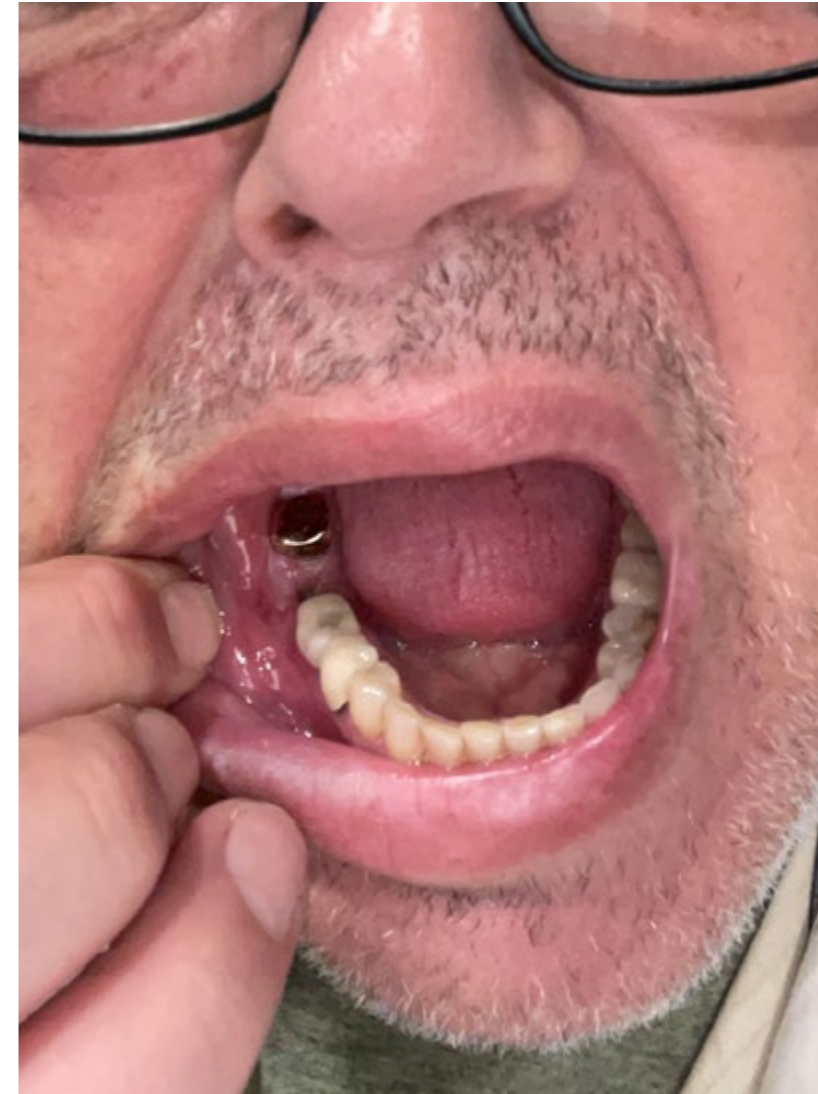Application

Sealing of the extraction socket



Day of surgery

"Yesterday I extracted my 47 (31), I curetted the site, irrigated and placed zenoss bone plug. I suture and Elemental granulate. I feel great, I brushed and rinsed."

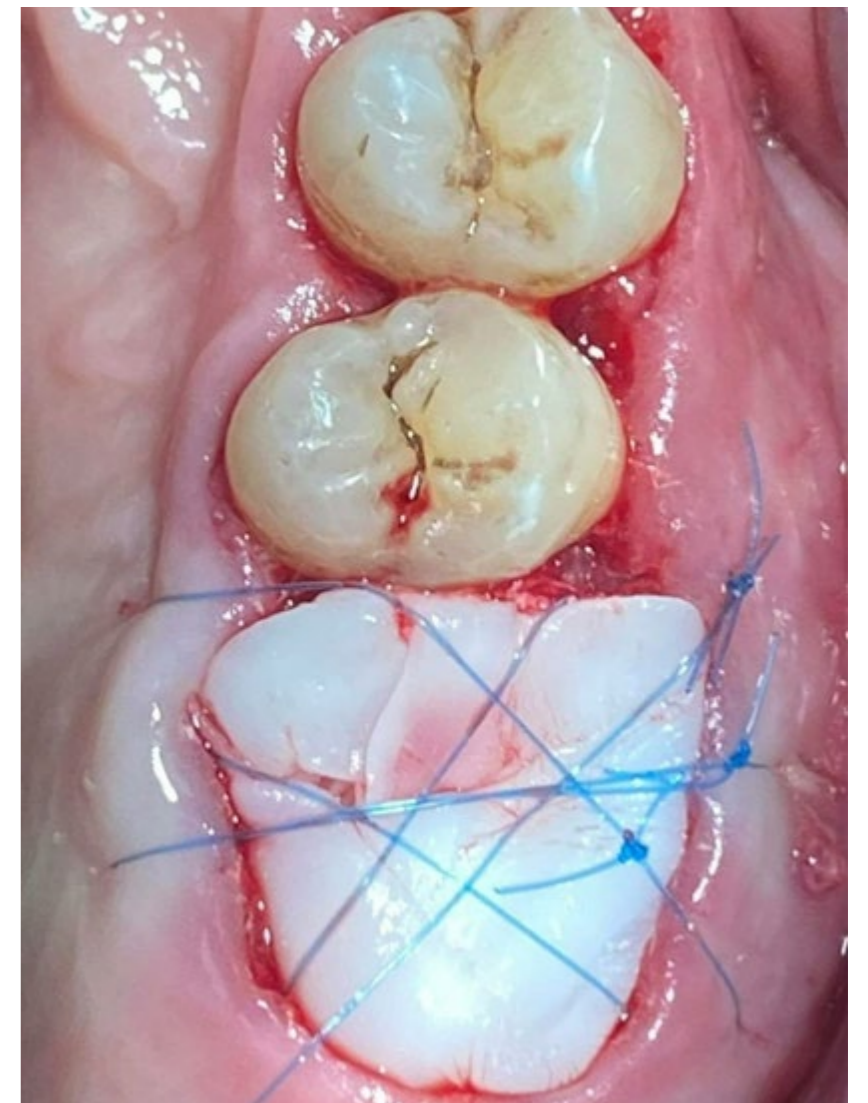
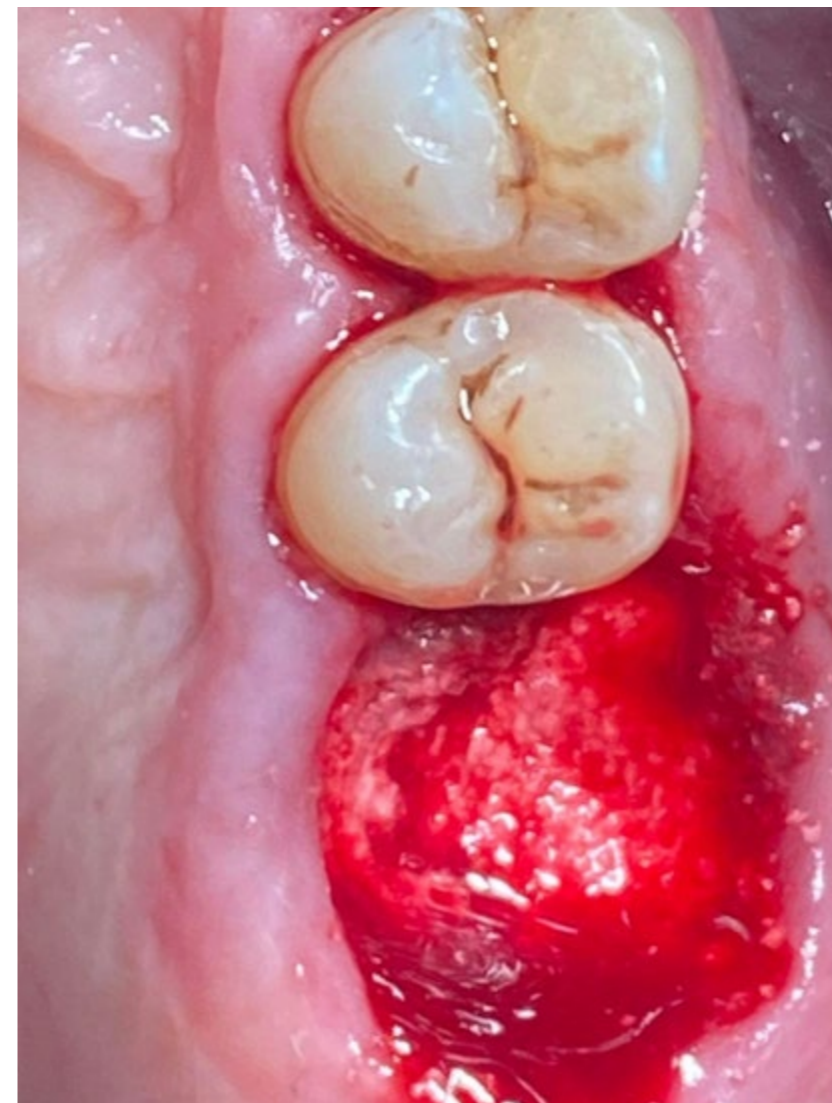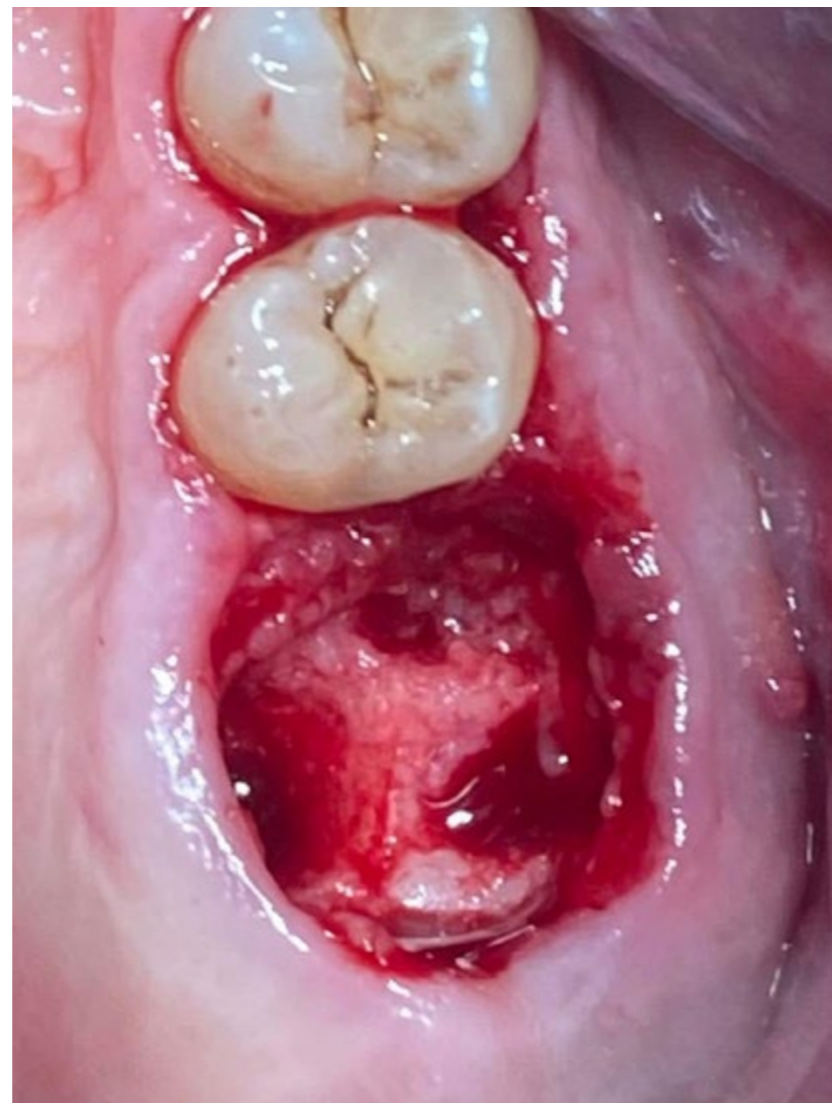

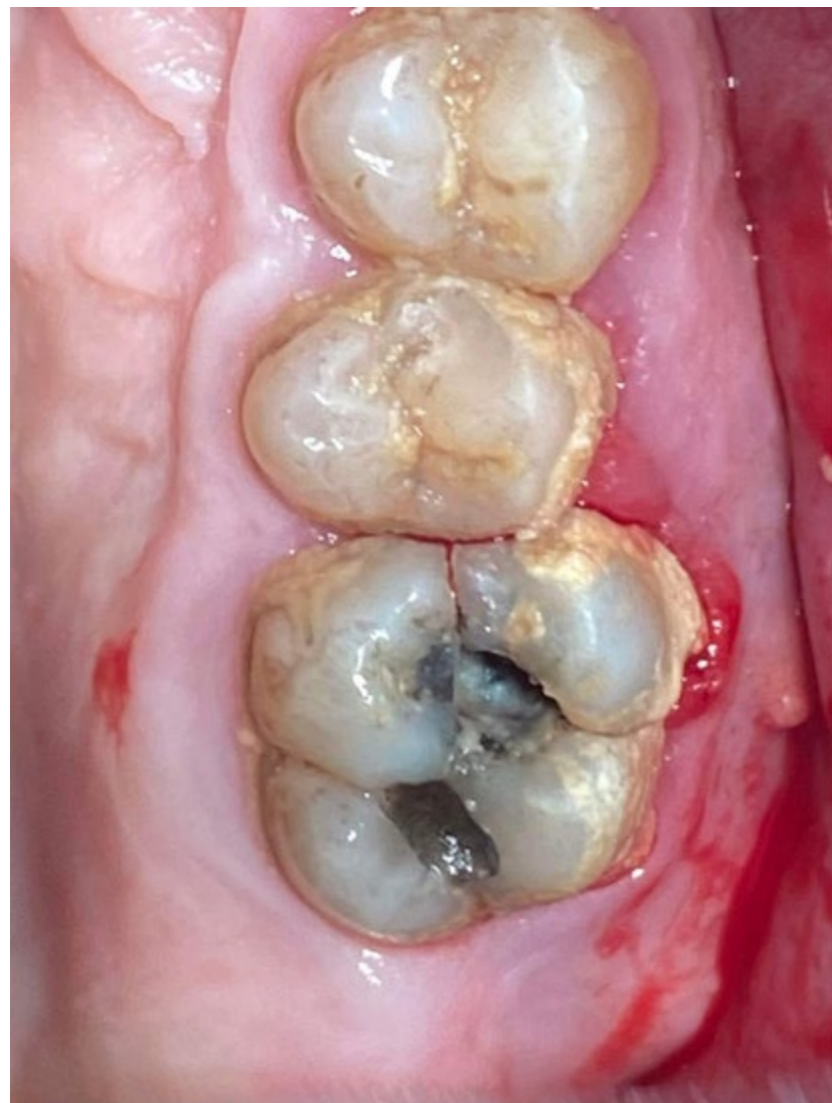
5 days post-operative

"I removed the material, the site is beautiful, I'm great, no pain."

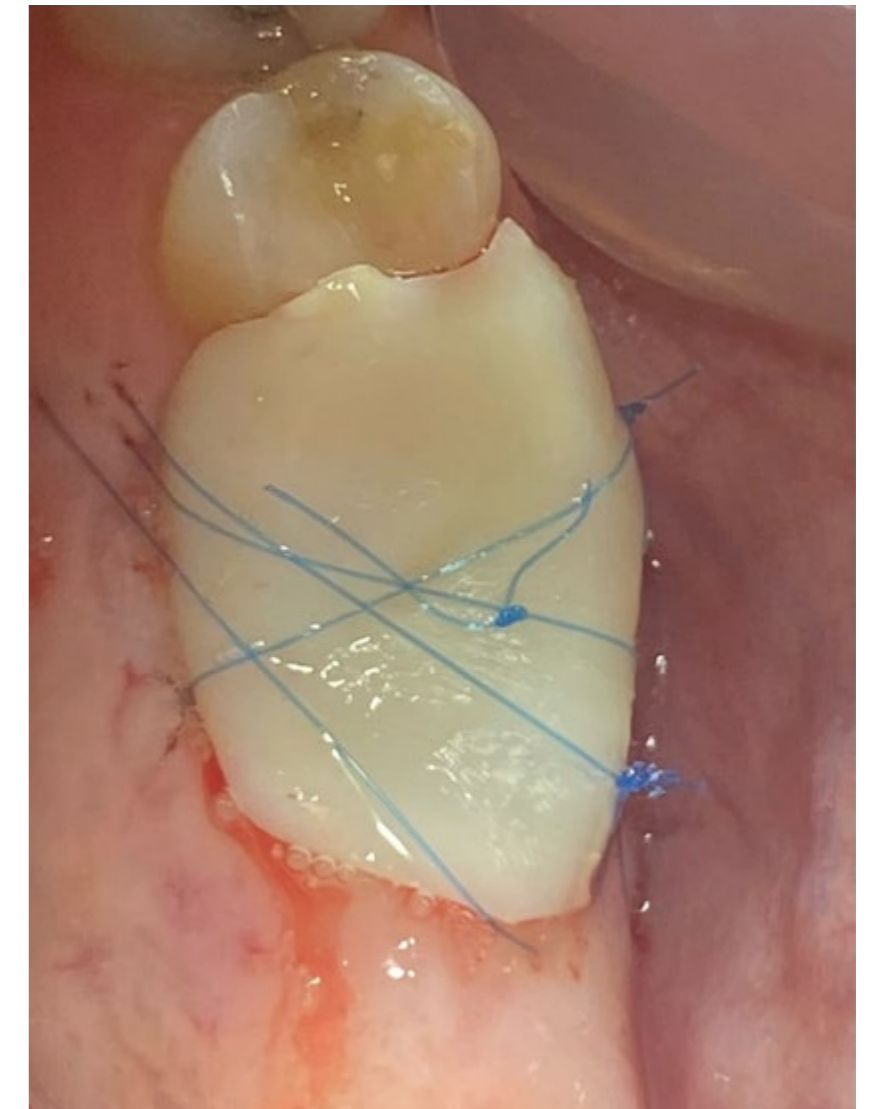
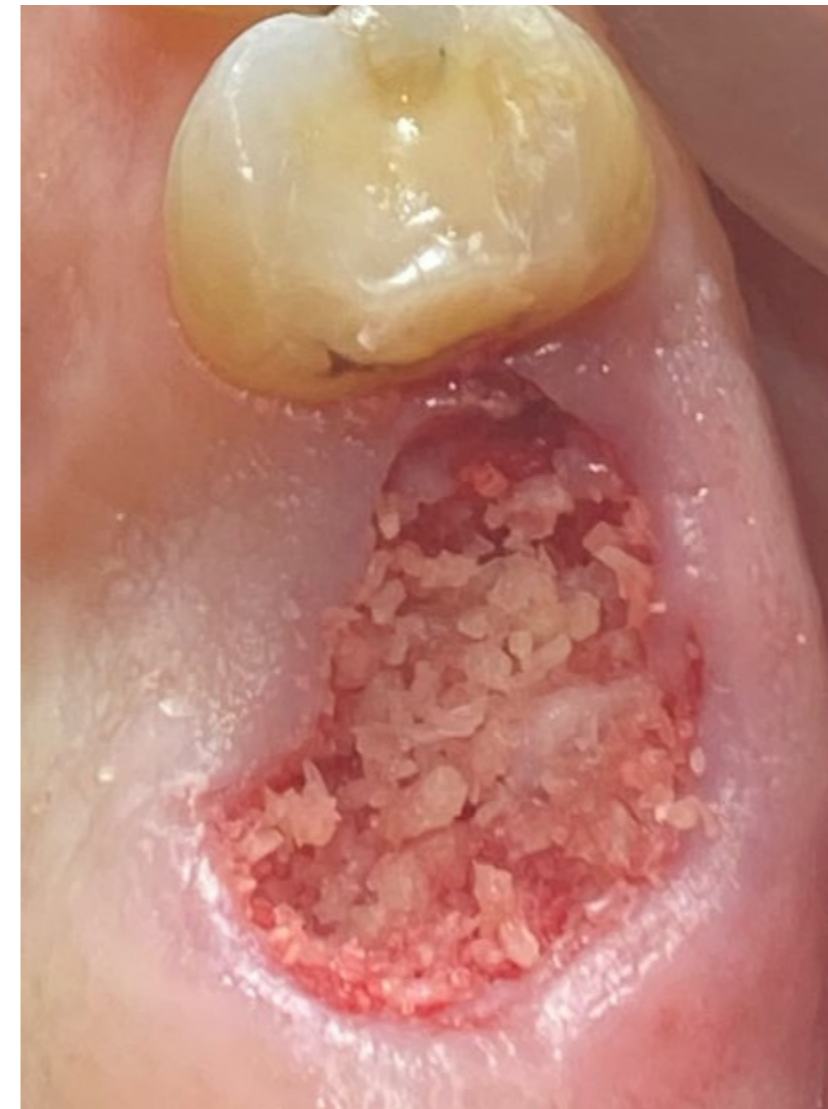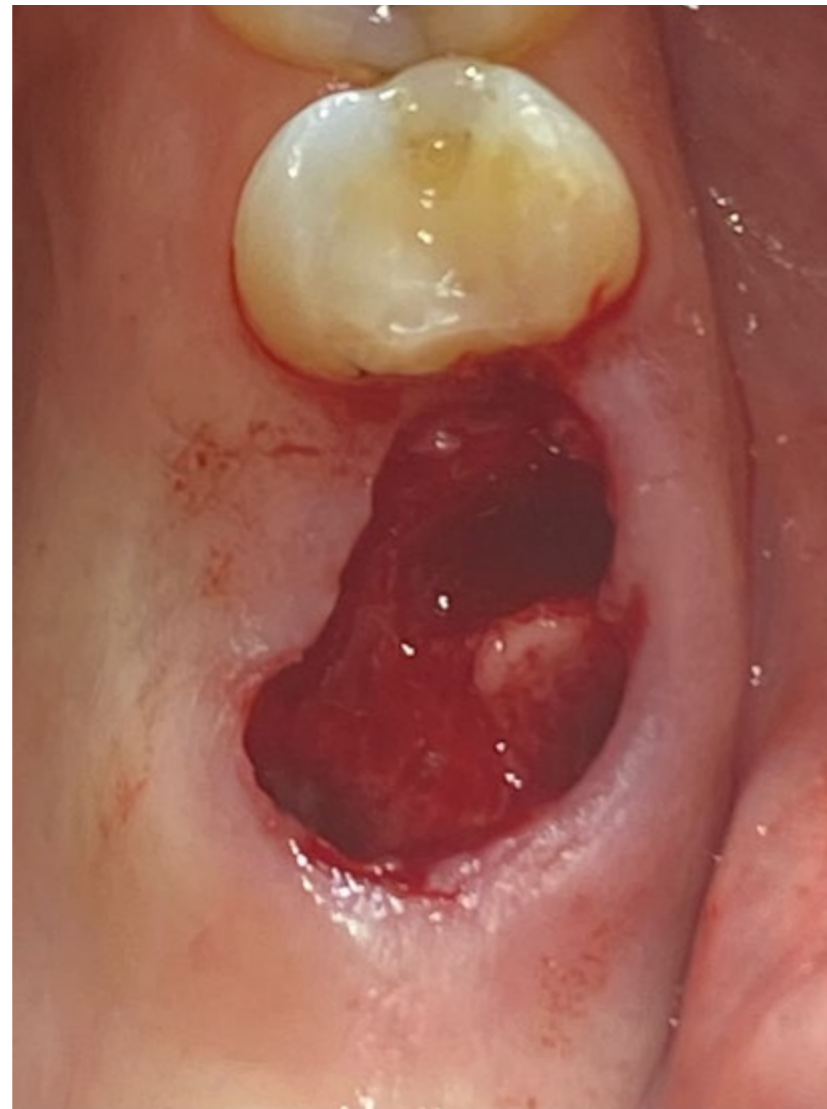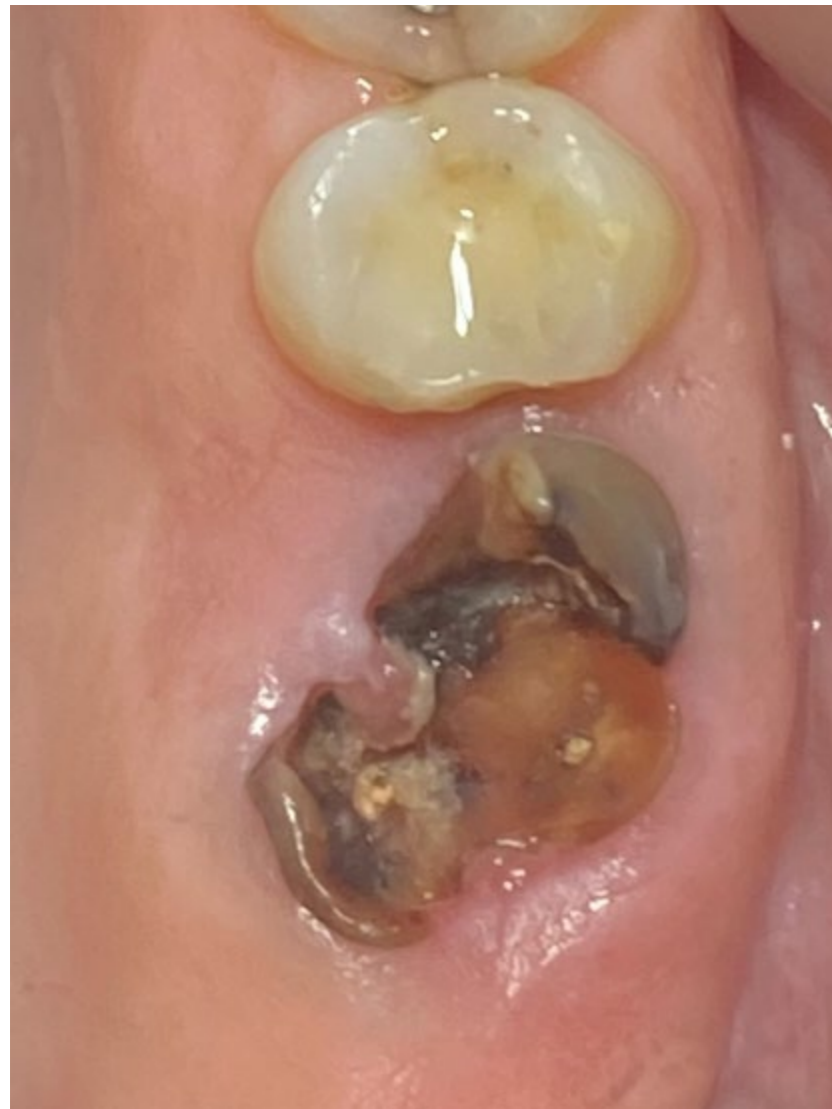Application

Sealing of the extraction socket



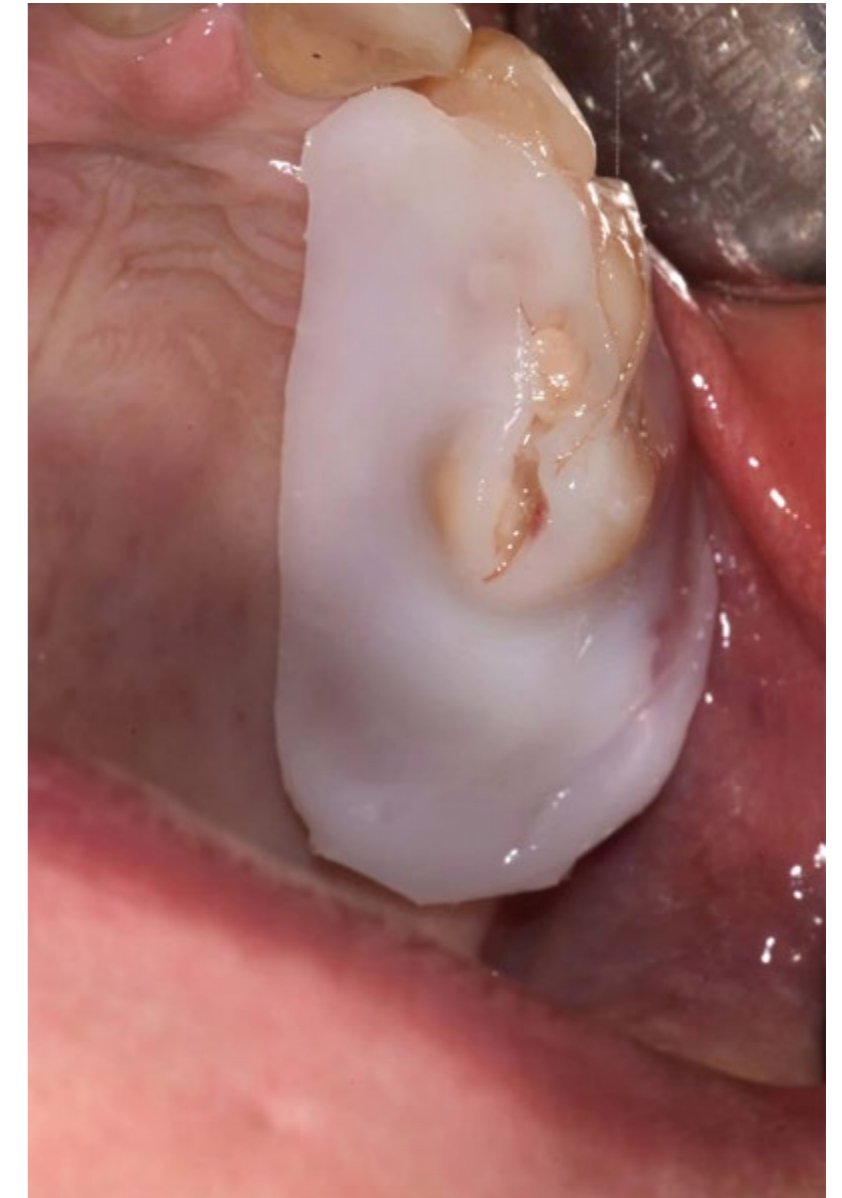
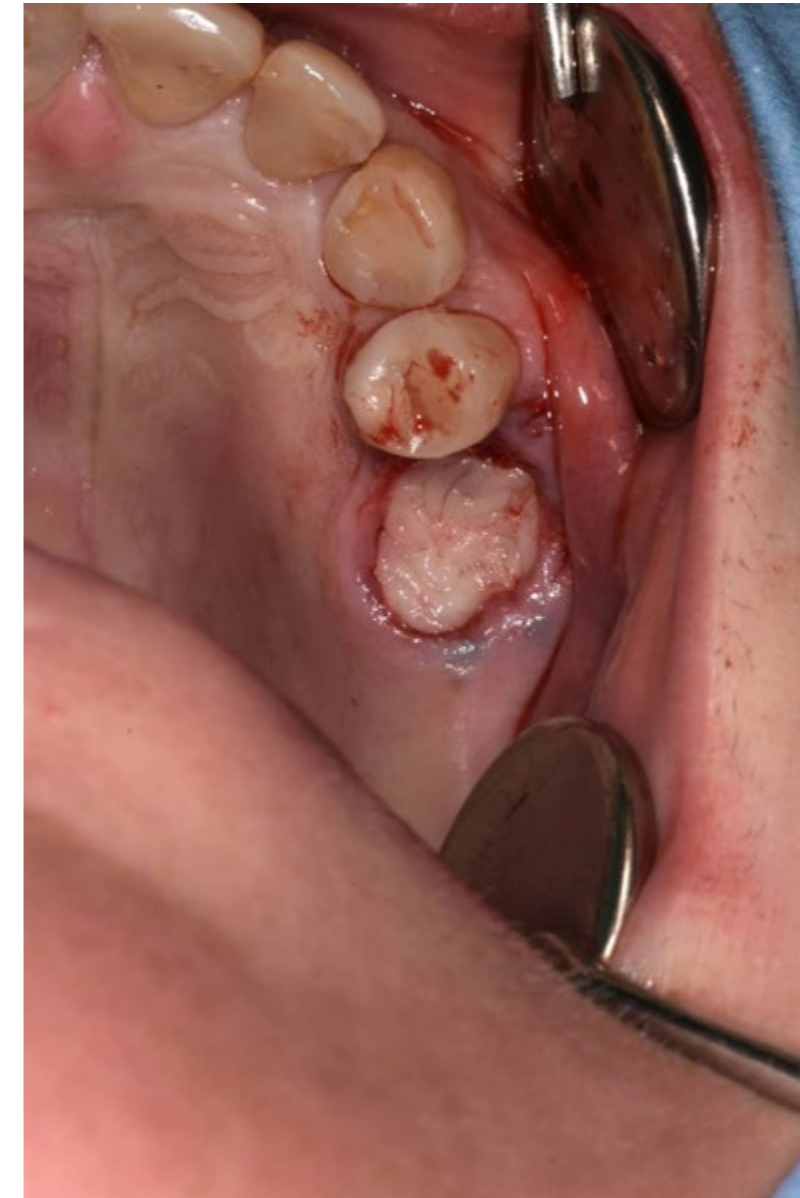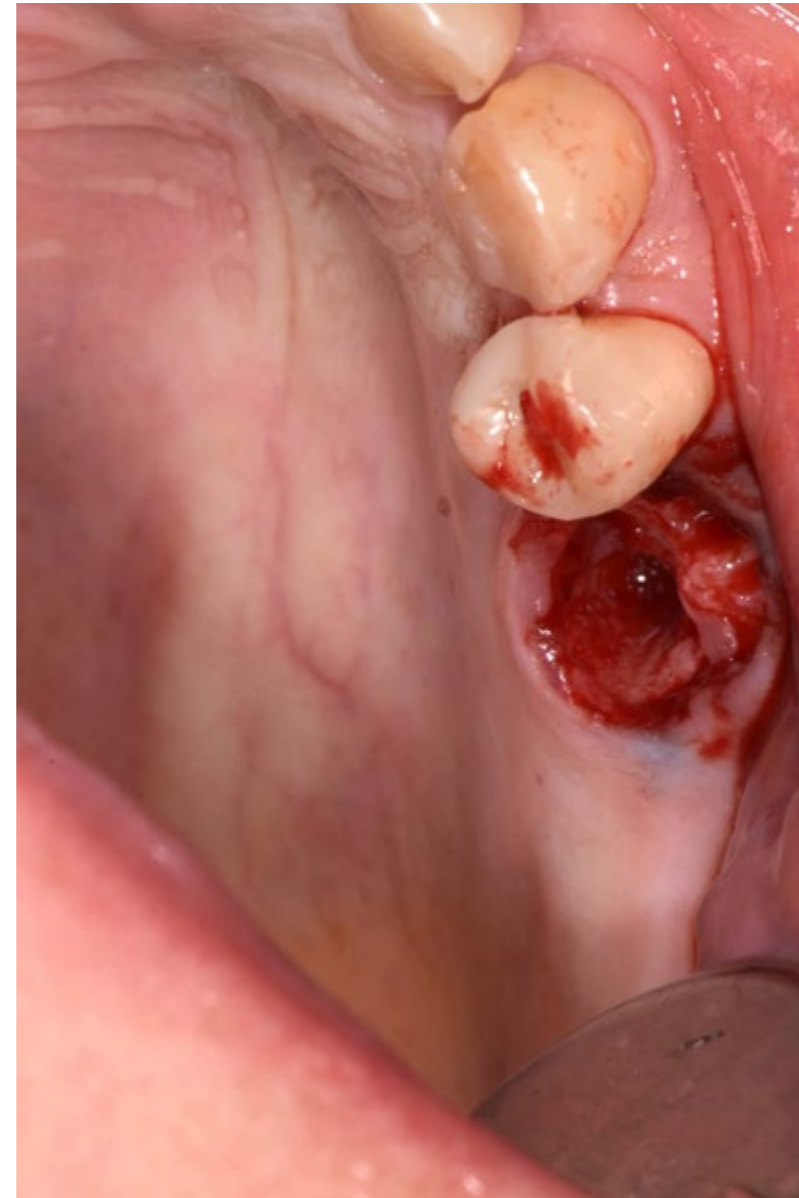
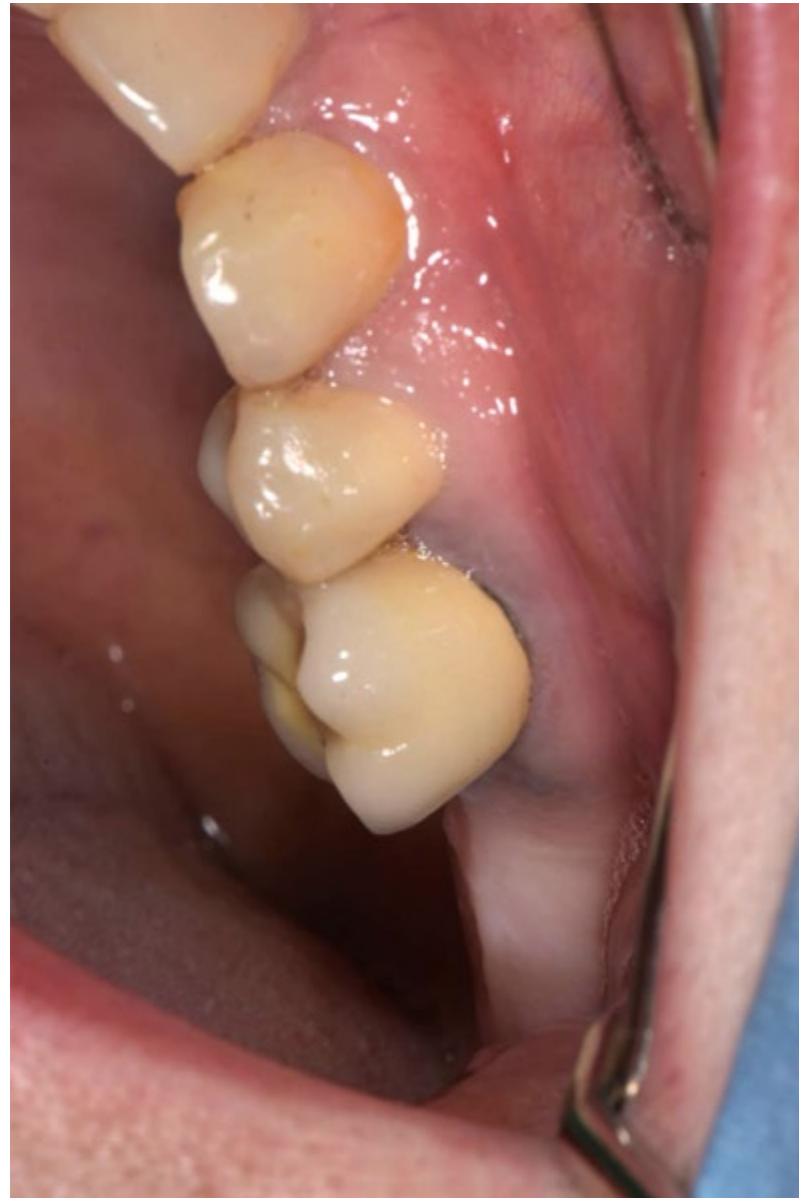Application

Sealing of the extraction socket



Application

Sealing of the extraction socket

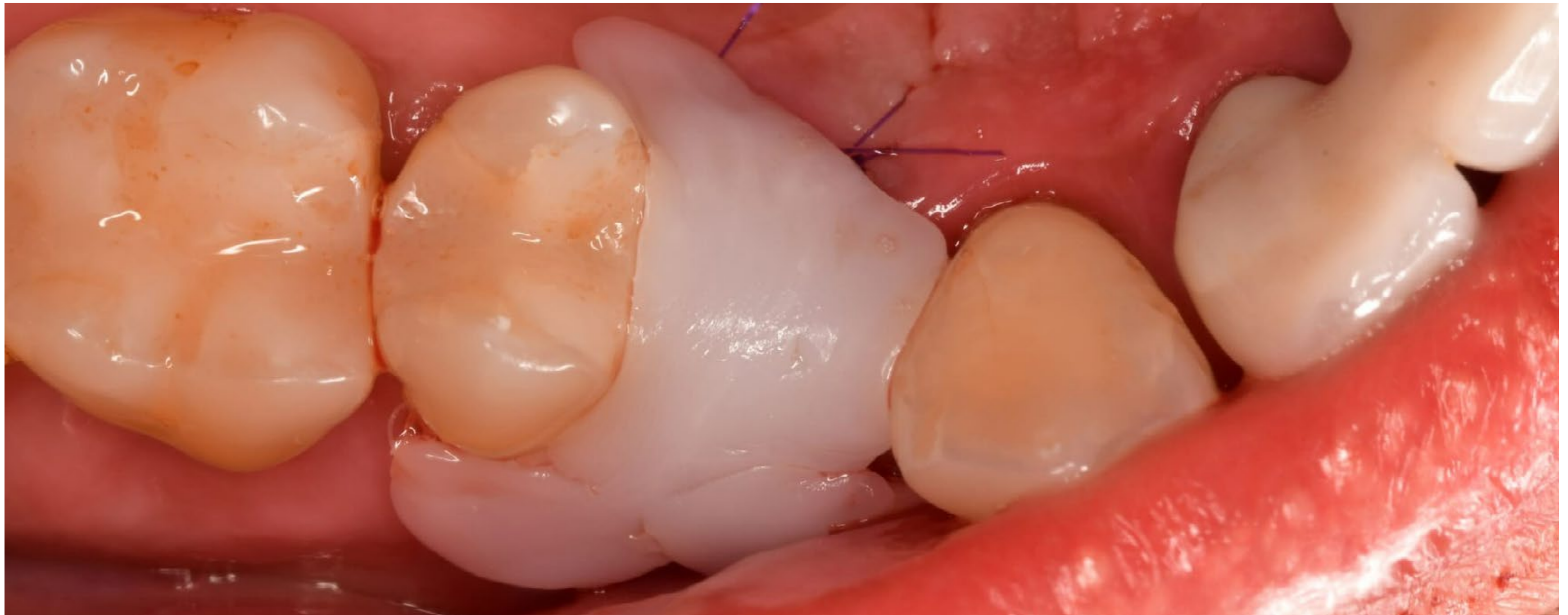


Elemental seal with composite fixation instead of mechanical retention.



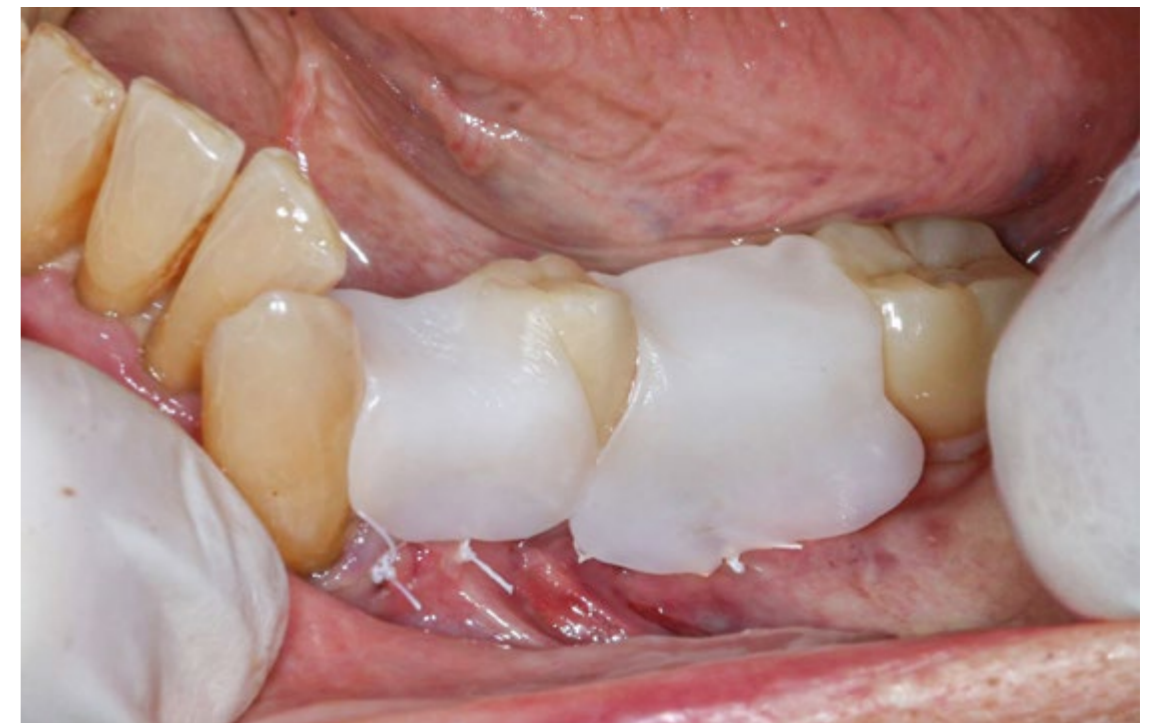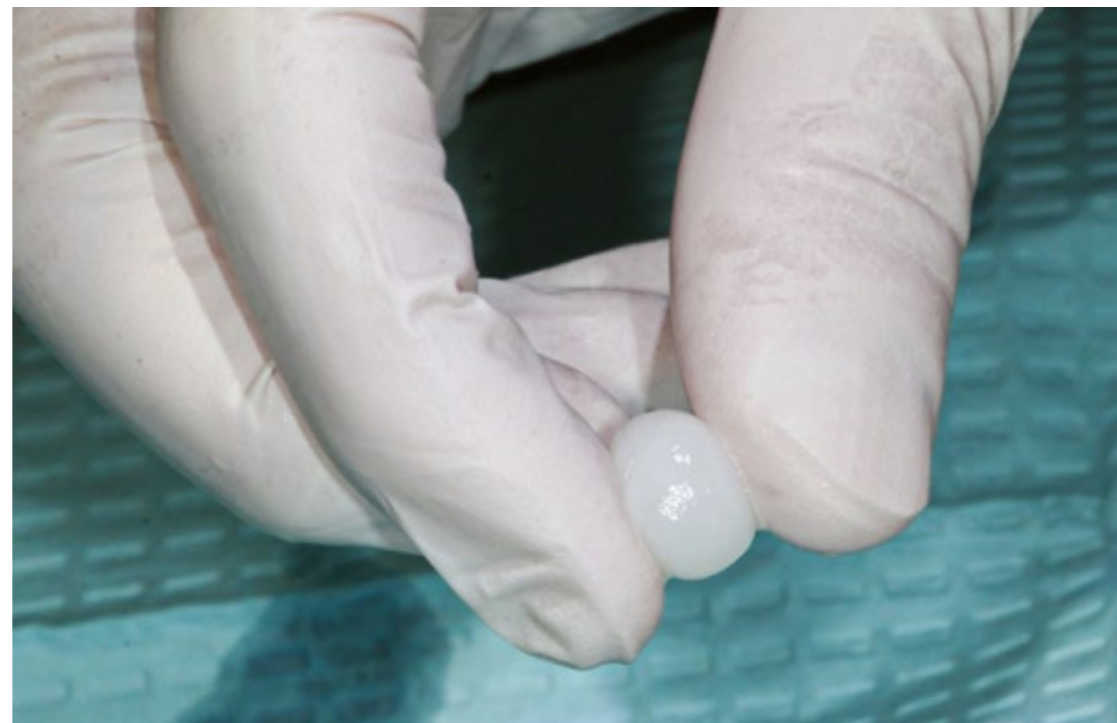
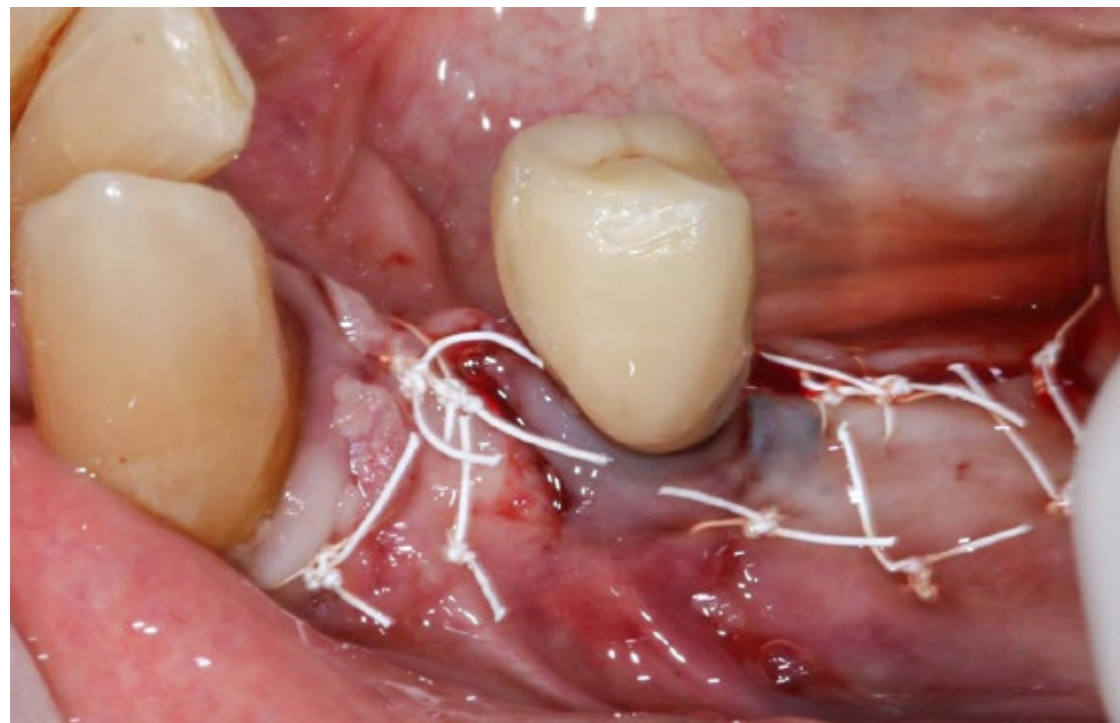
Application

Sealing of the extraction socket after PRF placement



Application

Elemental as adjunct to soft tissue healing after PRF placement



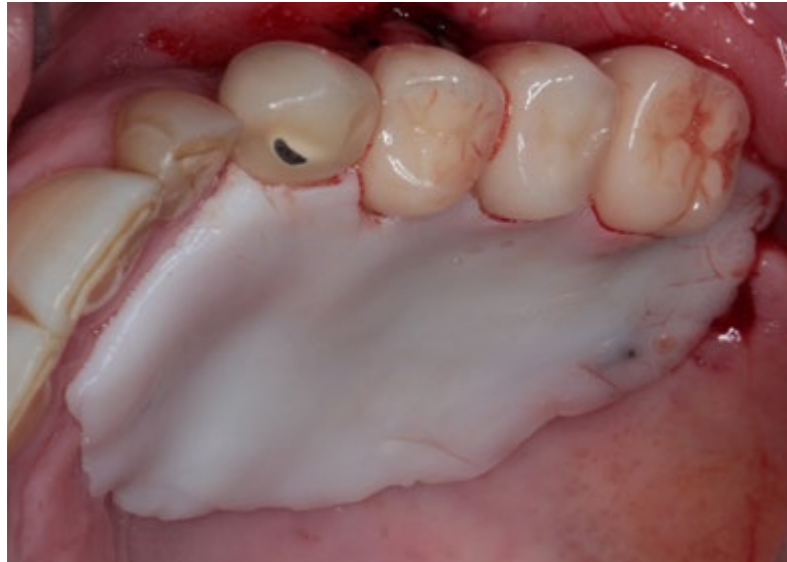

APPLICATION

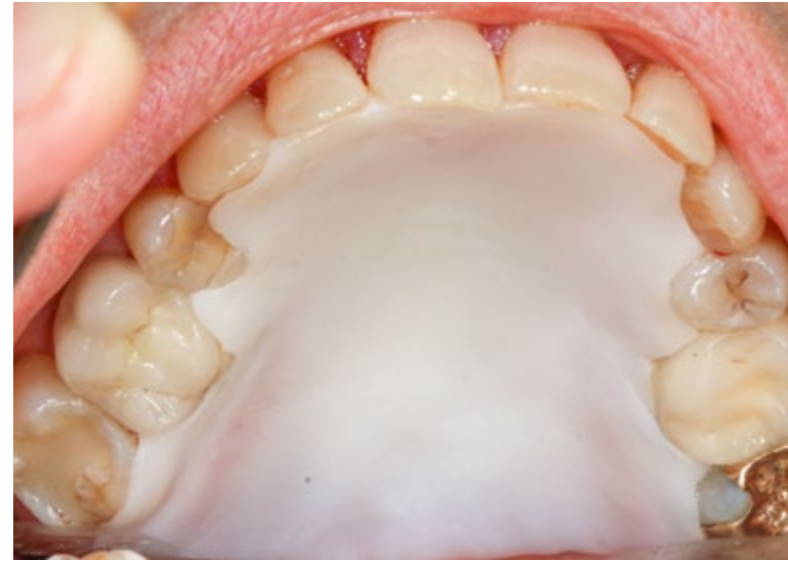**Palatal stent on donor site
after soft tissue harvesting techniques.**

Palatal stent

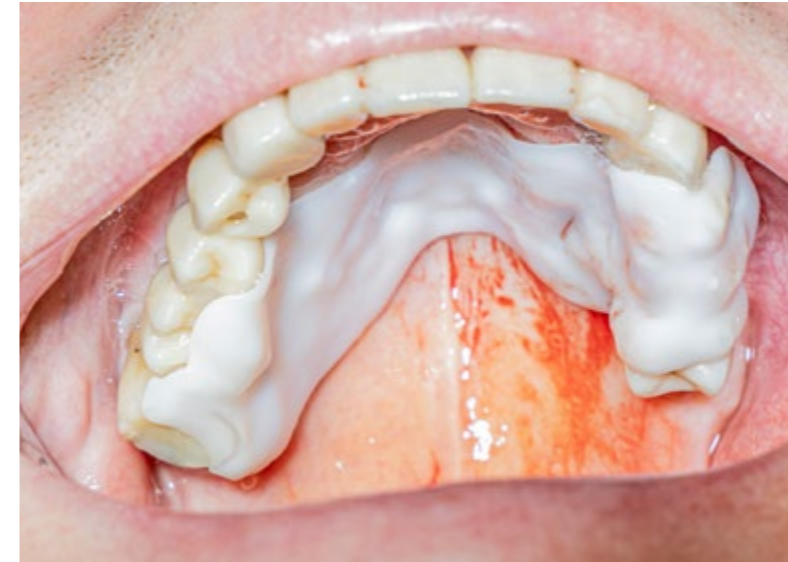Techniques for retention



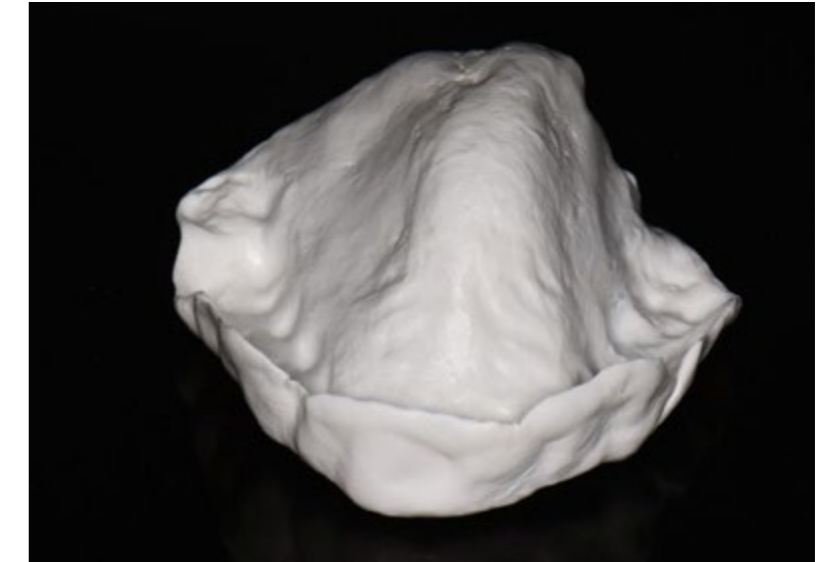Partial palatalstent, interproximal mechanical retention.
With haemostatic agent sutured on the donor site.



Full palatal stent, interproximal mechanical retention.
No haemostatic agent or suturing on the donor site.



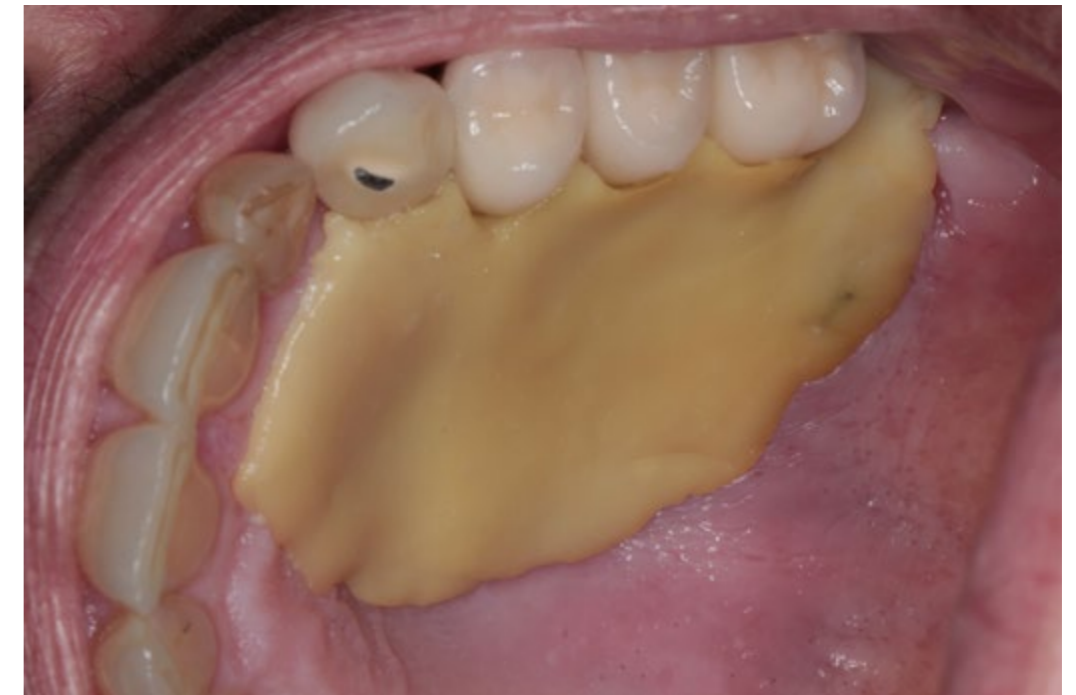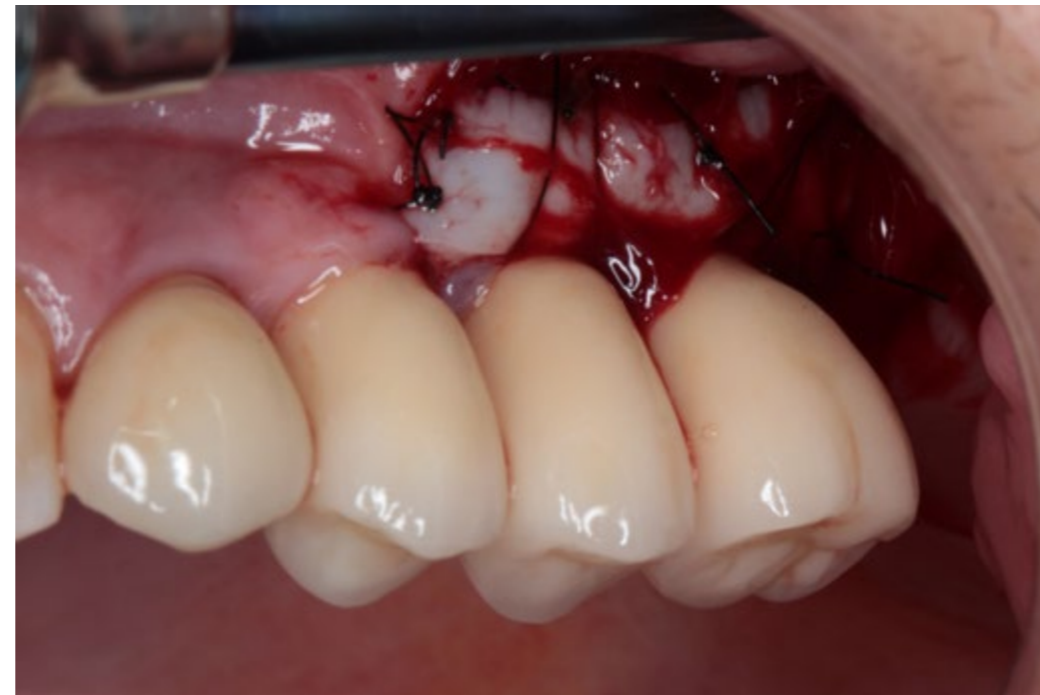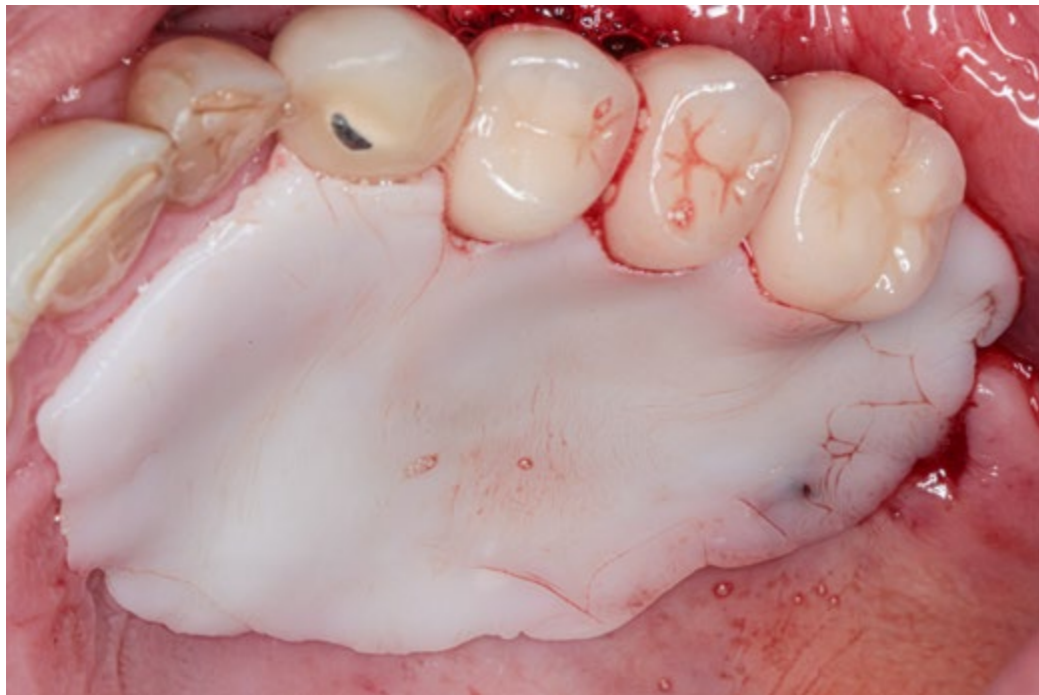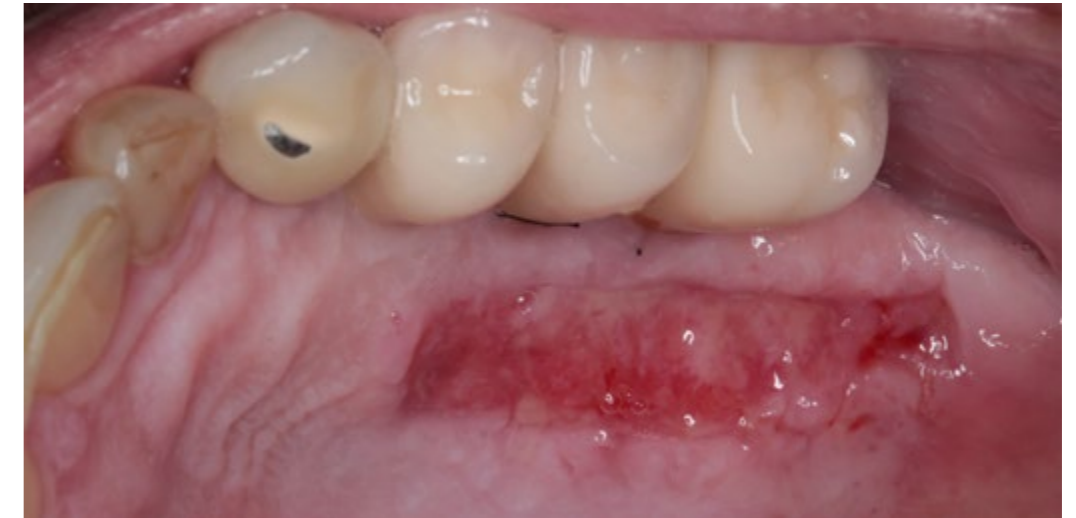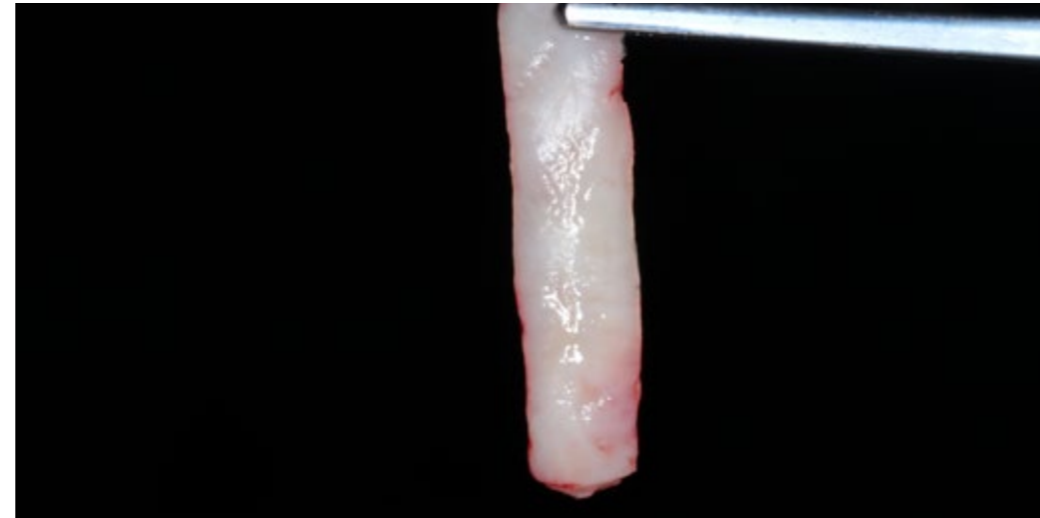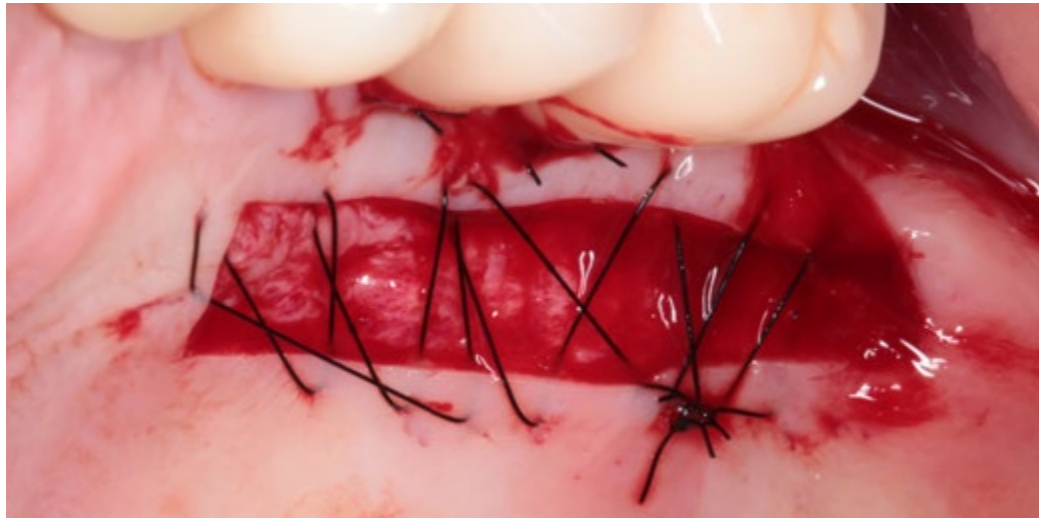Partial palatal stent, combination of mechanical interproximal retention + retention on occlusal & buccal surface of molars. No haemostatic agent or suturing on the donor site.



Full palatal stent, mechanical retention over incisal edges and on occlusal surface. No haemostatic agent or suturing on the donor site.

Application

Palatal stent on donor site after soft tissue grafting

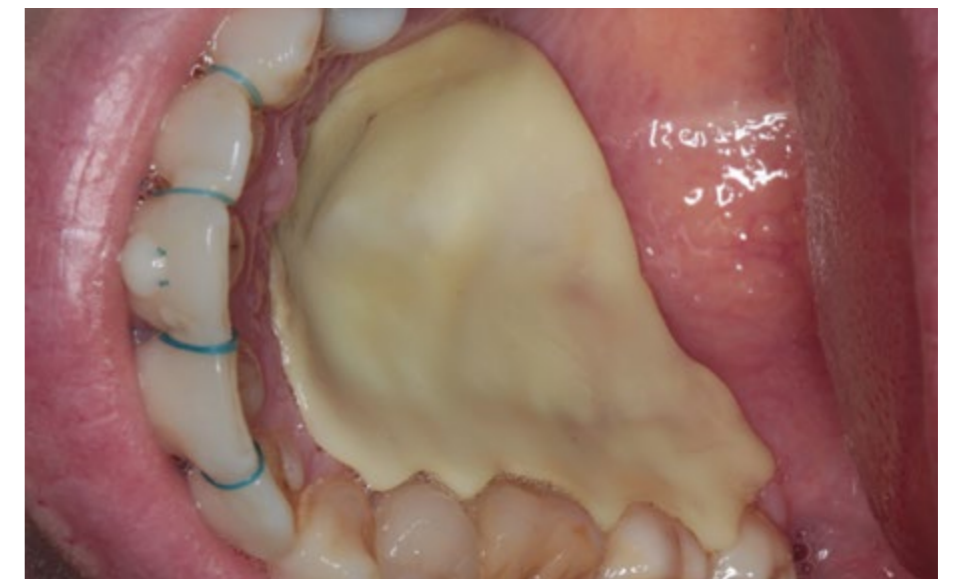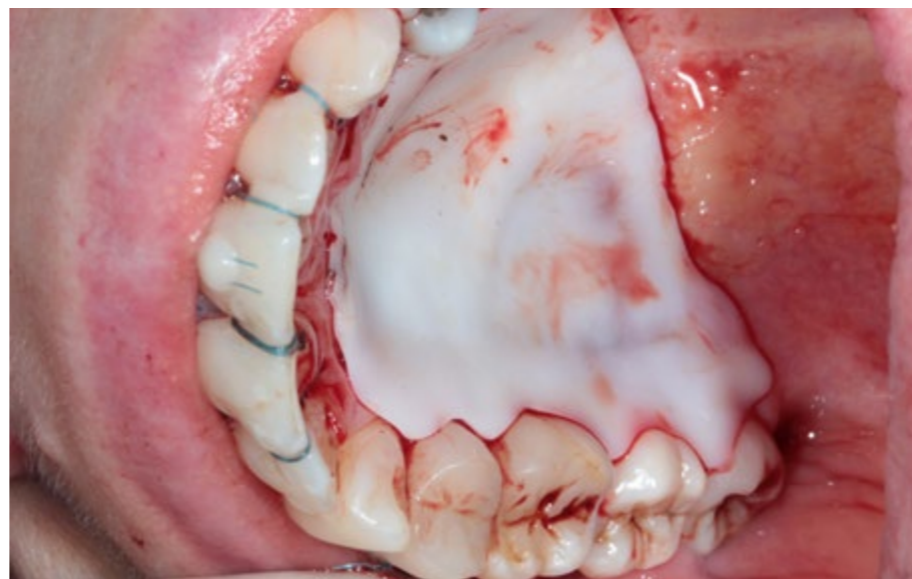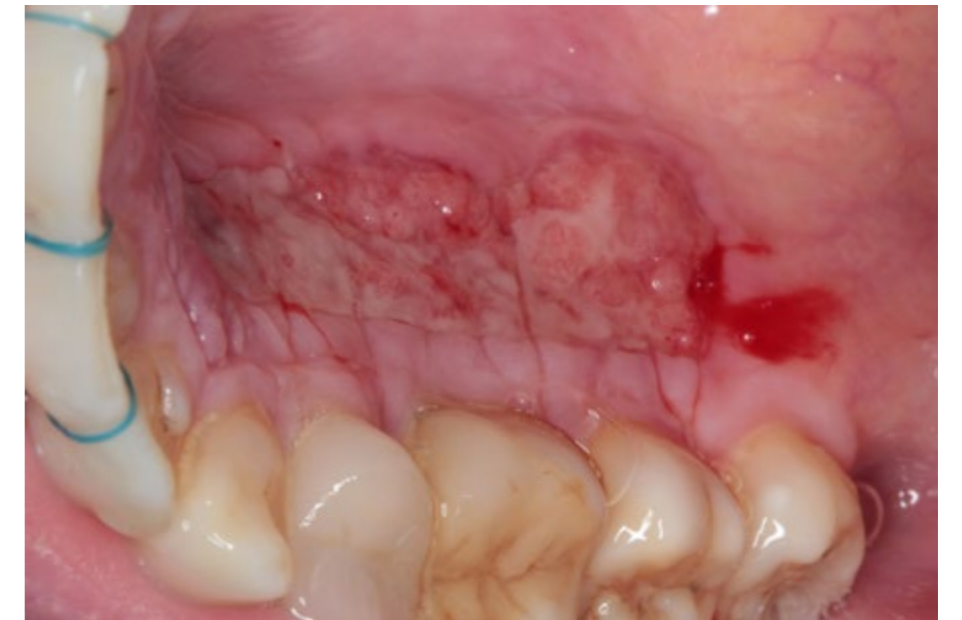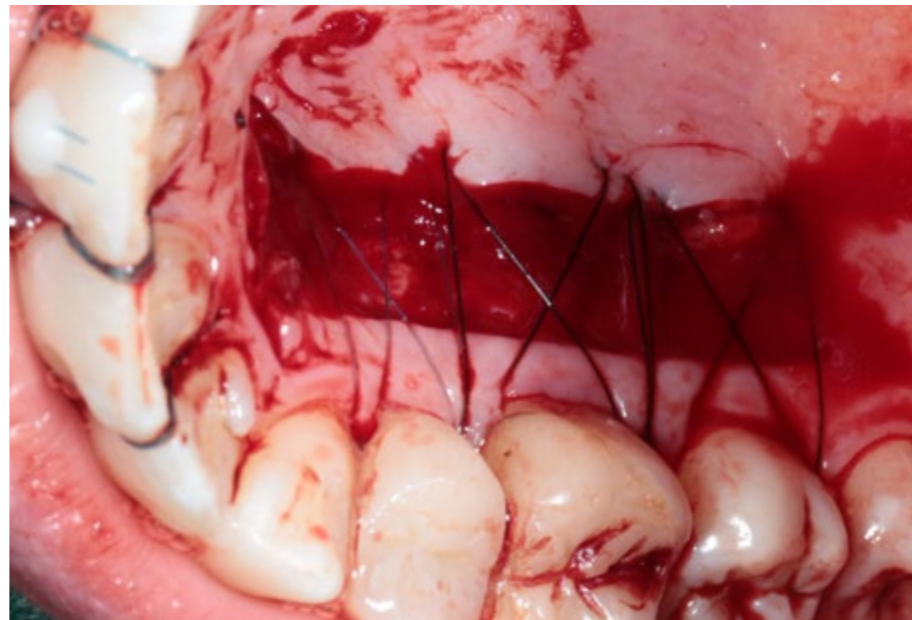


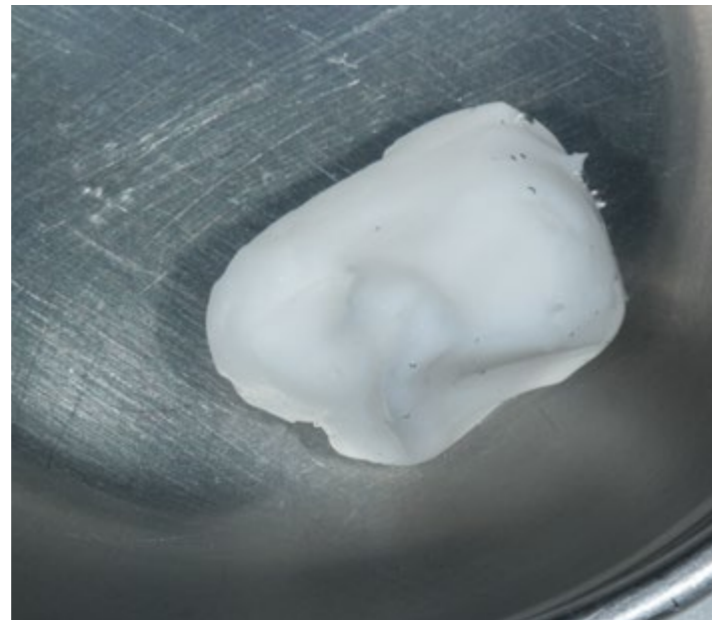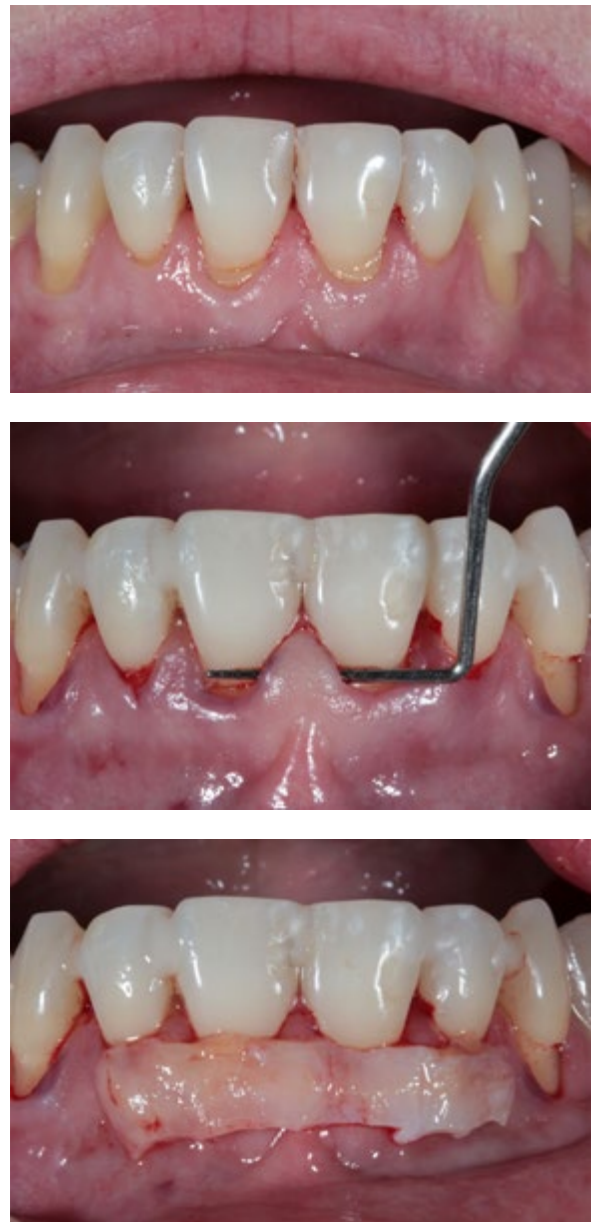Day of surgery

Follow-up

Application

Palatal stent on donor site after soft tissue grafting



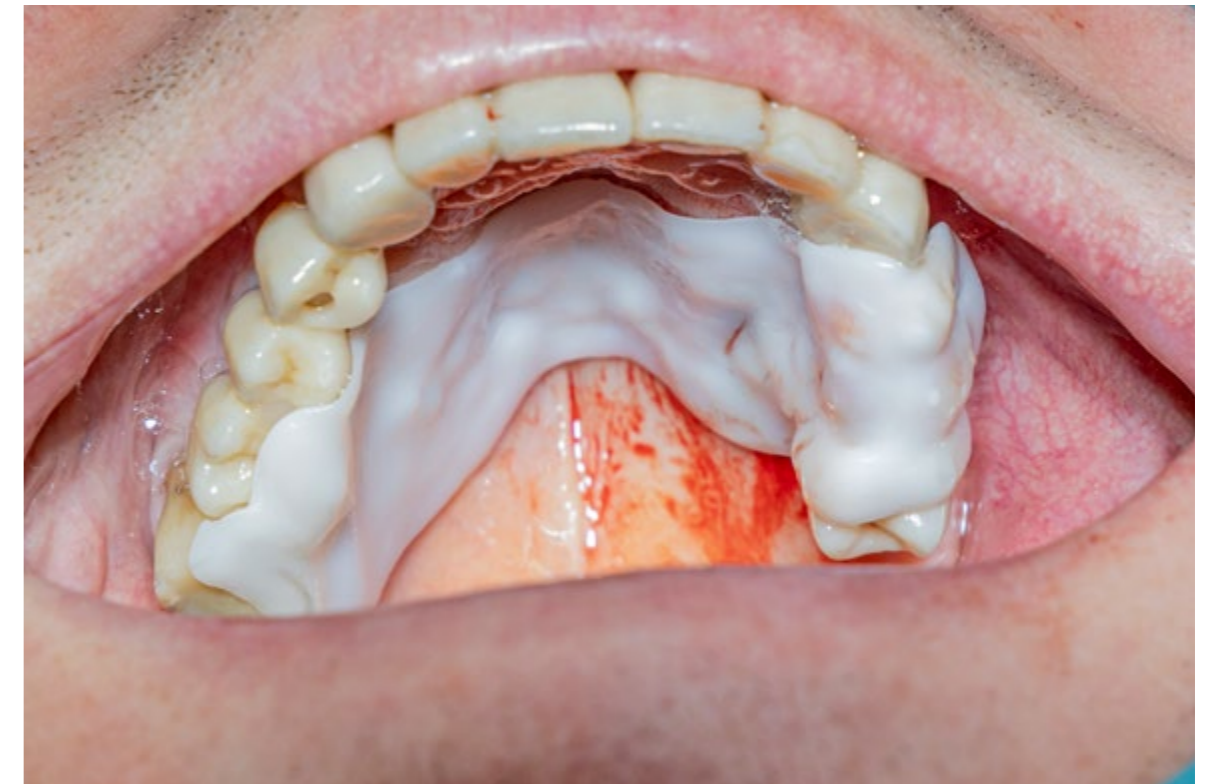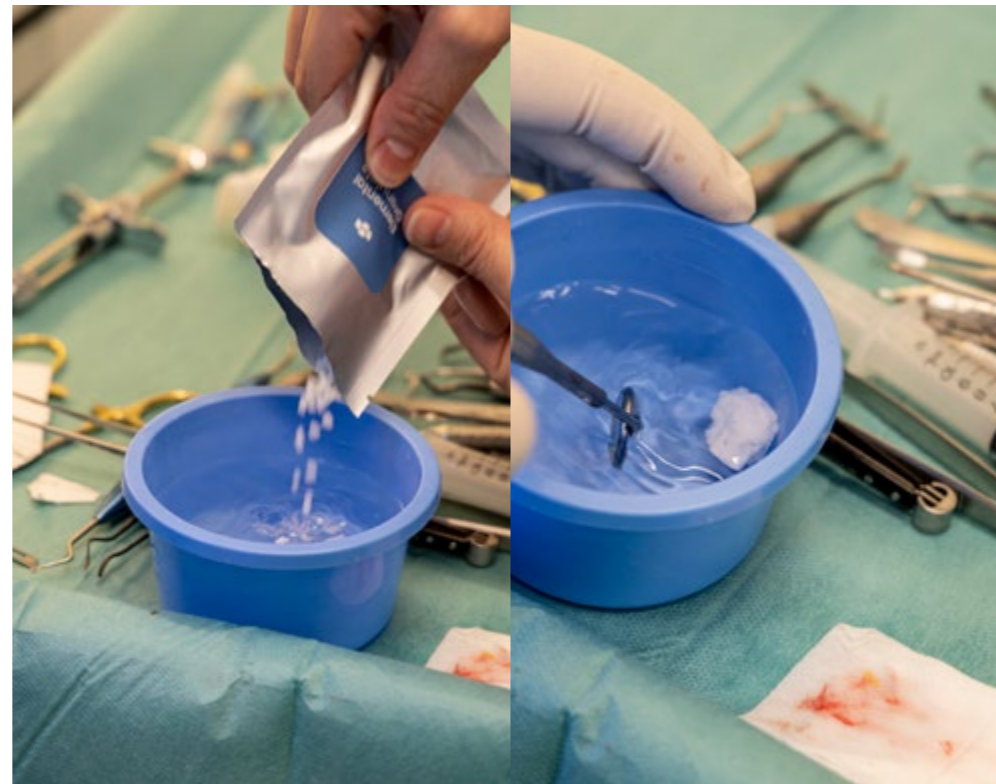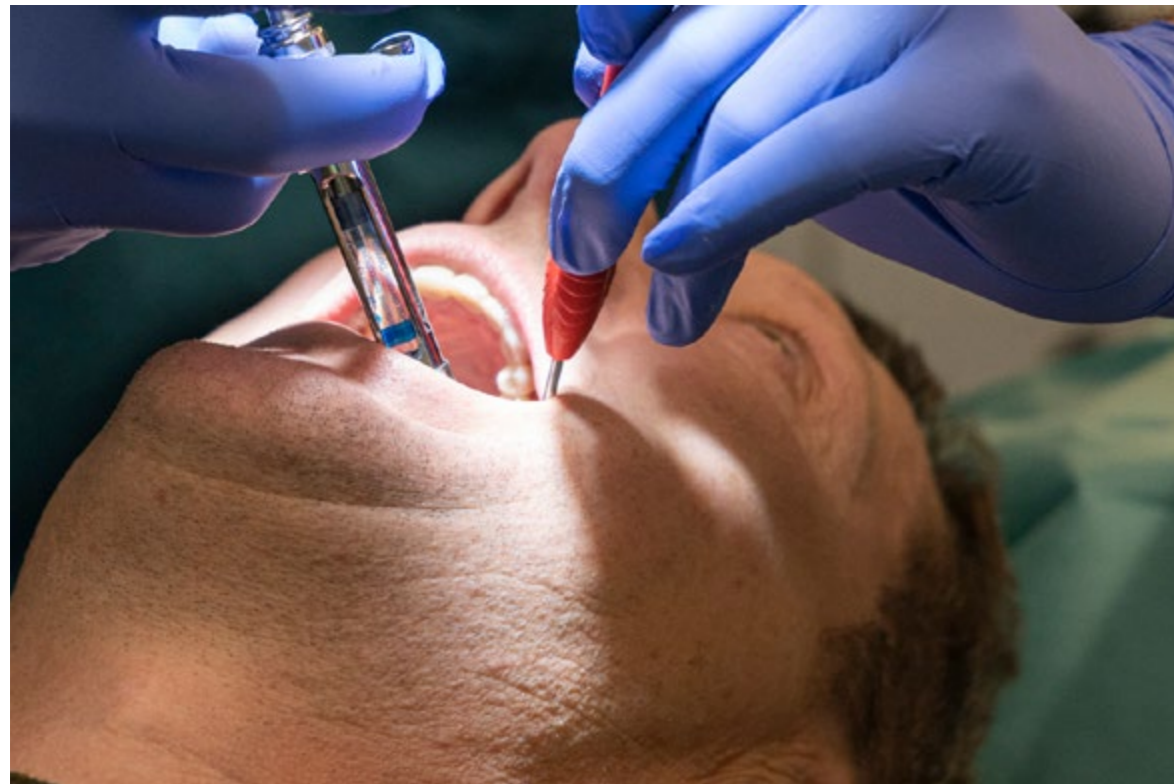Day of surgery

Follow-up



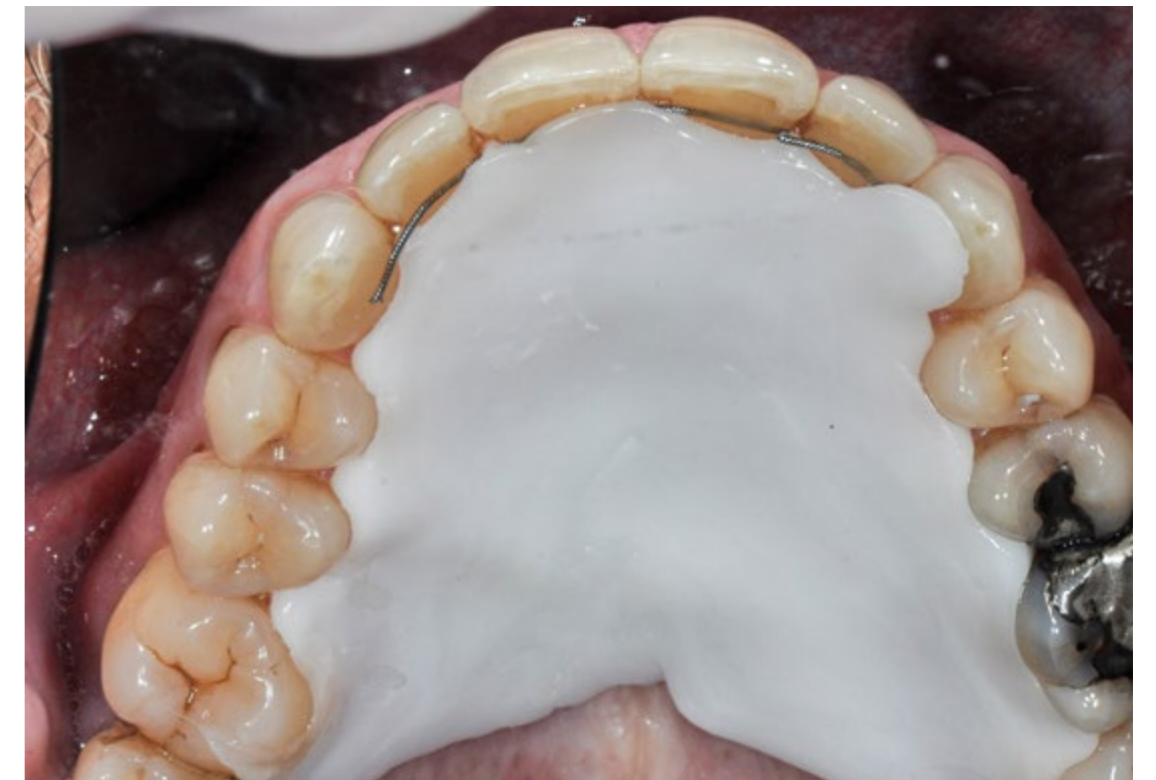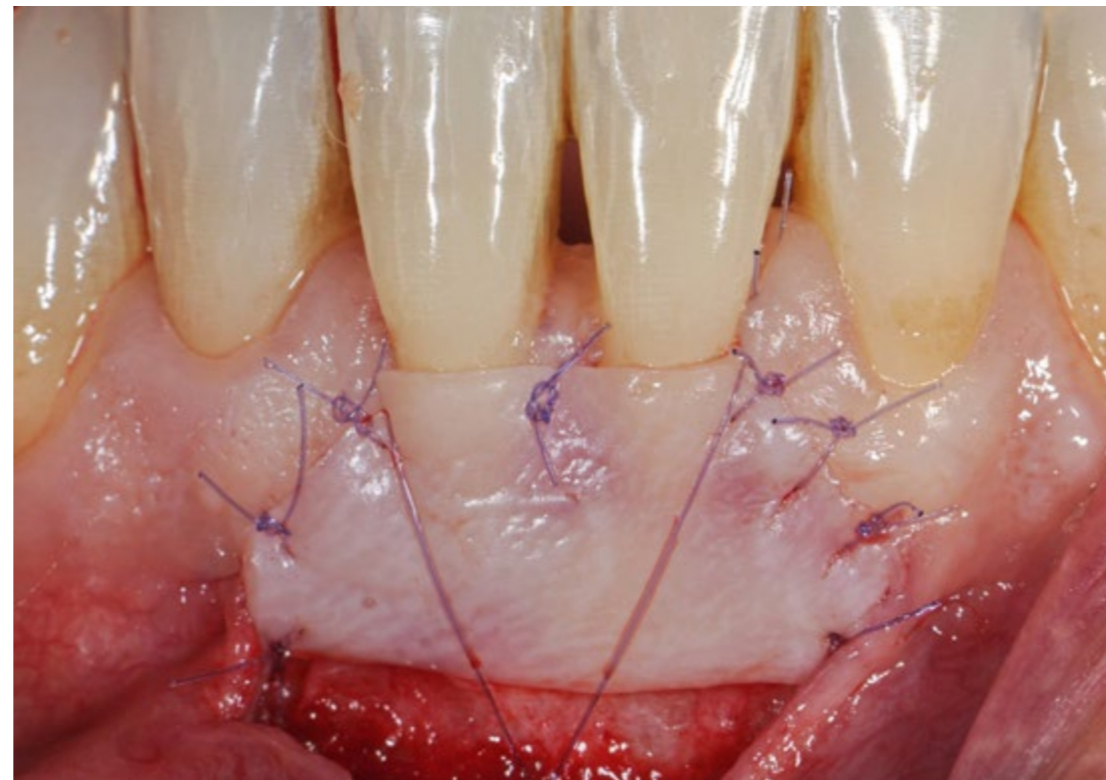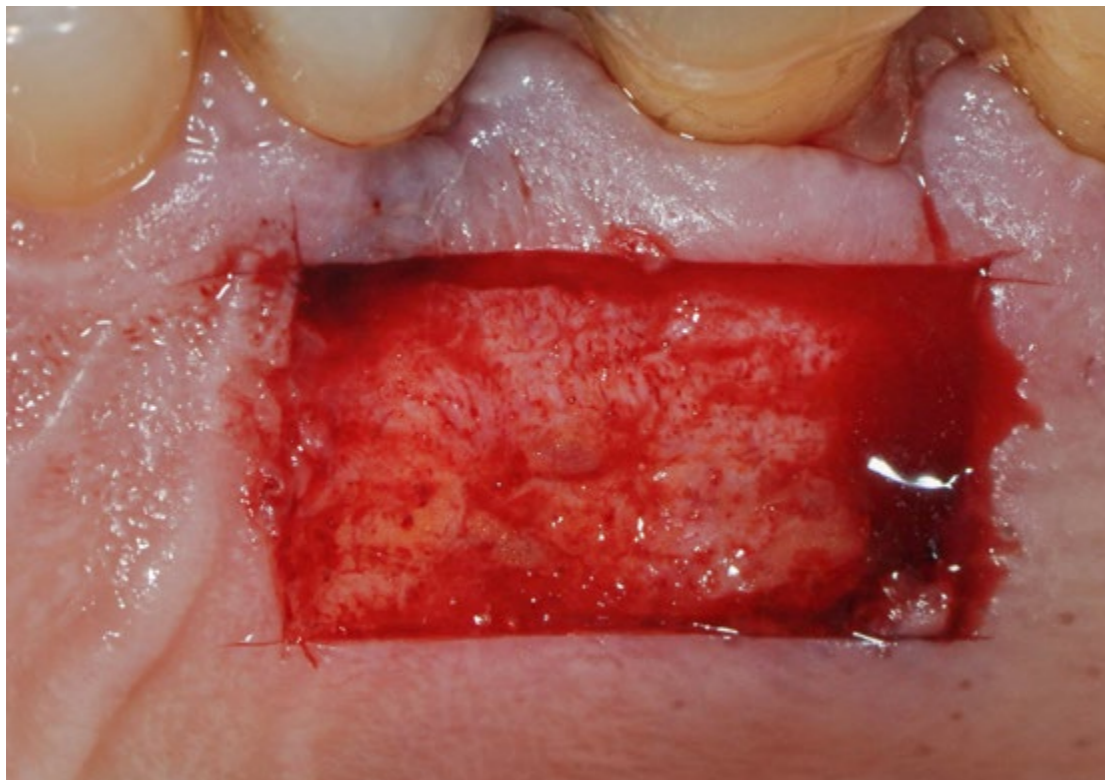
Application

Palatal stent on donor site after soft tissue grafting



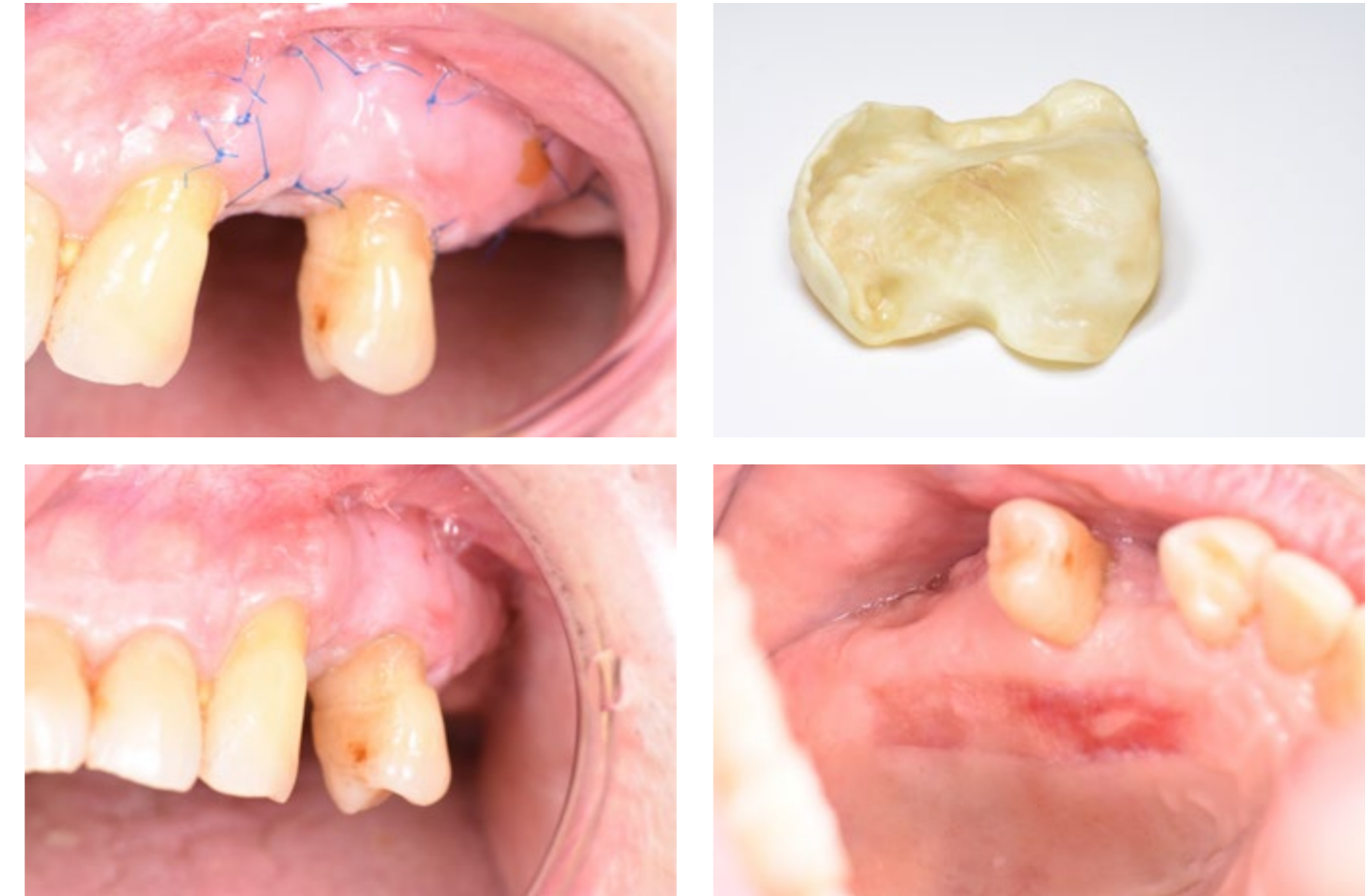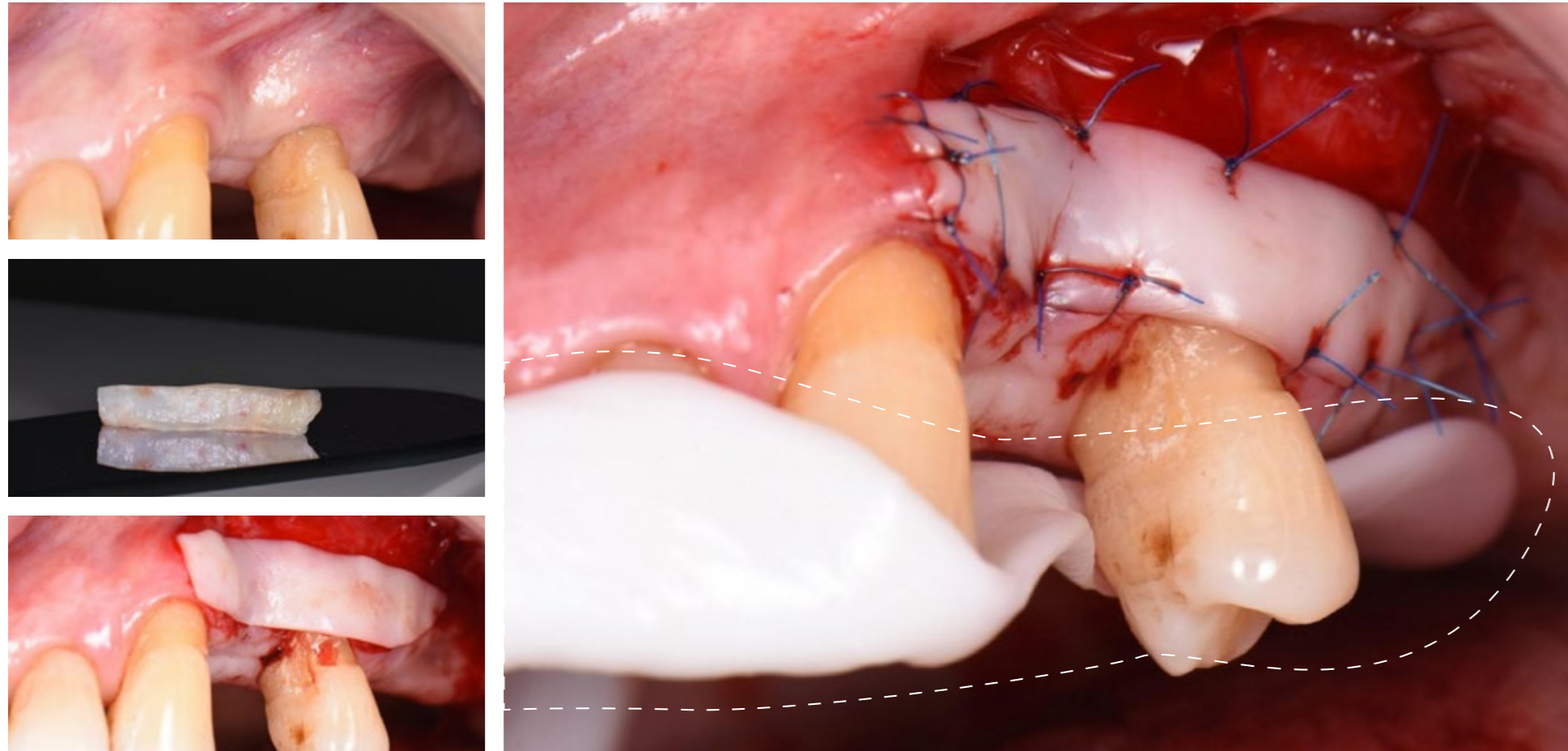
Application

Palatal stent on donor site after soft tissue grafting



Application

Palatal stent on donor site after soft tissue grafting



Day of surgery

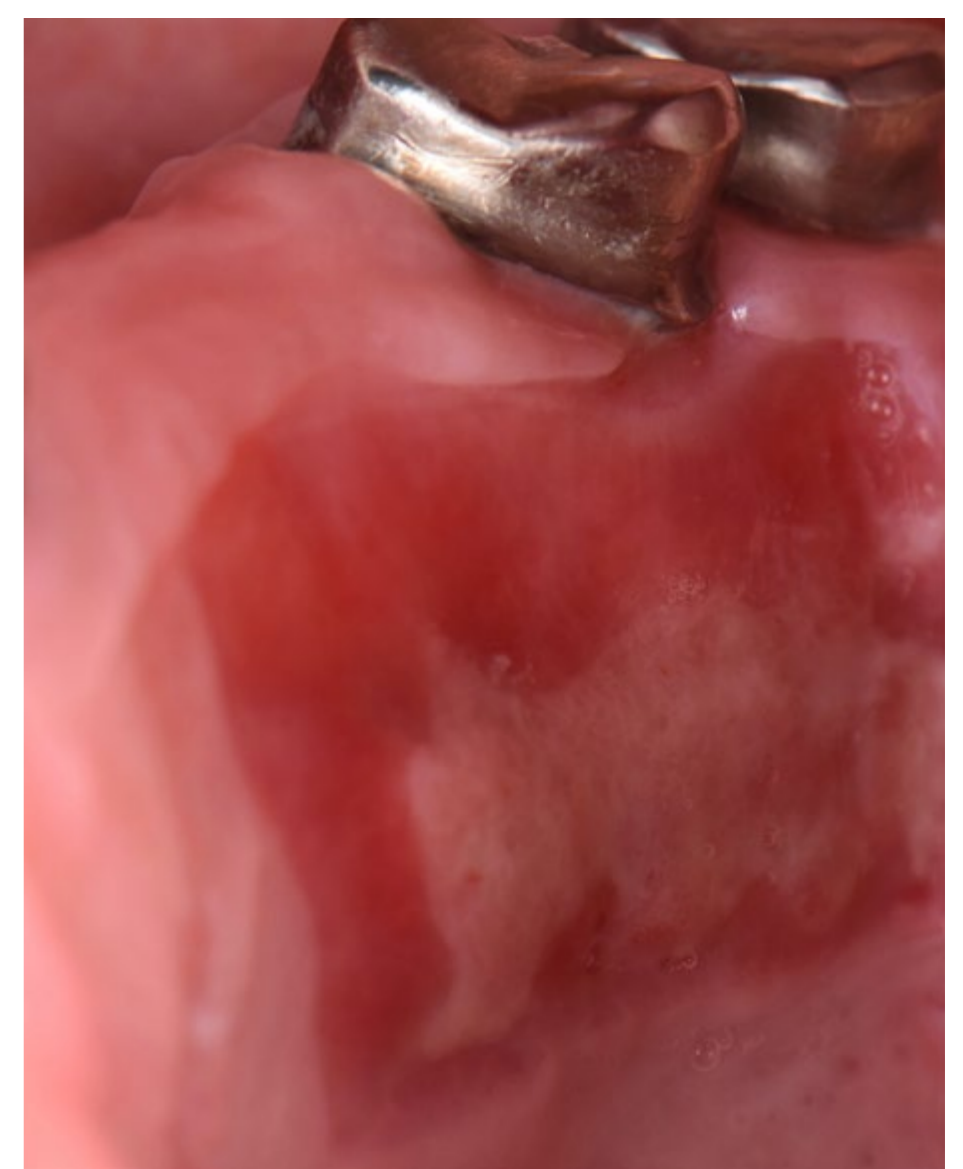
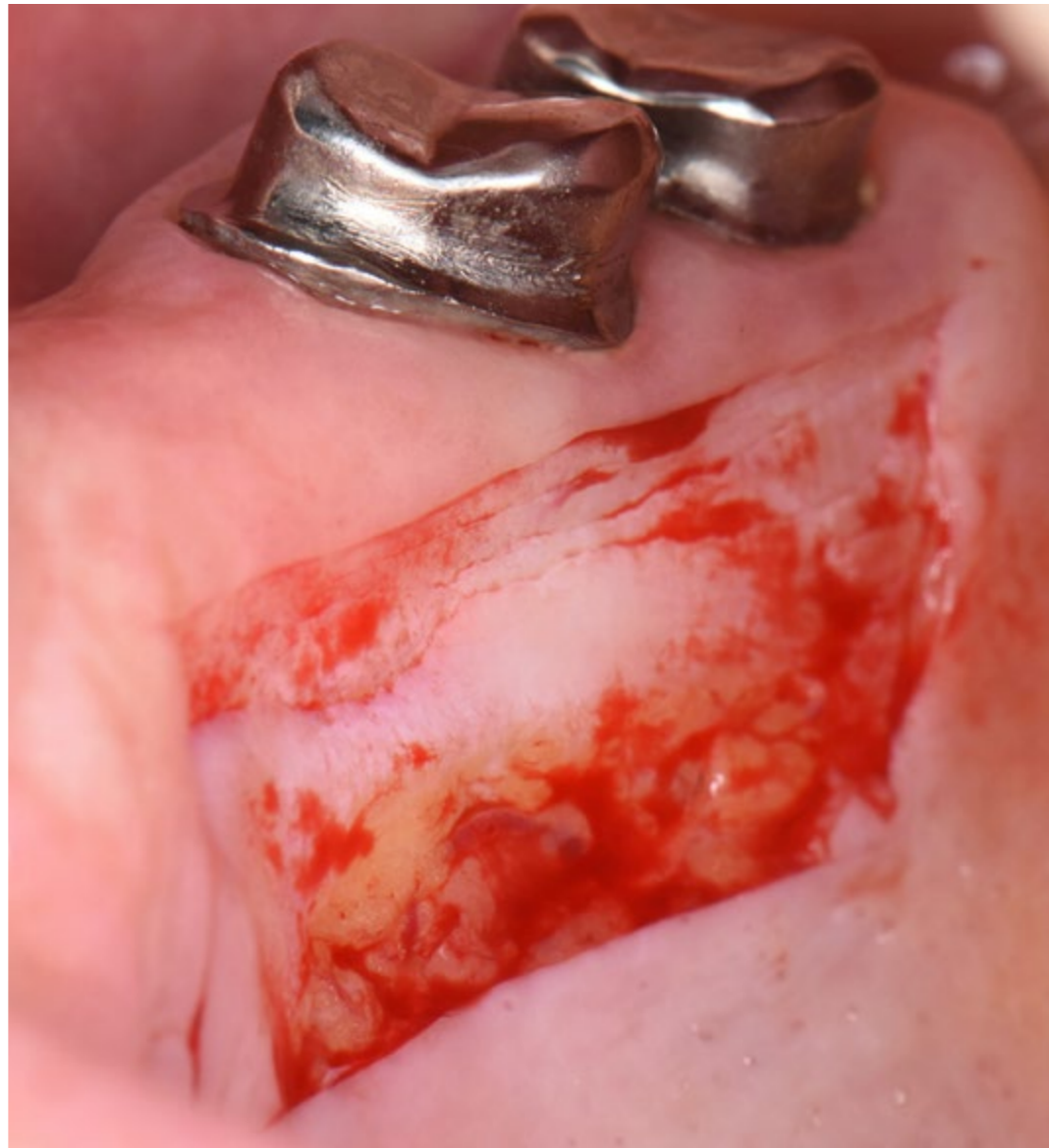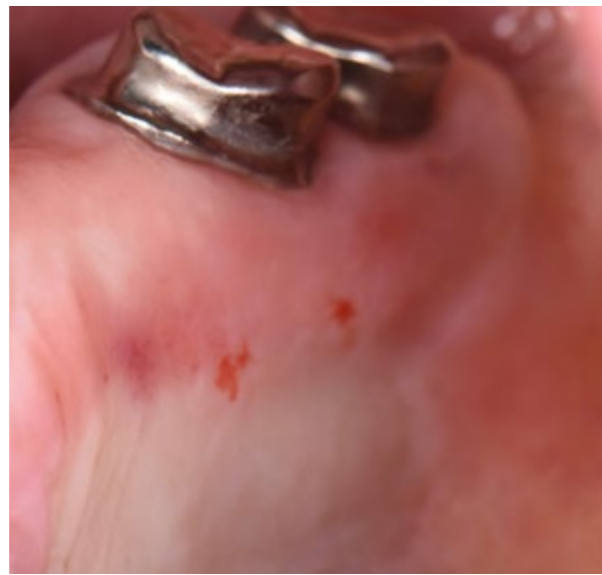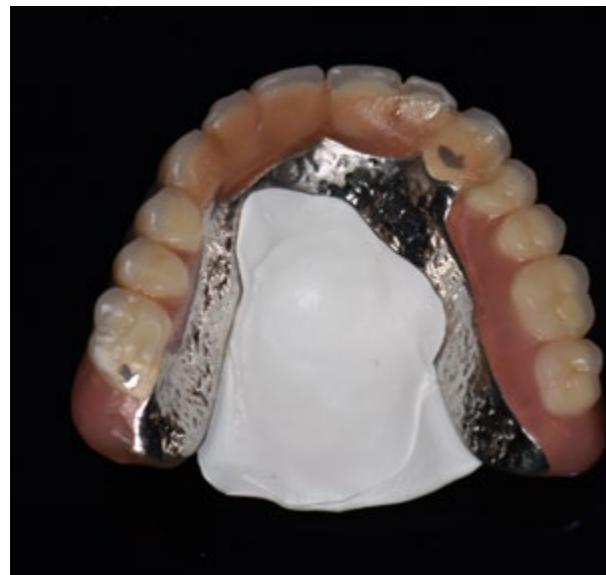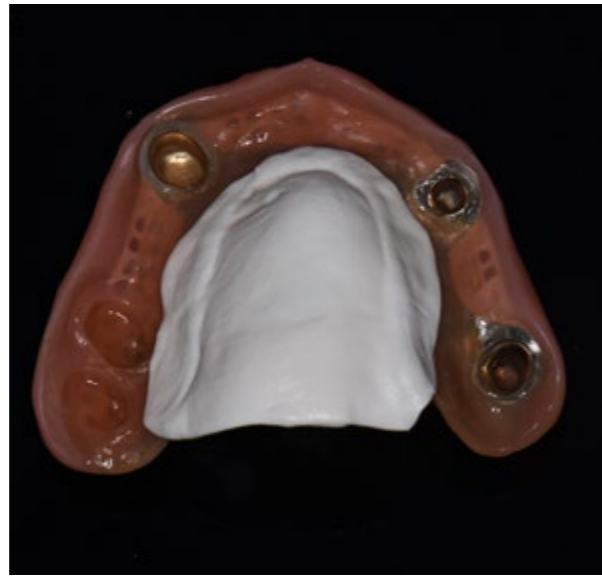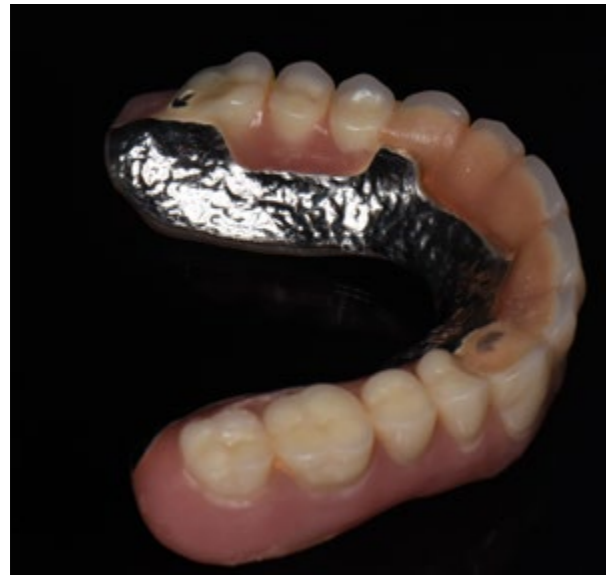“Preparation of recipient site, incision at mucogingival border. Apically displaced flap, removal of muscle tissue. Sutured apically with serafast 6-0. Harvesting donor site: Q2, no sutures used, Elemental granulate only. Adaptation FGG. Sutured FGG at the level of receptor site with Seralene 6-0. At the level of the recipient site, I made the stent go behind the tooth so that the stent would not get in the way of the sutures. This way, I also avoided the patient touching the graft in case he wanted to take out the stent.”

10 days post-operative

“10 days post-op after Free Gingival Graft at the level of implant site 24 and element 25. Phenotype modification. Patient barely took out the stent for 10 days (see discoloration of material). Furthermore, patient reported no post-operative pain.”

Application

Adaptive prosthesis as donor site stent



Day of surgery

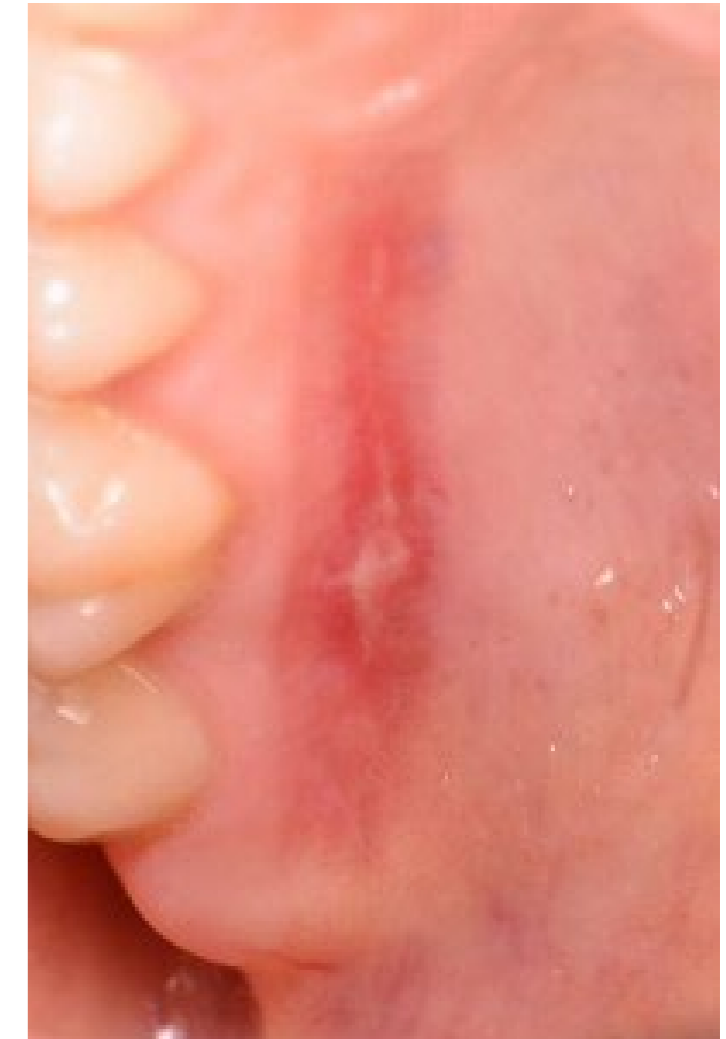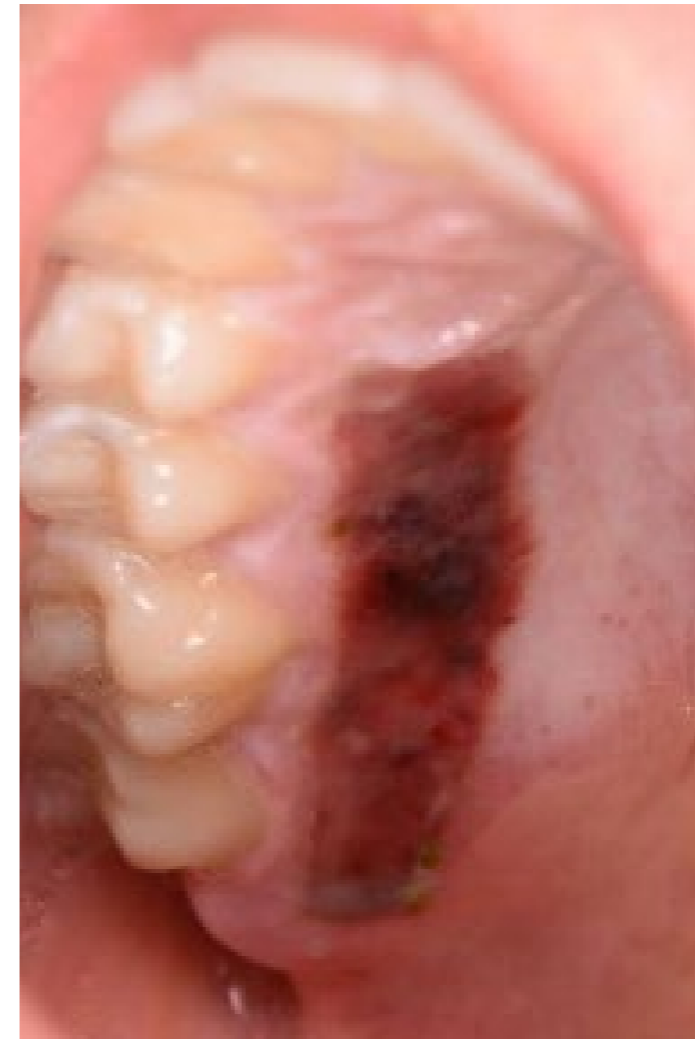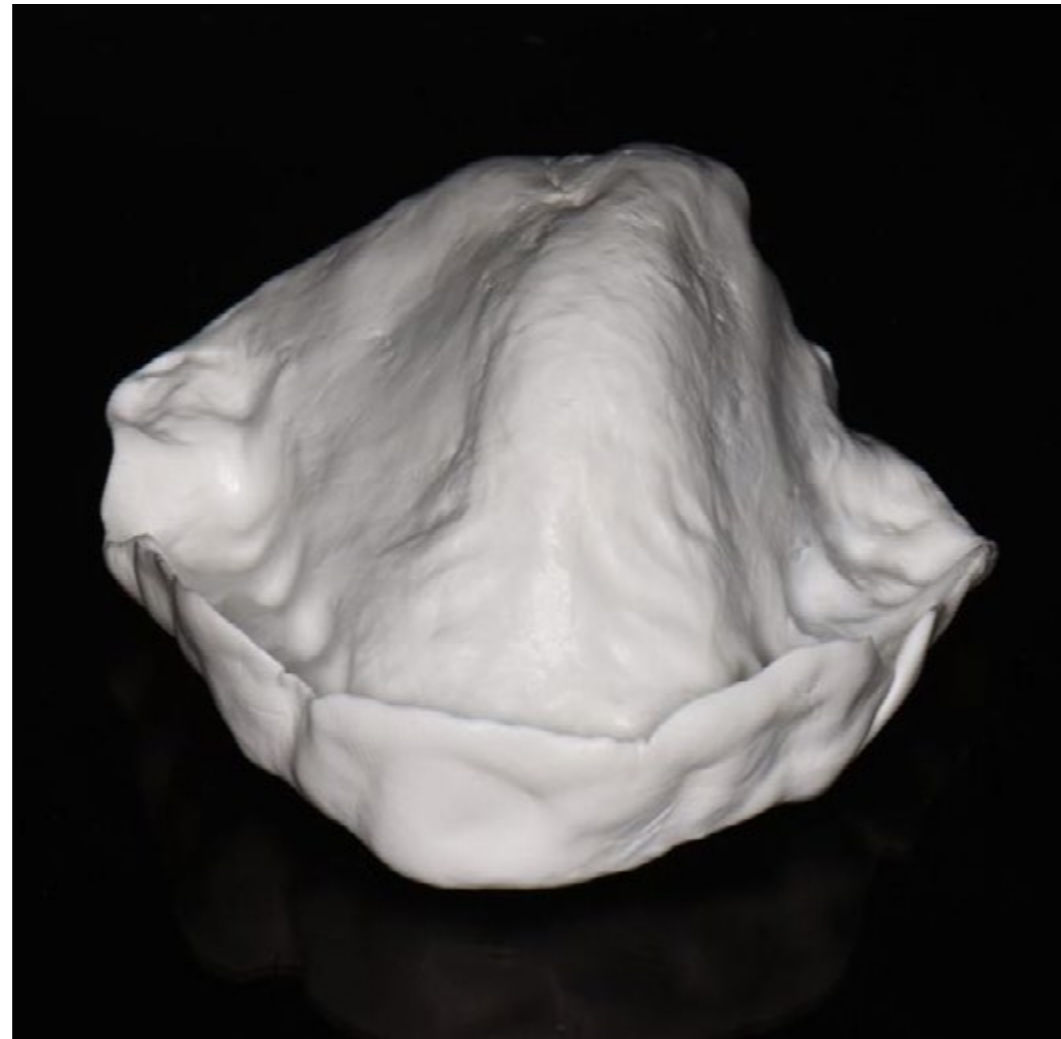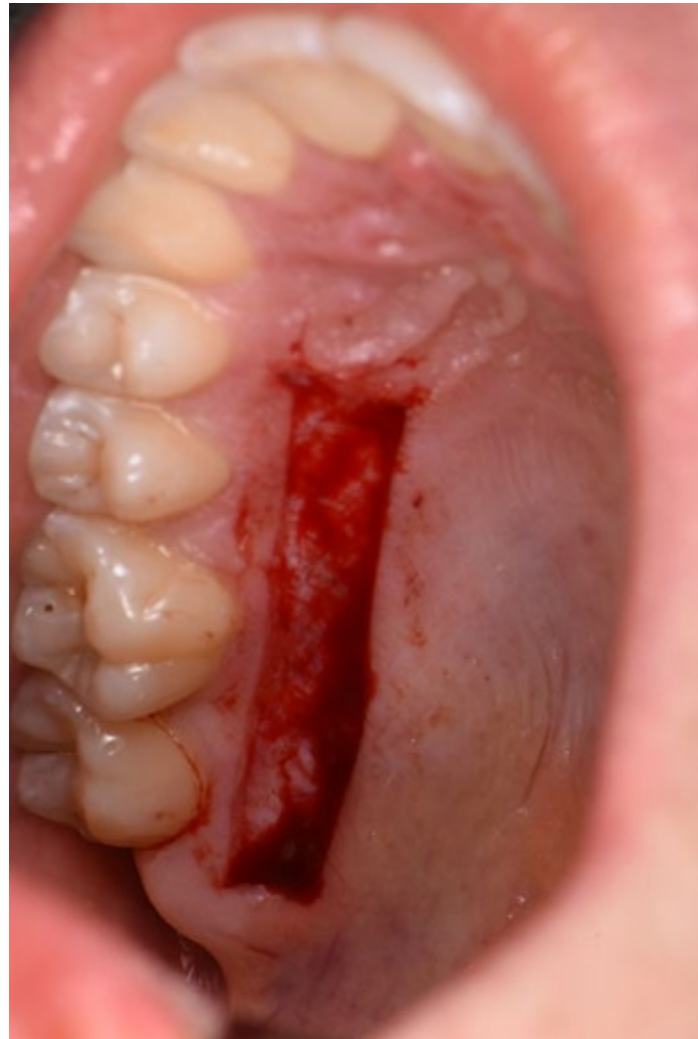Using the Elemental granulate, Dr. De Greef made an extension of the patient's prosthesis, creating an adaptive prosthesis. This way, the patient could keep on wearing her prosthesis while covering the donor site wound with the granulate material. The extension was made in such a way that the patient could remove it herself after the recommended 7 days.

7 days post-operative

Healing of the donor site, no post-operative pain reported by the patient.

Application

Palatal stent on donor site after soft tissue grafting



Day of surgery

Free Gingival Graft, chairside fabrication of the stent, placement and hardening in situ.

3 days post-operative

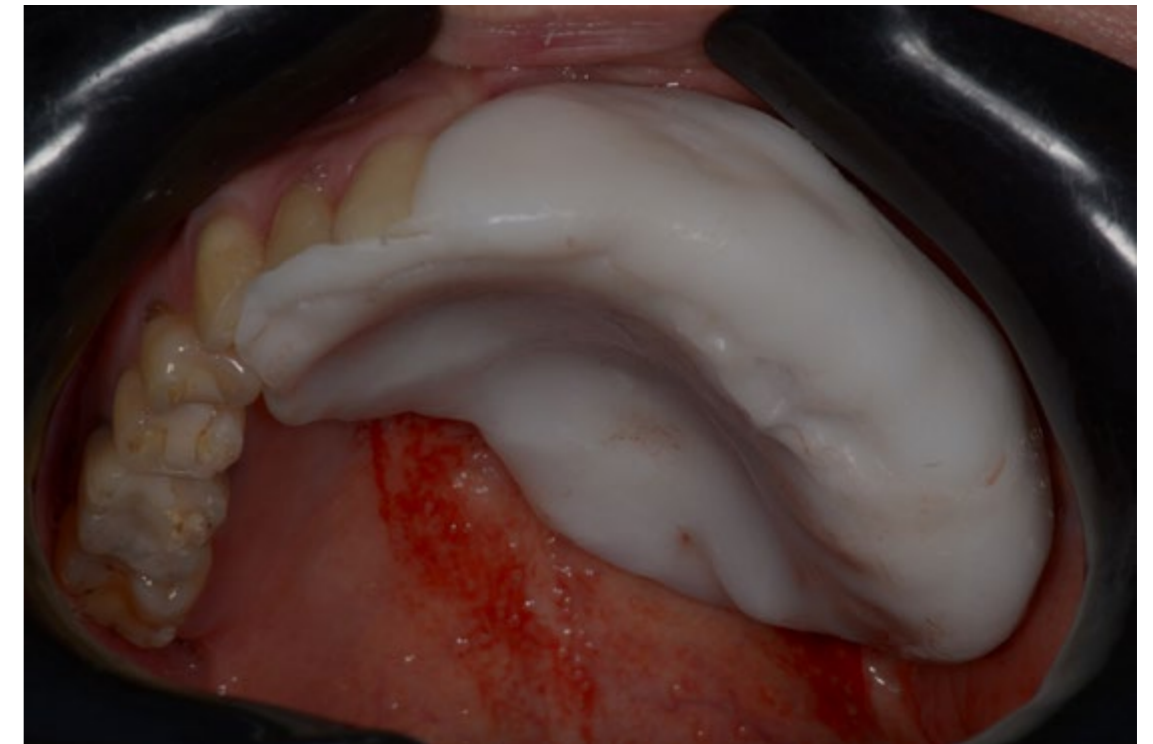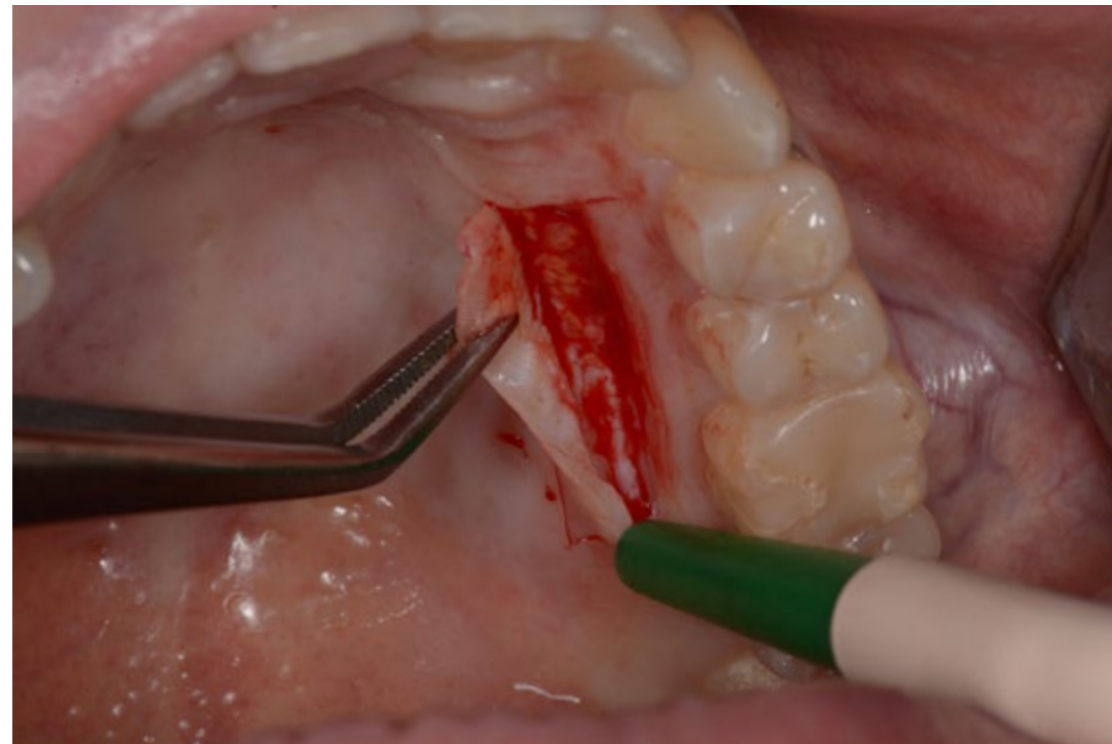
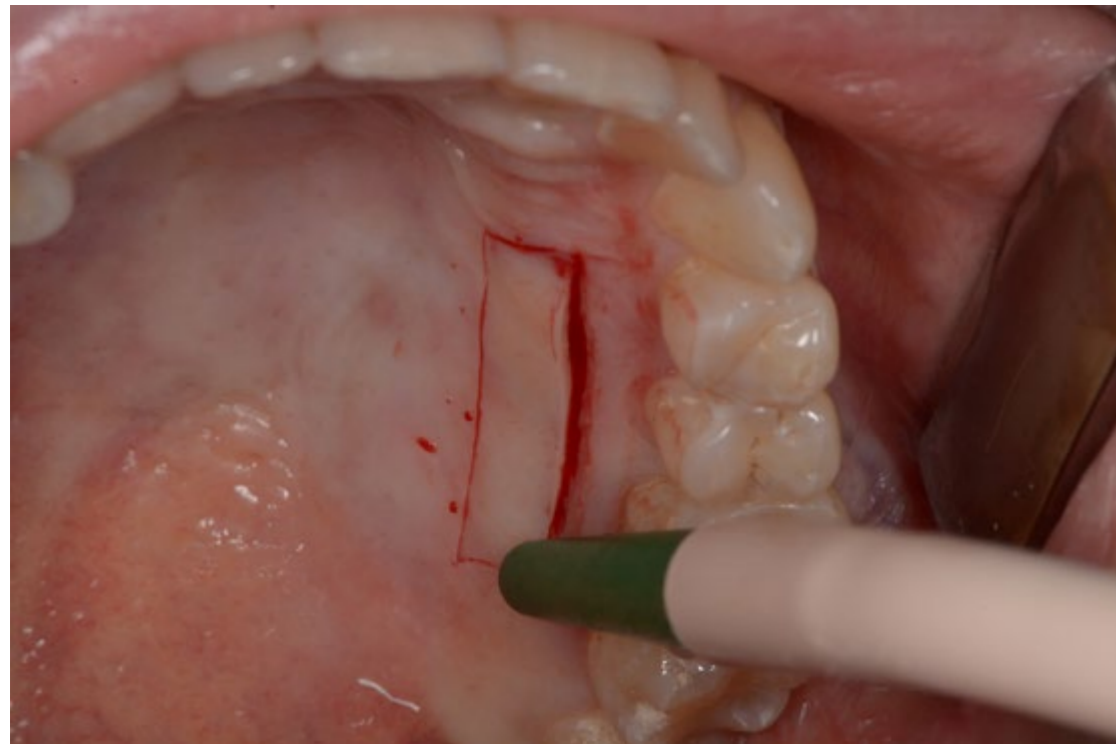
Healing of the donor site, no post-operative pain reported.

10 days post-operative

Healing of the donor site, no post-operative pain reported.

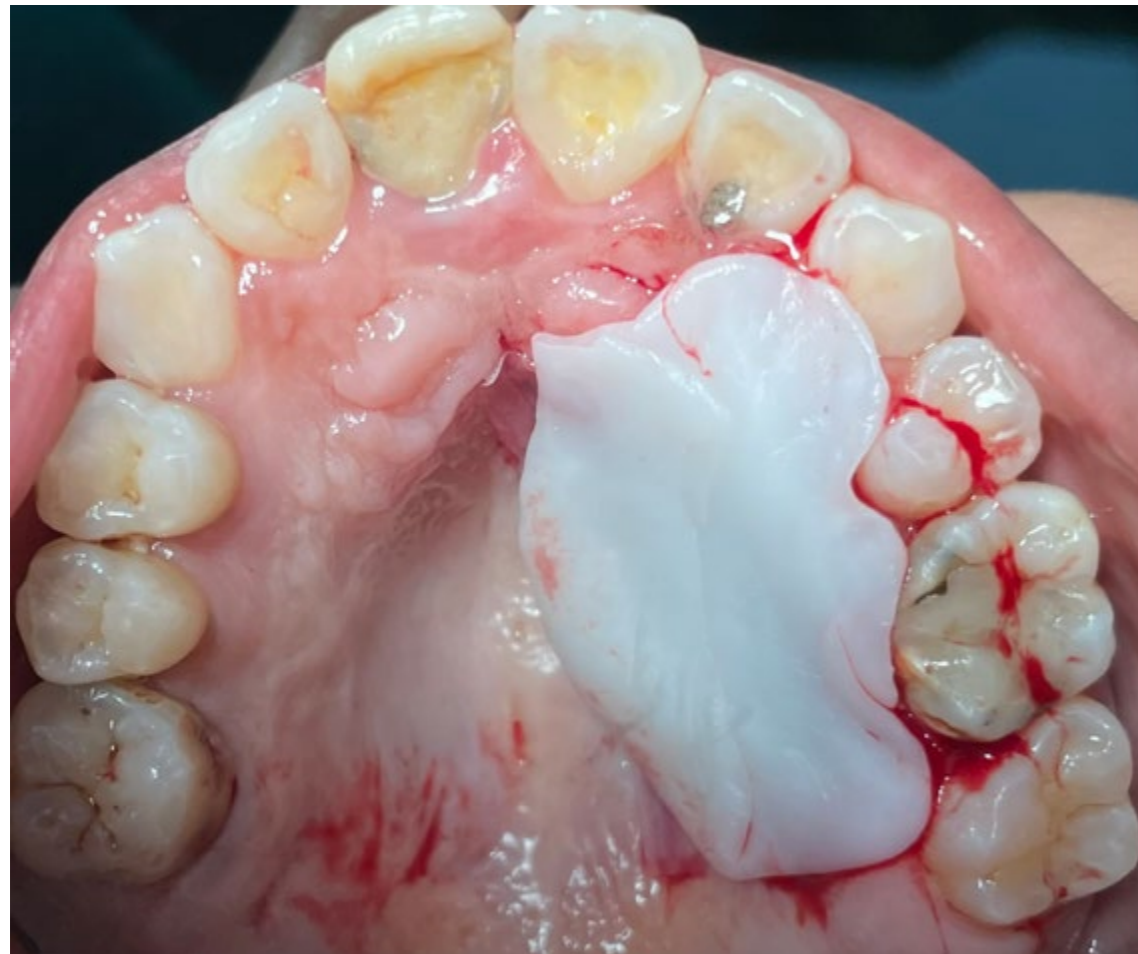Application

Palatal stent on donor site after soft tissue grafting

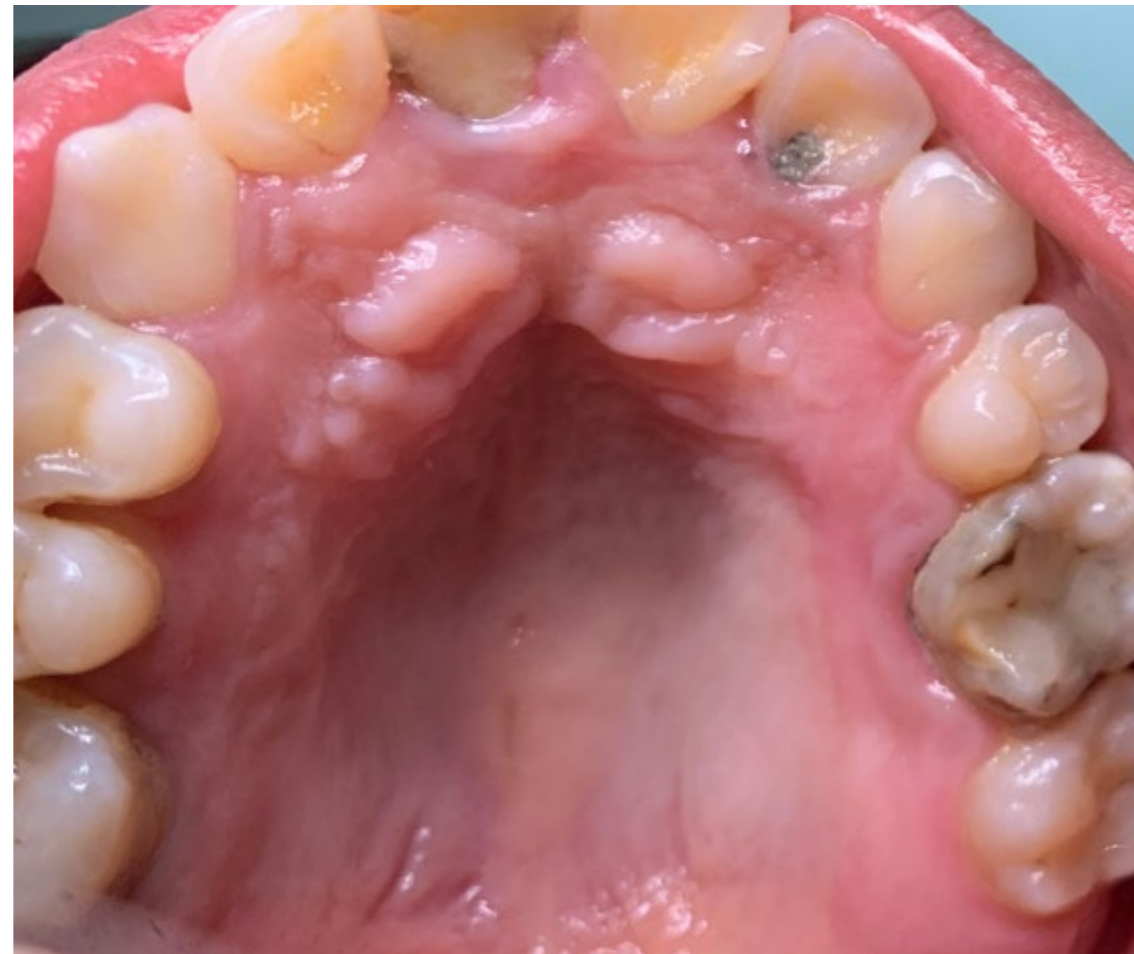

Application

Palatal stent on donor site after soft tissue grafting



Day of surgery



1 month post-operative

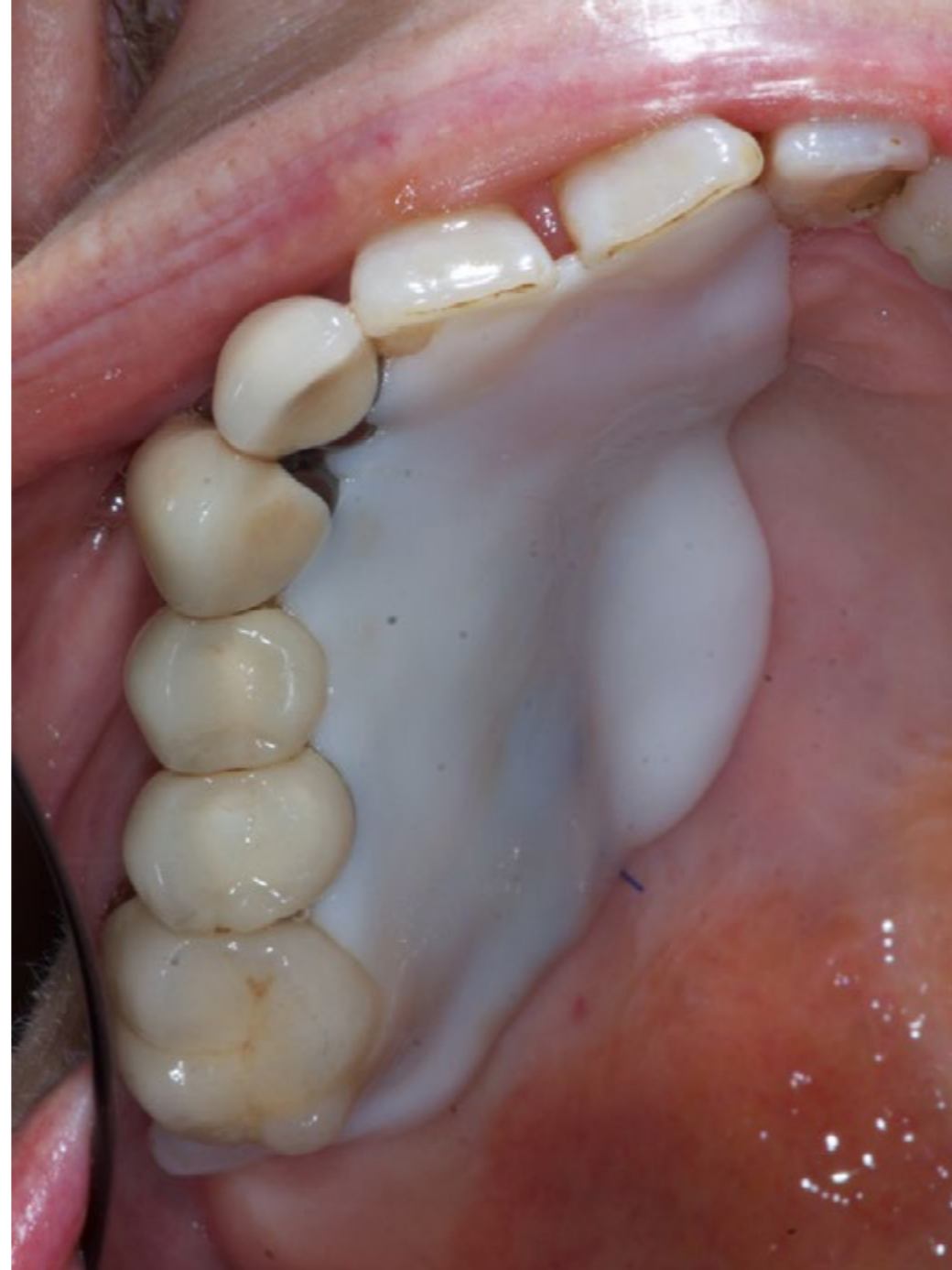“What surprised me was the retention of the polymer on the palate. It actually stayed on until the 3rd day when my patient decided to remove it herself due to the pressure on the wound.

The good thing about this polymer stent is that it really helps with haemostasis and it can be made easily chairside. The only problem, according to my patient, is it shouldn't be worn for more than 2 days as it gets uncomfortable with post-op oedema.

Is it something I would use in the clinic? Definitely for mucogingival procedures as it saves the trouble of making an acrylic plate.”

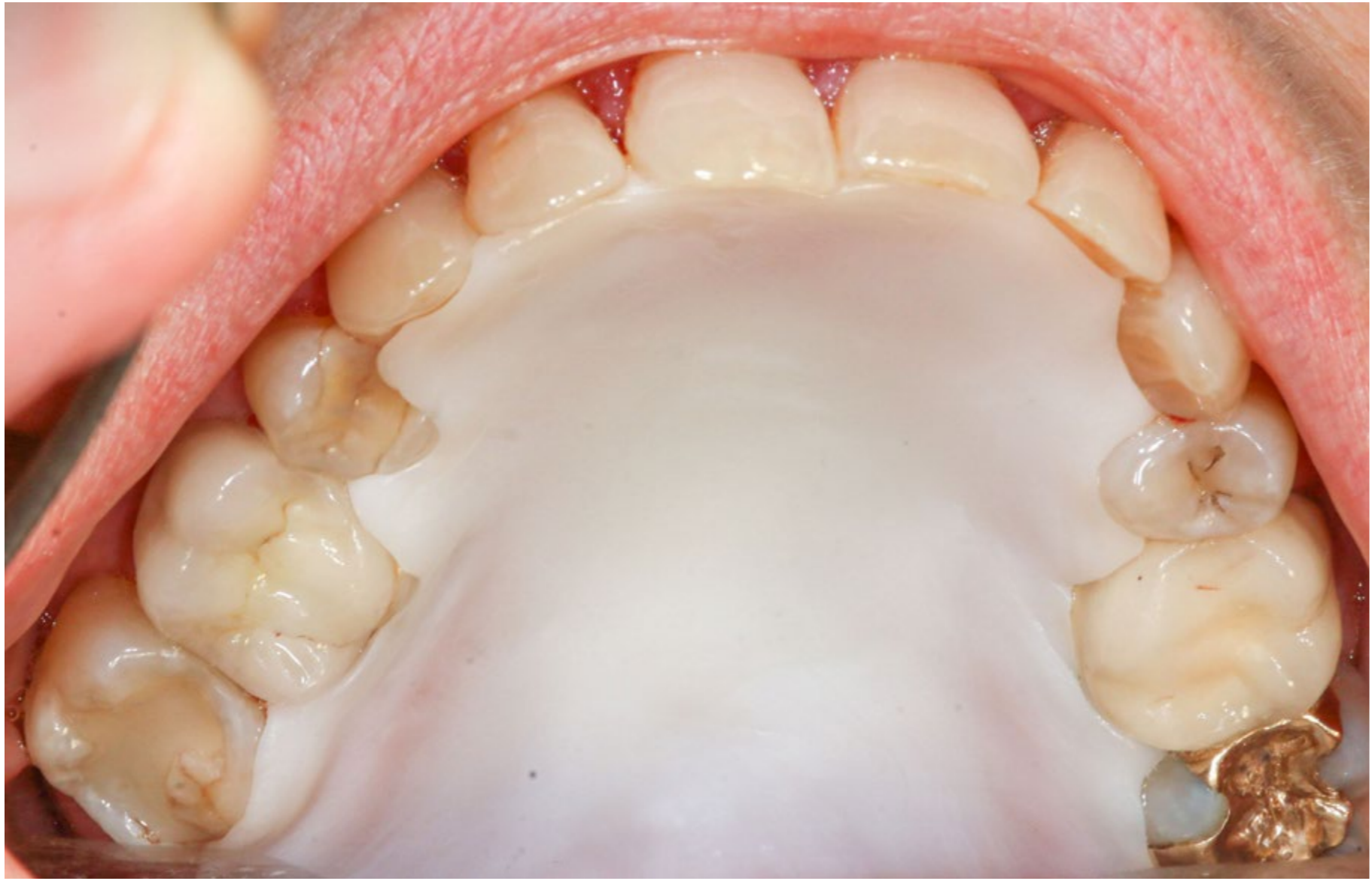Application

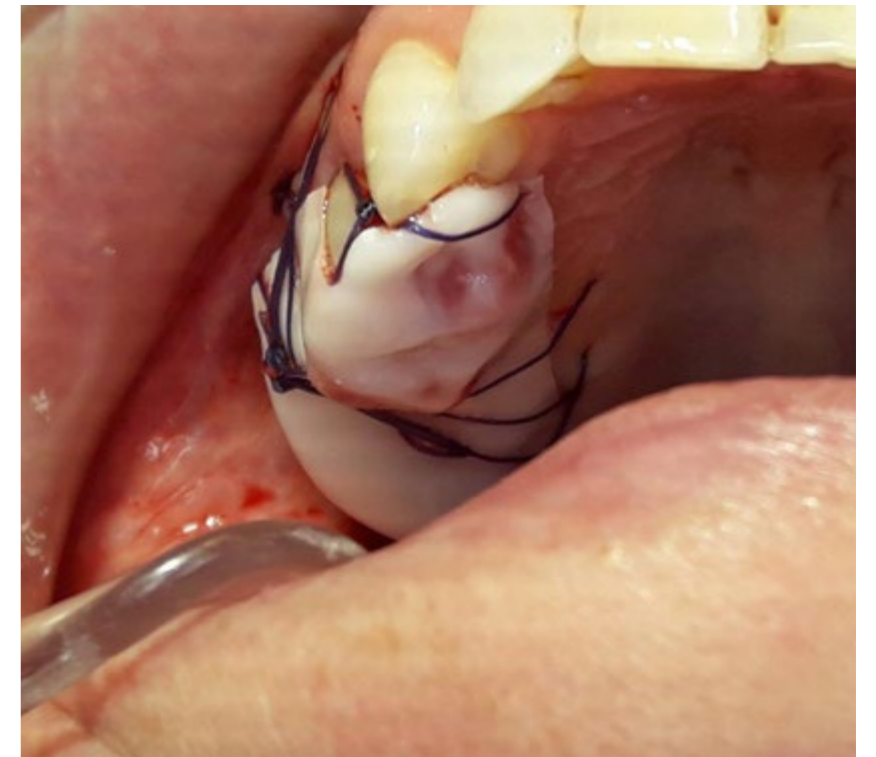
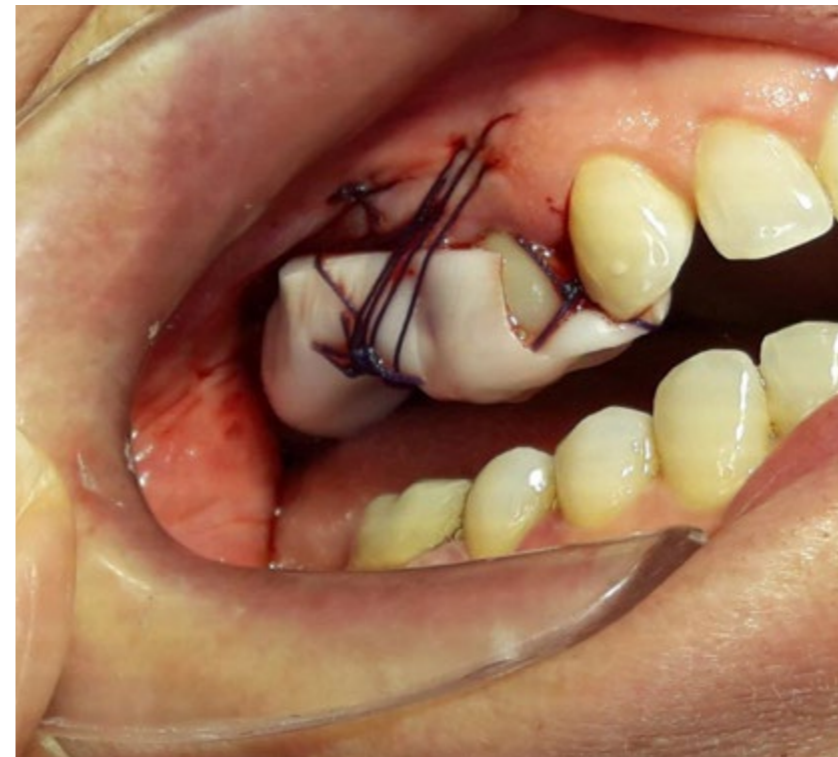
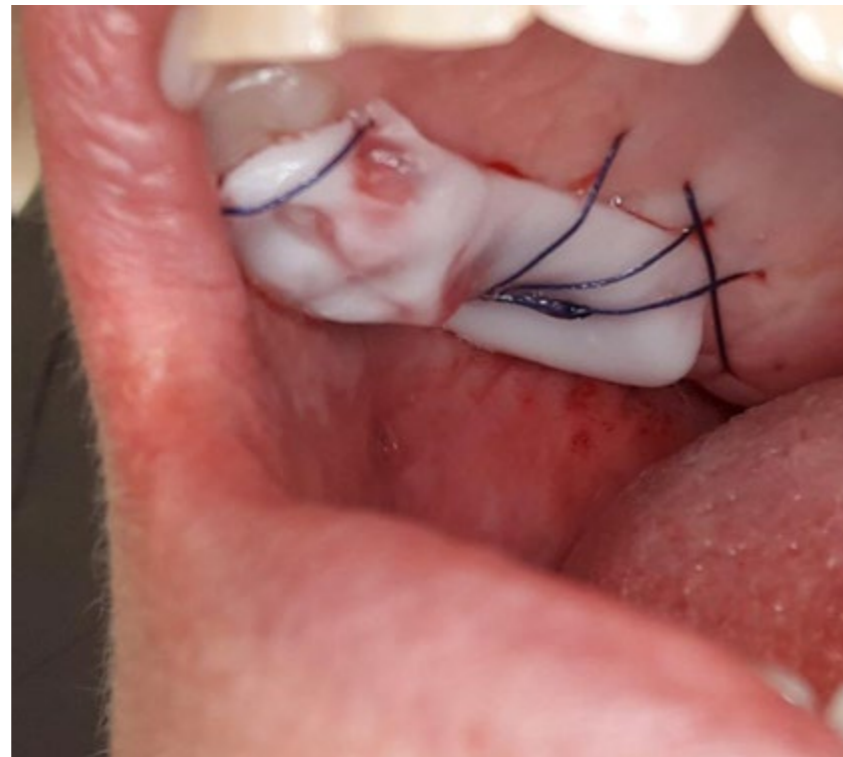
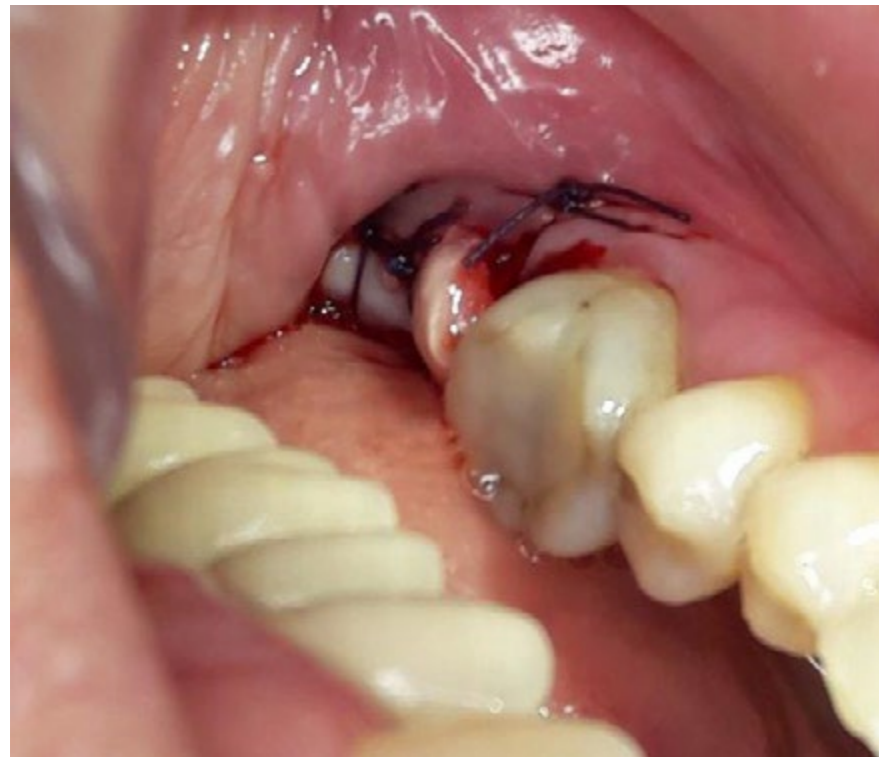Palatal stent on donor site after soft tissue grafting



Application

Palatal stent on donor site after soft tissue grafting







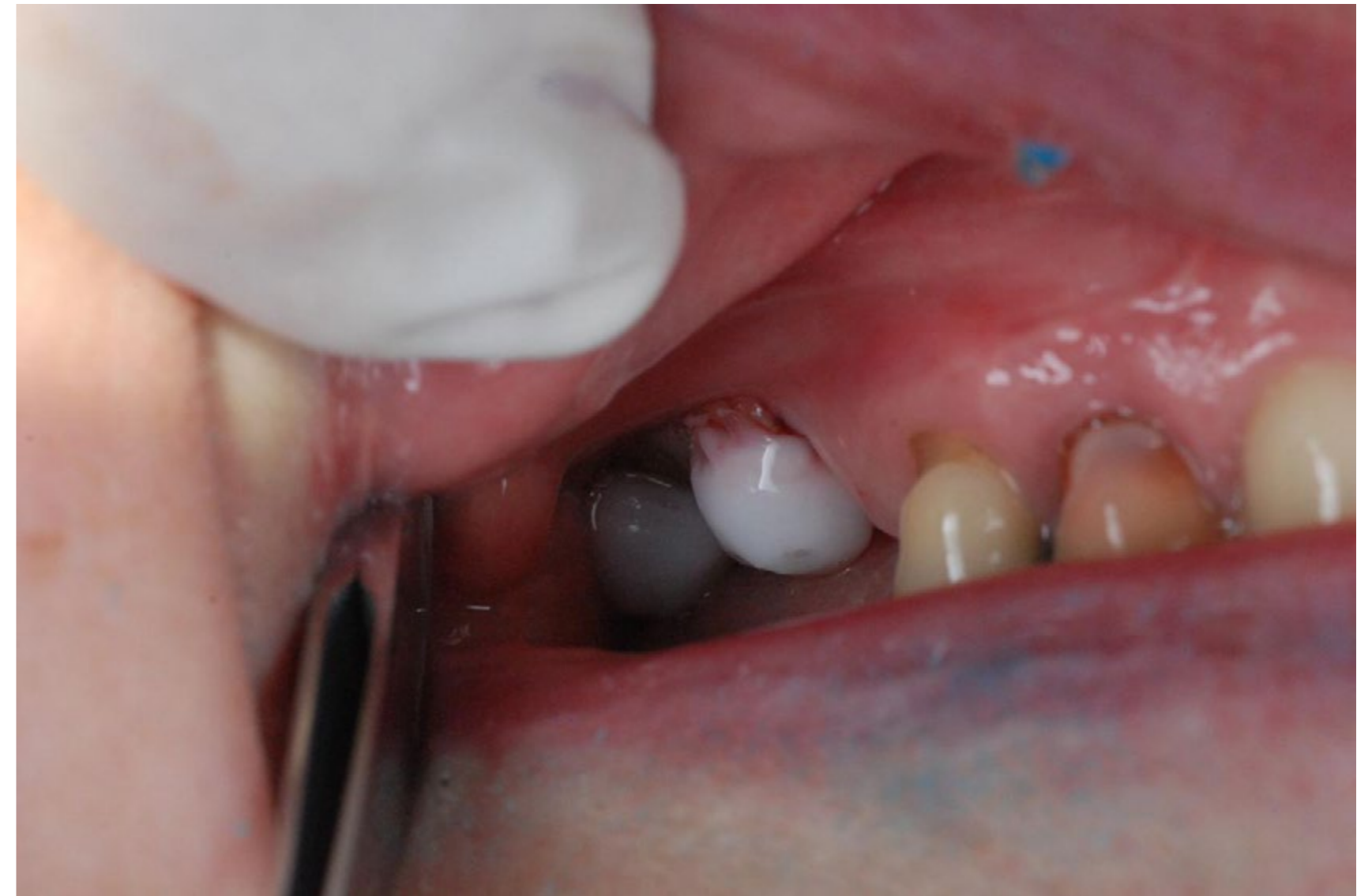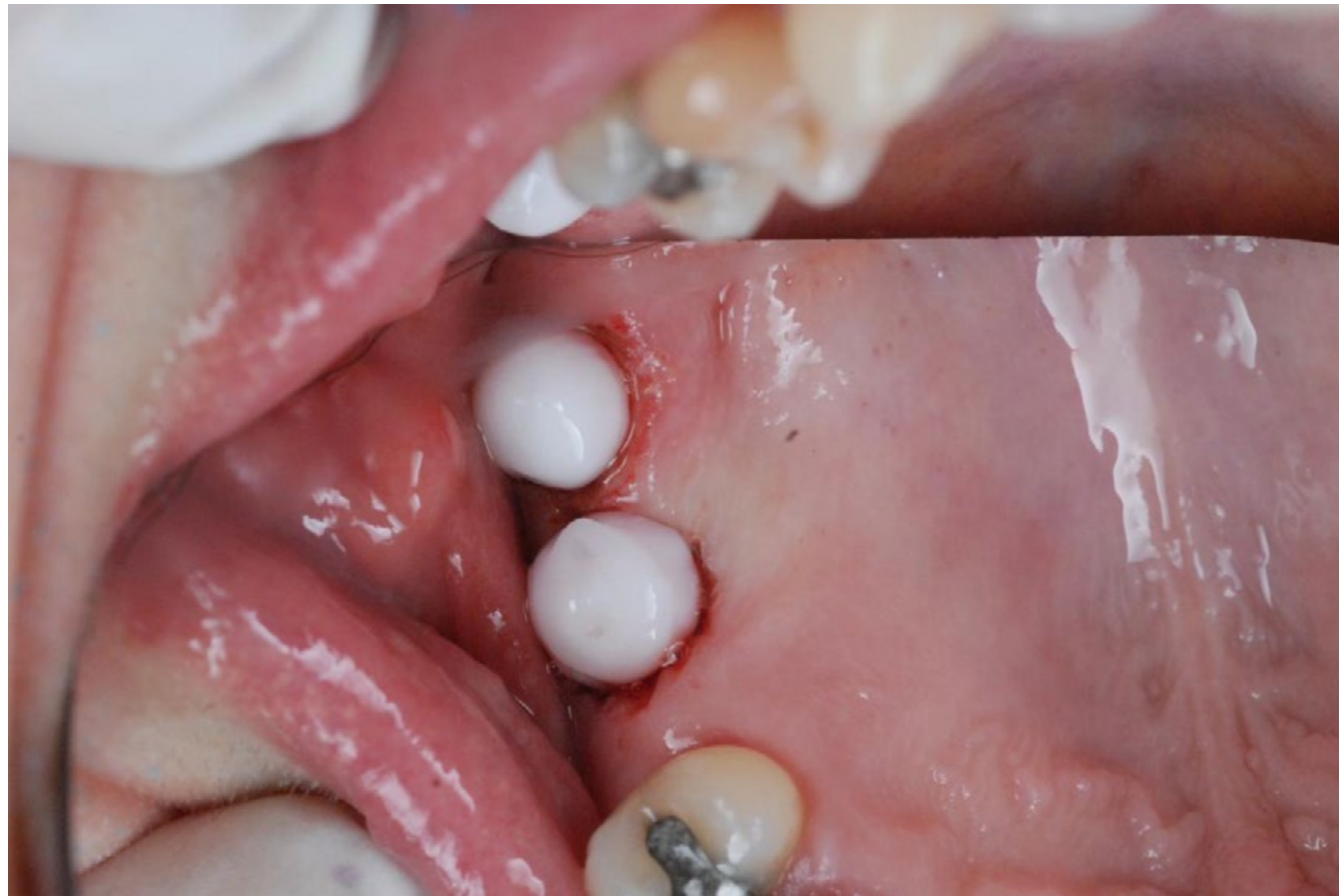APPLICATION

Custom Healing Abutments



Application

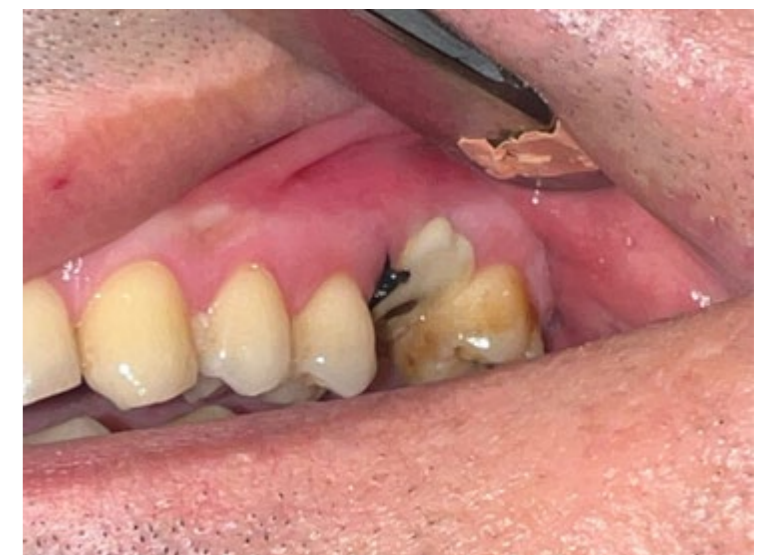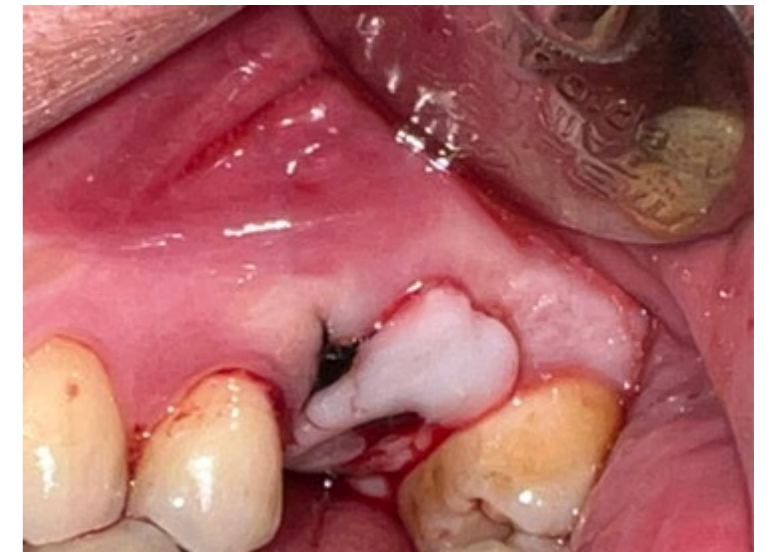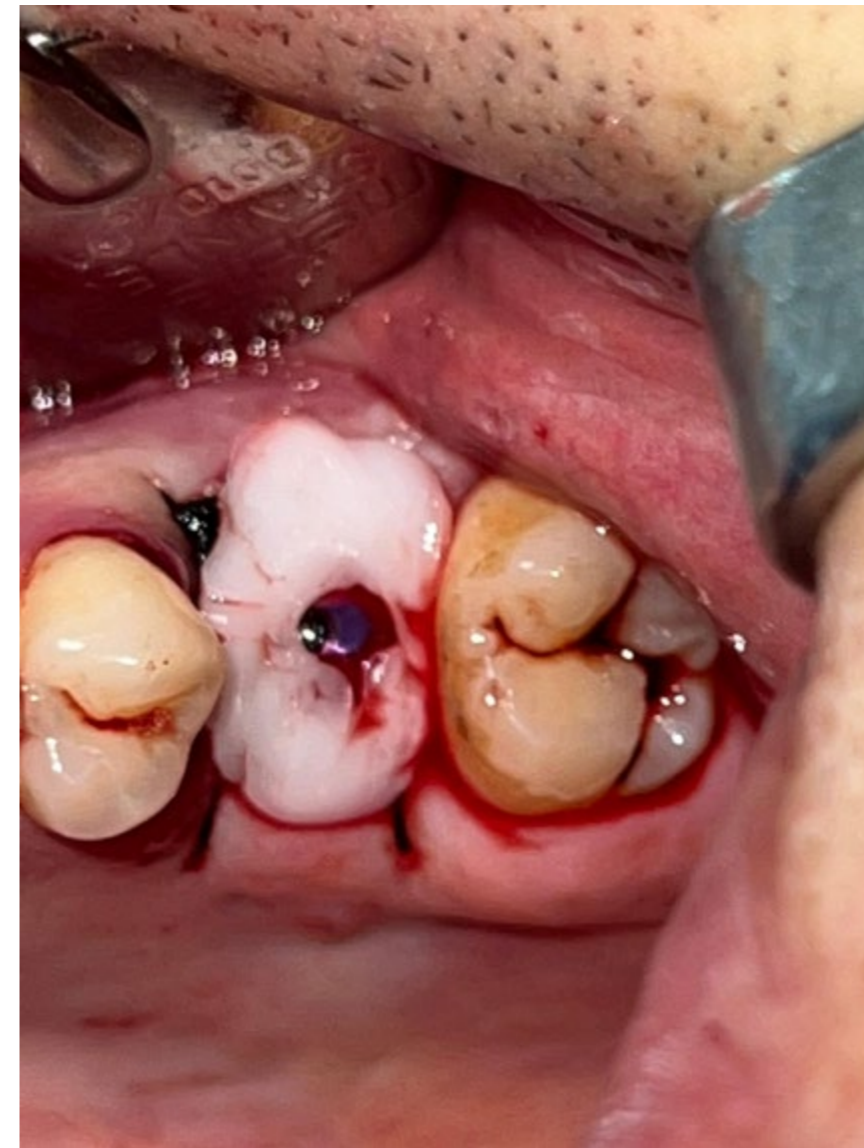
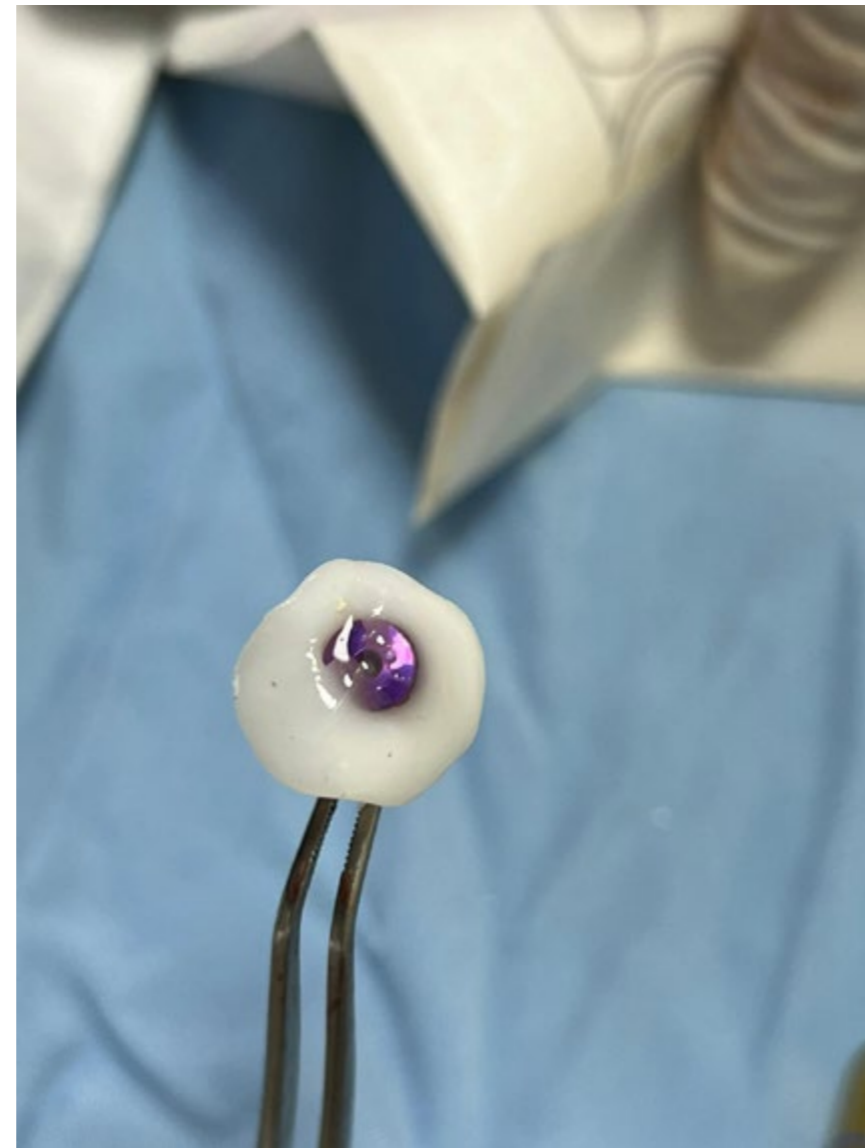
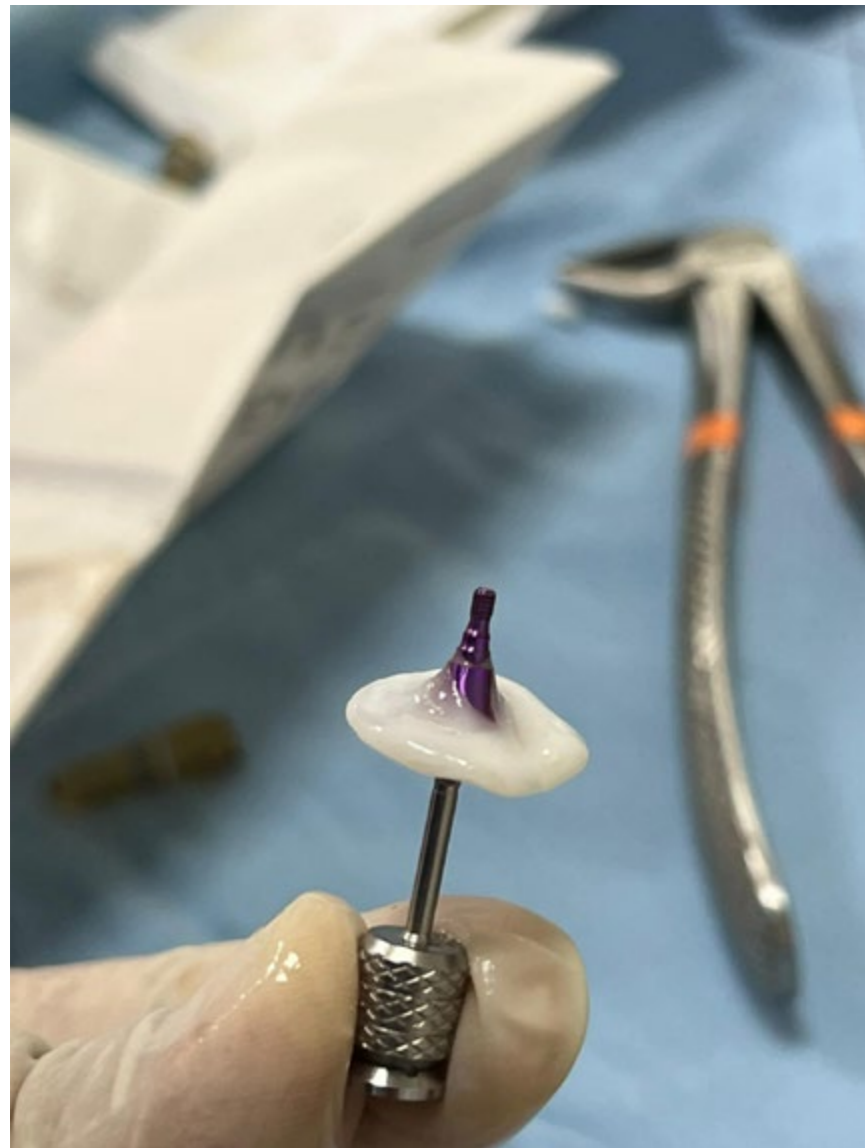Custom healing abutment





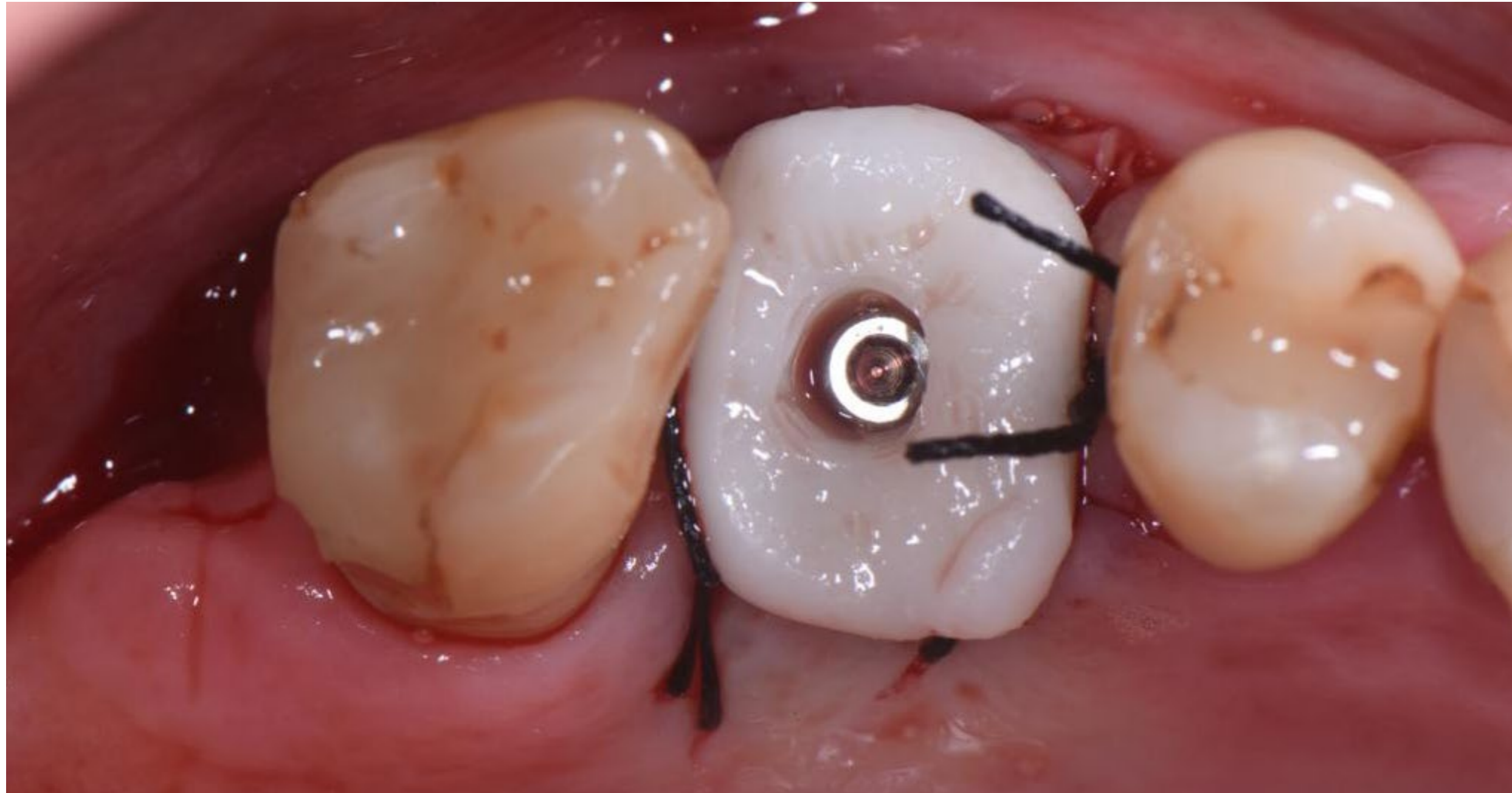
Application

Custom healing abutment



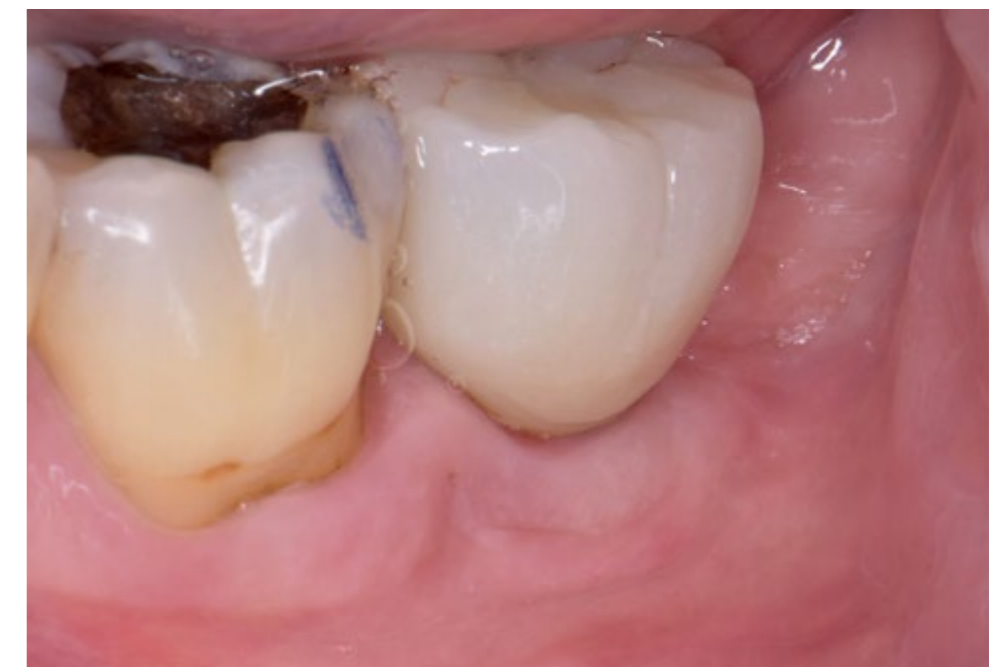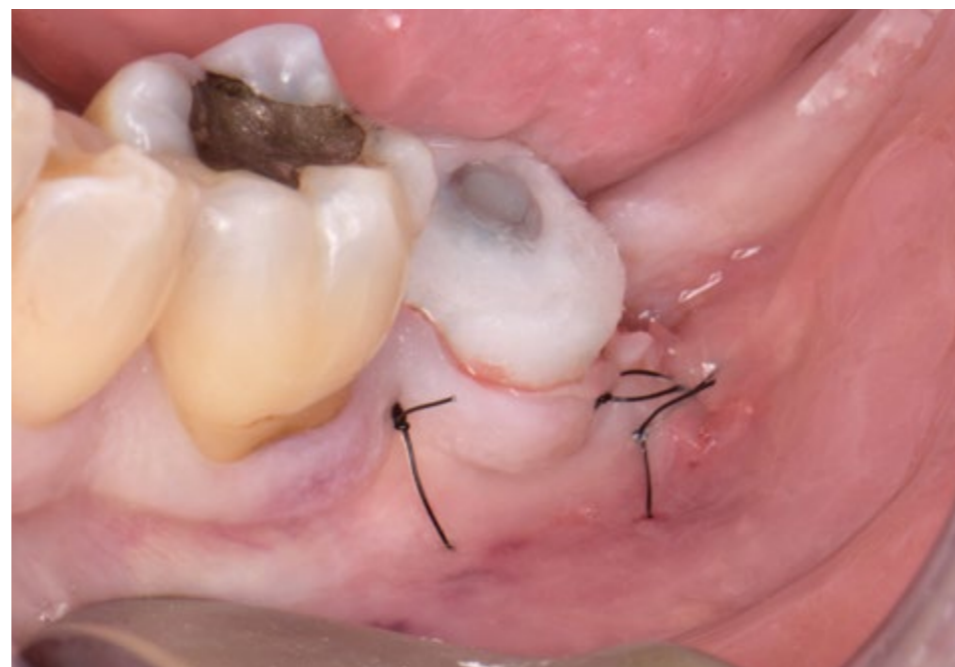
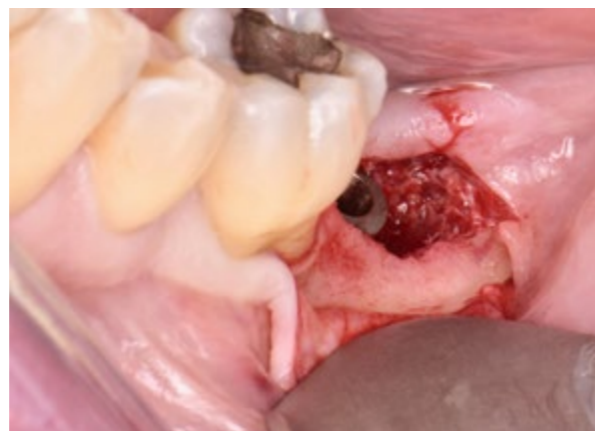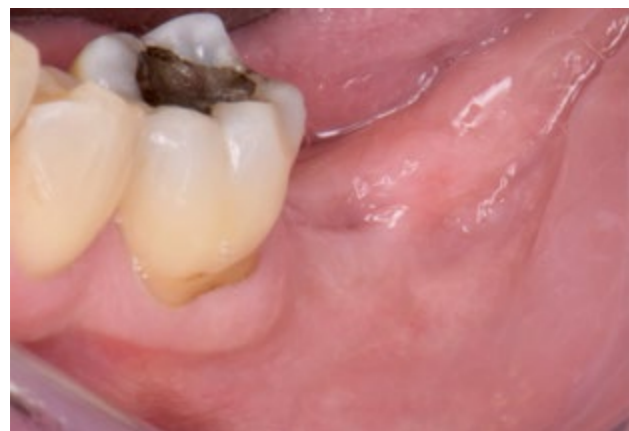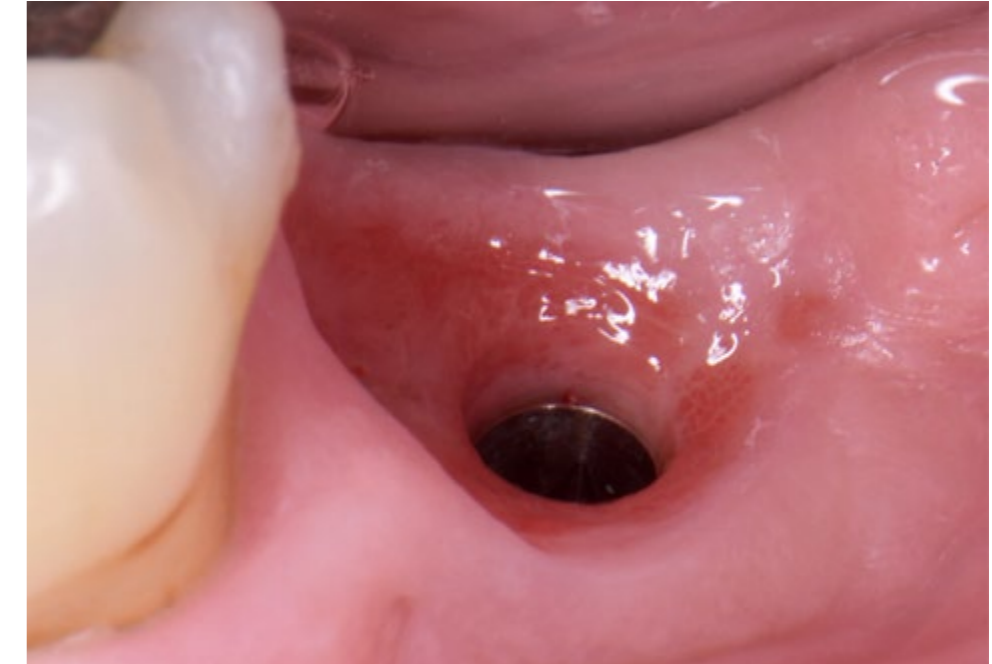
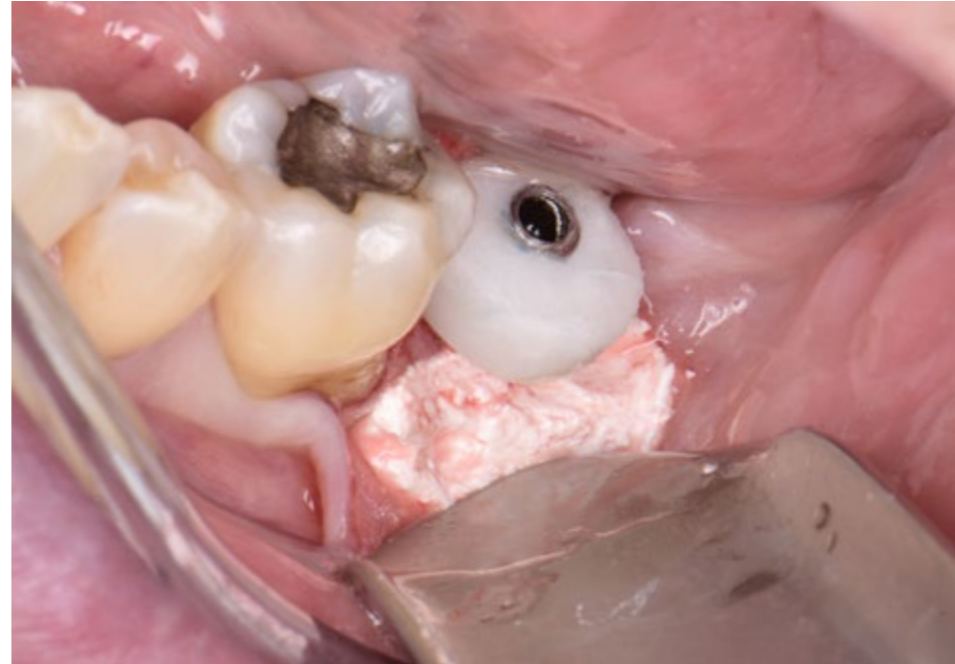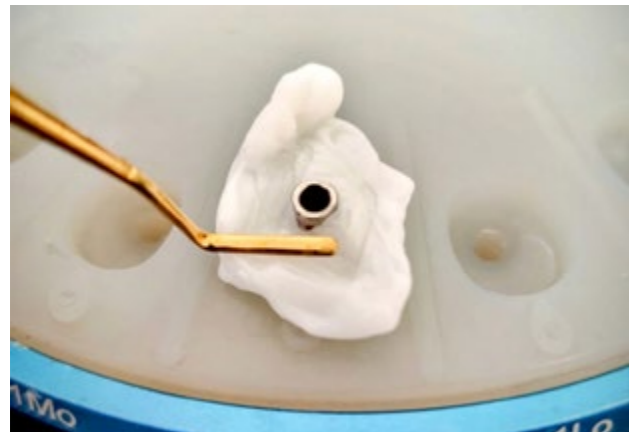Application

Socket Sealing Abutment



Application

Custom healing abutment with Cervico mold



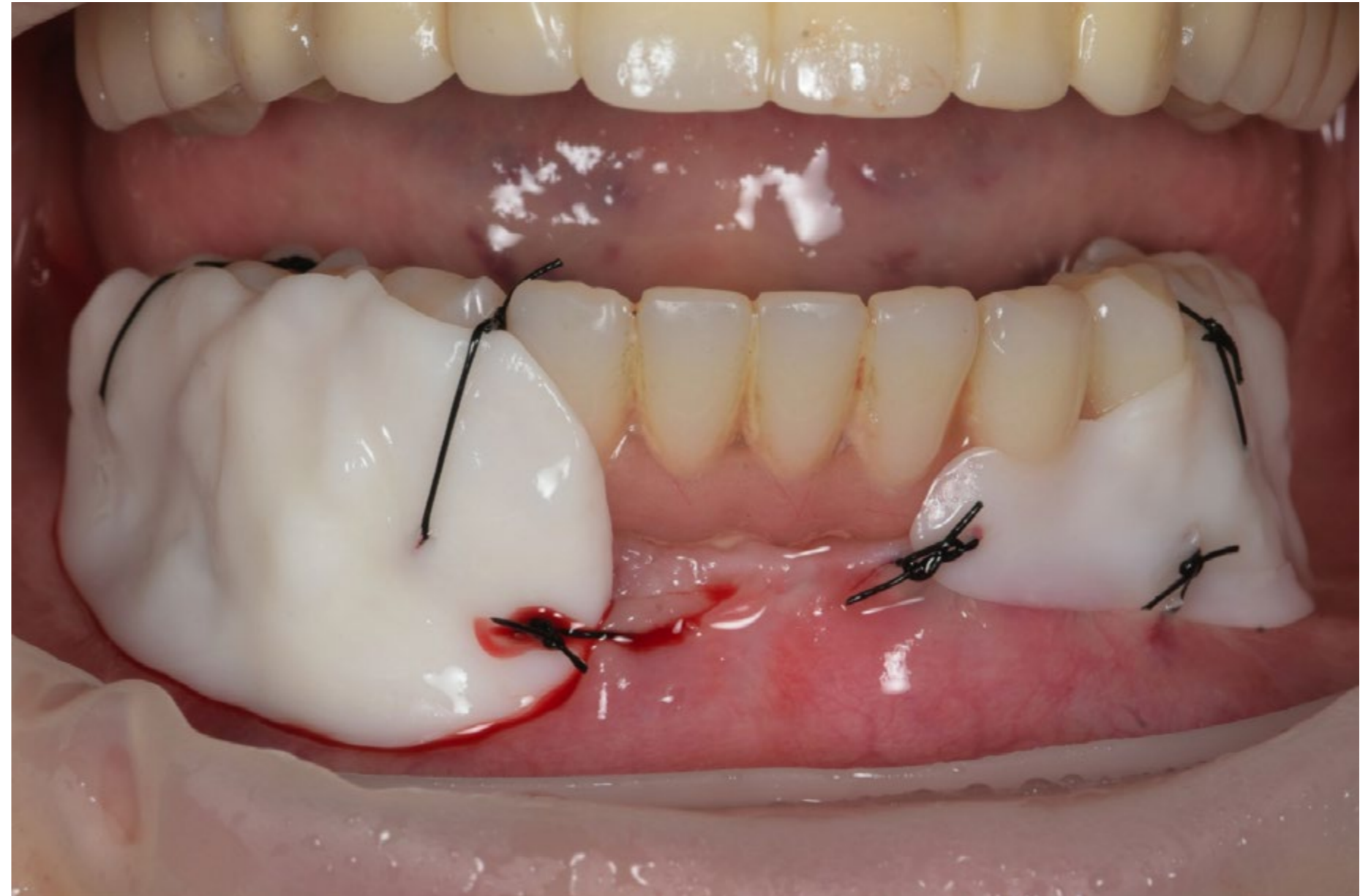
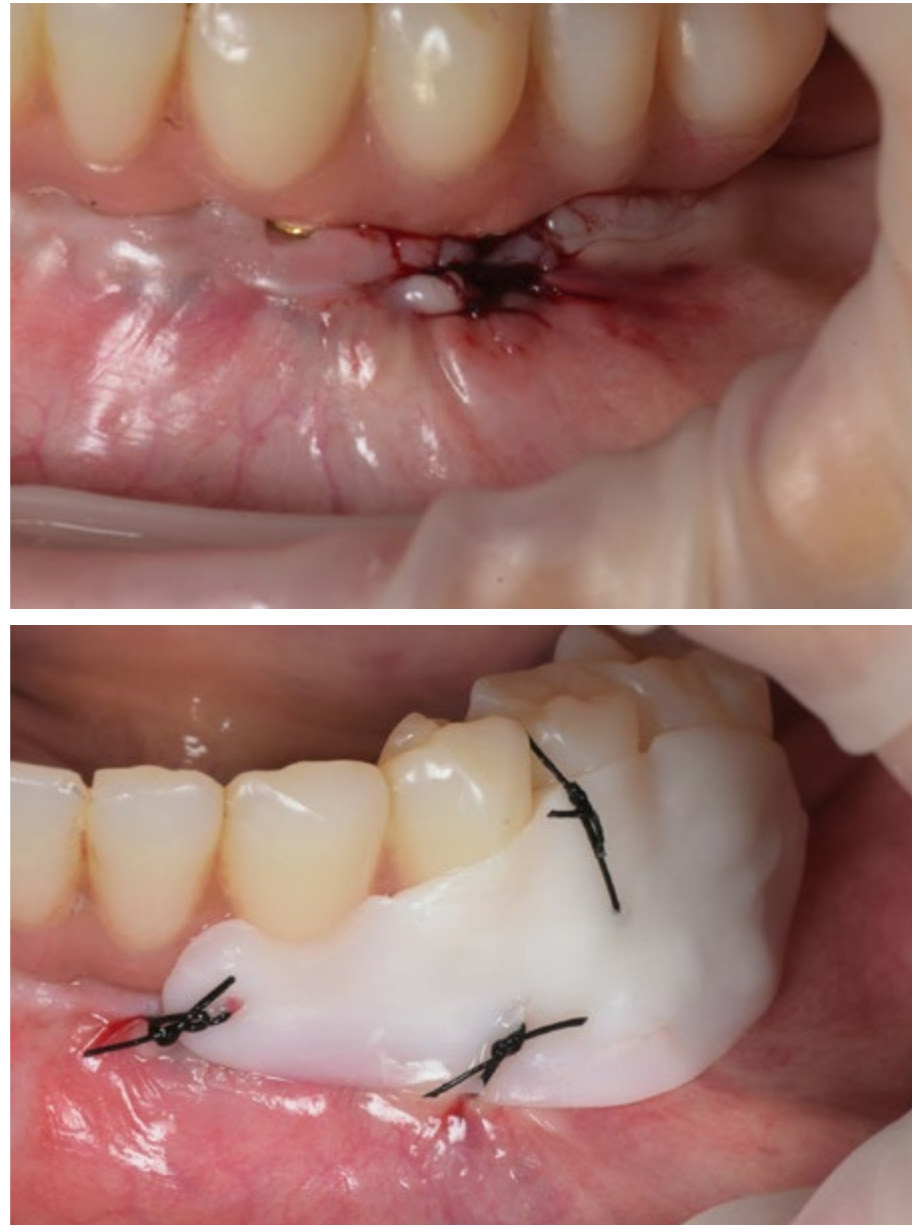
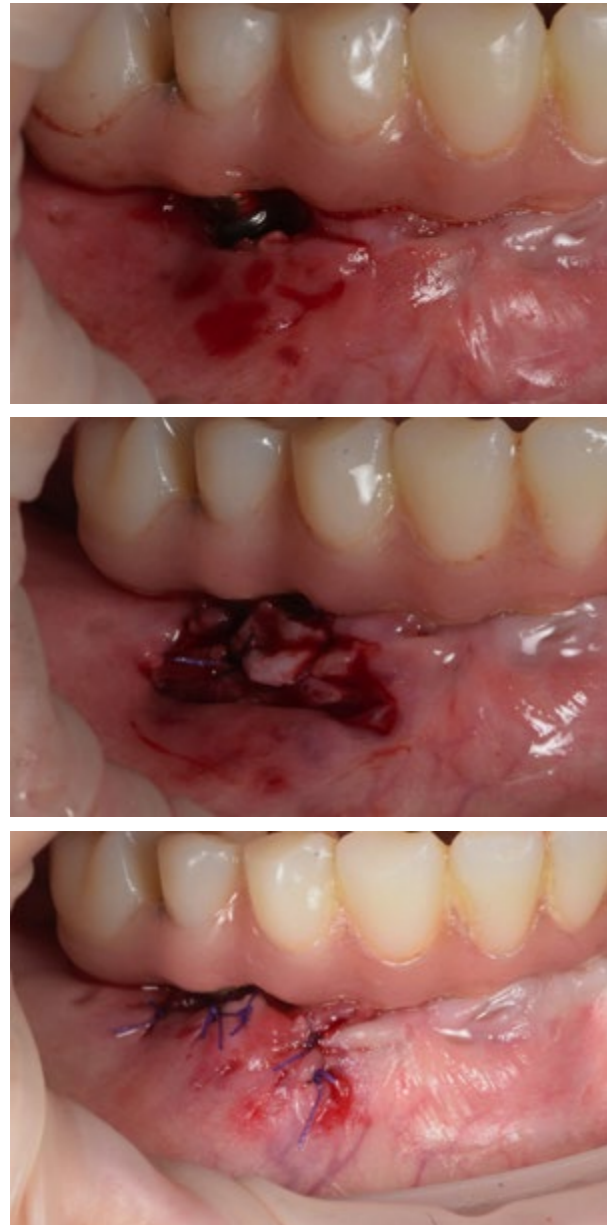
APPLICATION

**Antibacterial wound barrier
on surgical sites**

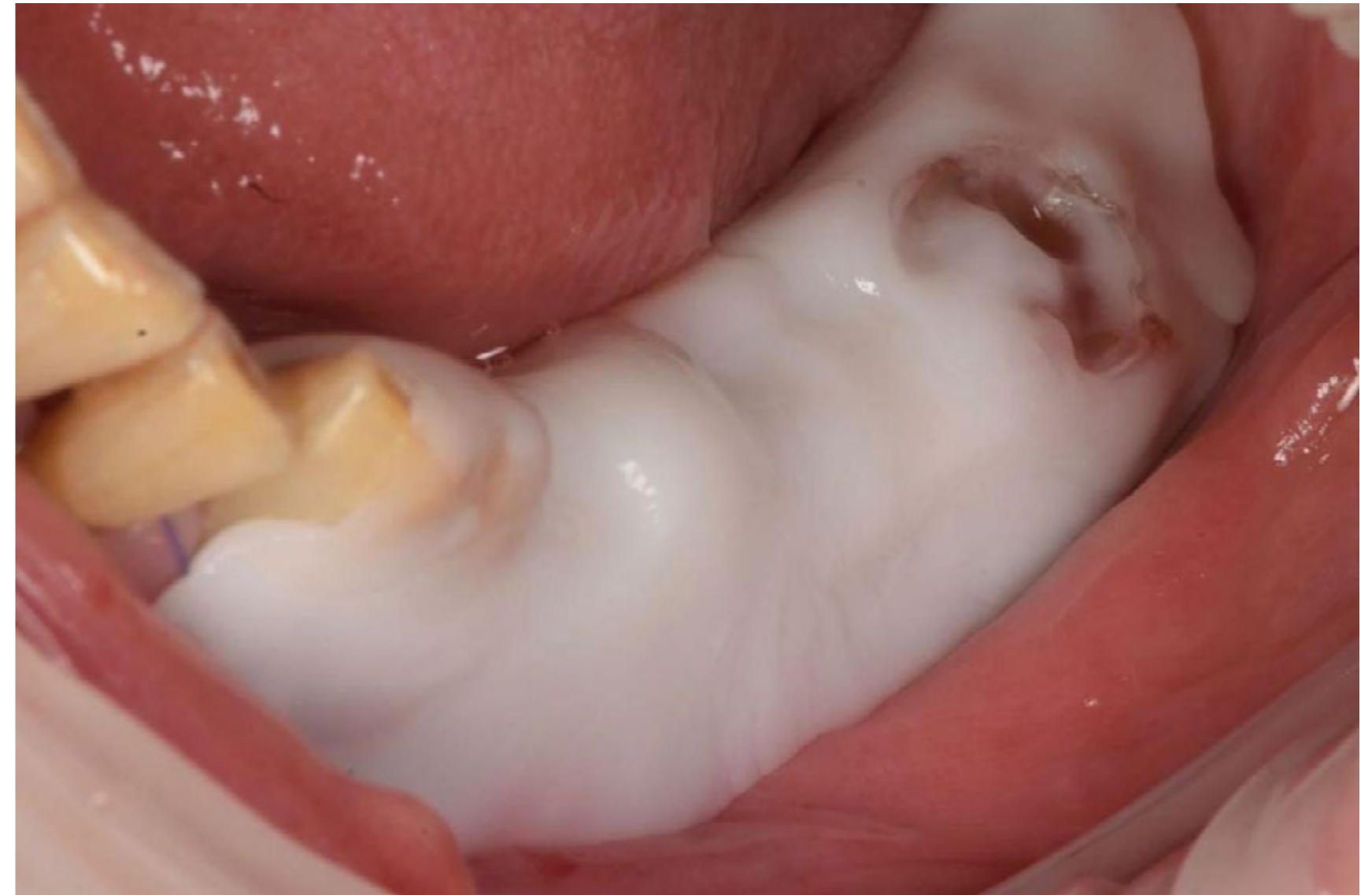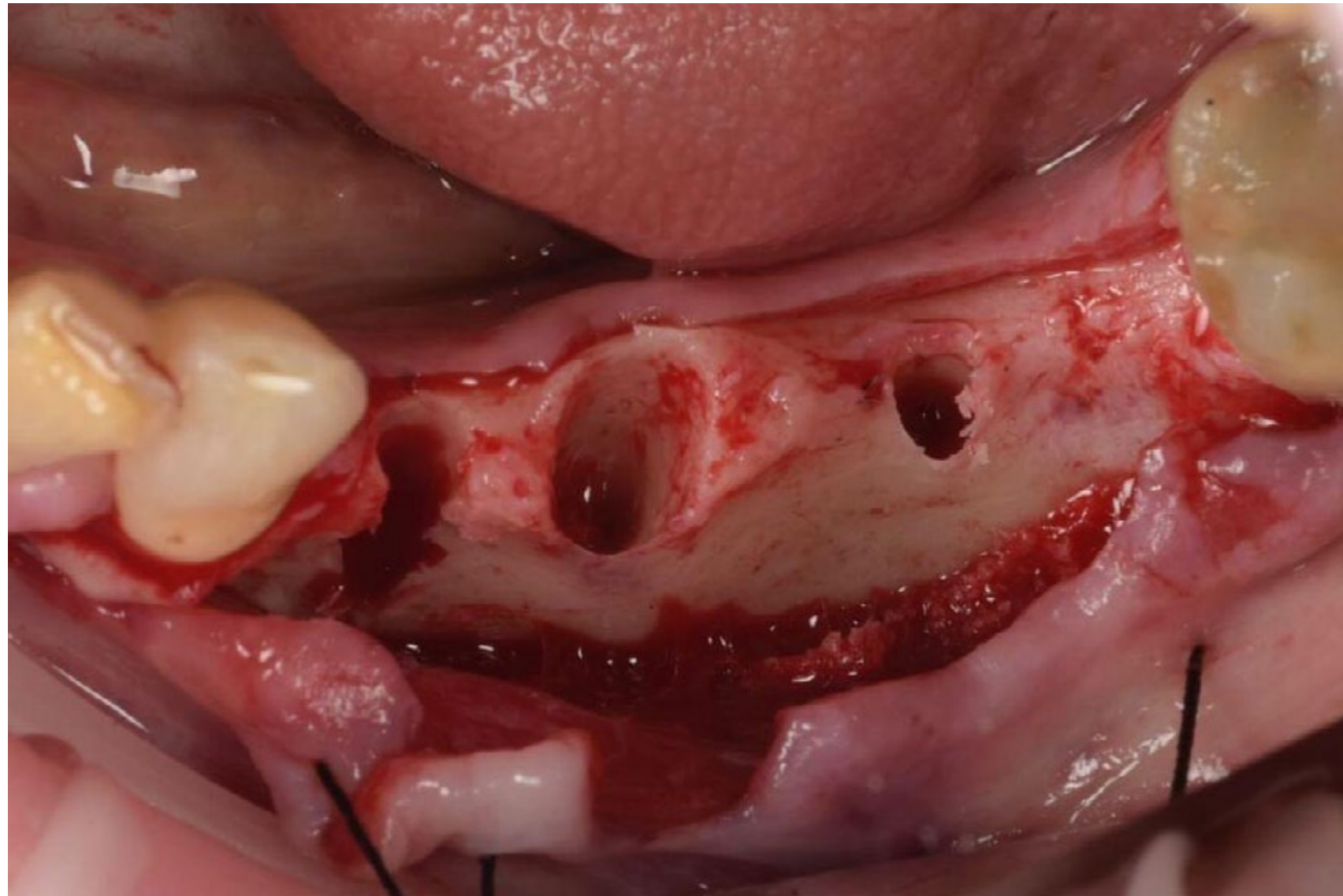
Application

Mechanical antibacterial coverage of surgical sites



Application

Mechanical antibacterial coverage of surgical sites





APPLICATION

Denture Relining





Application

Antibacterial denture relining

